




BOSTON  
MEDICAL LIBRARY  
8 THE FENWAY







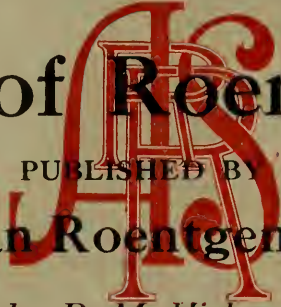Gal 3/8



# The American Quarterly of Roentgenology

PUBLISHED BY

## The American Roentgen Ray Society



*Edited by P. M. Hickey, M. D.  
Associate Editor, F. G. Zapffe, M. D.*

	PAGE
Roentgenographic Diagnosis on Ureteral Kinks Causing Intermittent Hydronephrosis - - - - - <i>G. H. Stover, M. D., Denver, Colo.</i>	1
The Control of Fracture Work by the Roentgen Ray - <i>Roland Hammond, Providence, R. I.</i>	5
X-Ray Dosage With a Unipolar X-Ray Tube - - <i>Sinclair Tousey, A. M., M. D., New York</i>	18
Syphilitic Manifestations in the Lungs, Resembling Pulmonary Tuberculosis, with Report of Cases - - - <i>R. P. Daniells, M. D., and H. W. Dachtler, Toledo, O.</i>	20
Carcinomatosis of the Bone, Secondary to a Growth in Some Epithelial Organ - - - - - <i>Russell H. Boggs, M. D., Pittsburg, Pa.</i>	30
The Importance of the Proper Understanding of the Relation of the Abdominal Viscera in the Treatment of Auto-intoxication and Auto Infection - - - - <i>Dr. Joel E. Goldthwait, Boston, Mass.</i>	37
Preliminary Announcement of Annual Meeting - -	54

**The Next Annual Meeting will be at Niagara Falls, September 11, 12, 13 and 14, 1912**

COPYRIGHT APPLIED FOR BY PRESTON M. HICKEY. ALL RIGHTS RESERVED

# Officers of American Roentgen Ray Society

---

PRESIDENT: F. H. BAETJER, M. D., Baltimore, Md.

## VICE-PRESIDENTS:

G. M. STEELE, M. D., Oshkosh, Wis.

H. W. VAN ALLEN, M. D., Springfield, Mass.

J. H. EDMONSON, M. D., Birmingham, Ala.

W. H. EAGAR, M. D., Halifax, N. S.

H. E. POTTER, M. D., Chicago, Ill.

SECRETARY: HENRY K. PANCOAST, M. D., Philadelphia, Pa.

TREASURER: CHAS. F. BOWEN, M. D., Columbus, Ohio

## Executive Committee

P. M. HICKEY, M. D., Detroit, Mich.

ARTHUR HOLDING, M. D., Albany, N. Y.

A. L. GRAY, M. D., Richmond, Va.

## Committee on Publication

P. M. HICKEY, M. D., Detroit, Mich.

SIDNEY LANGE, M. D., Cincinnati, O.

D. R. BOWEN, M. D., Philadelphia, Pa.

## Librarian

H. W. DACHTLER, Toledo, Ohio

# The American Quarterly of Roentgenology

*Editor, P. M. Hickey, M. D., Detroit*  
*Associate Editor, F. C. Zapffe, M. D., Chicago*

---

---

Vol. IV

AUGUST, 1912

No. 1

---

---

## ROENTGENOGRAPHIC DIAGNOSIS ON URETERAL KINKS CAUSING INTERMITTENT HYDRONEPHROSIS.

BY G. H. STOVER, M. D., DENVER, COLORADO.

While the Roentgenographic examination of the renal pelvis and ureter following the injection of opaque fluids such as collargol, etc., is not new, it is believed that a suggestion of Dr. O. S. Fowler, of Denver, Colo., regarding an addition to the technique of these examinations, which technique has since been made use of by the writer and Dr. Fowler in the examination of several cases, has practically developed a new method of examination and diagnosis in a very troublesome class of kidney cases.

Hydronephrosis has heretofore been recognized only in rather an advanced age, when the dilatation of the renal pelvis is considerable; the Mayos, for instance, consider that the renal pelvis must be able to contain 50CC. of fluid before they make a diagnosis of operable hydronephrosis; at this time the function of the kidney is markedly impaired and its structure may have received serious damage.

Many of the classically hydronephrotic cases are found at operation to accompany a movable kidney, in which there is a dilatation of the renal pelvis and in which there is also a dilatation of the ureter above the location of an aberrant artery or vein, or a band of adhesion; these patients were relieved after a fixation of the kidney and removal of the obstructing structure.

We have found, and have demonstrated by catheter tests,

Roentgenograms and surgical operation that there is easily recognizable a much earlier stage of this condition, to be discovered before dilatation of the renal pelvis has taken place.

A certain number of patients complain of pain in one or both kidneys; a pain somewhat like that of the classical hydronephrosis, but not relieved by the sudden passage of a quantity of urine and a disappearance of the tumor, and without the microscopic urinary findings of fully developed hydronephrosis; a pain suggestive, but not typical of renal calculus colic, and in which Roentgenographic examination for stone is negative. The symptom complex in this class of cases has usually been rather vague in its diagnostic indications, and there have undoubtedly been many instances in which a faulty diagnosis has led to operation for conditions which were not present, the trouble being laid to an appendix, a tube, an ovary, or a gall bladder.

In the class of cases under consideration it was found by Dr. Fowler that the injection of a comparatively small amount of solution (averaging only 14 CC.) into the pelvis of the kidney, produced a pain exactly similar to the pain from which the patient suffered, an injection of the unaffected kidney produced a pain which the patient had never felt there before, but identical with that which had been felt on the other side.

We had already examined hydronephrotic cases after collargol injections, and in the course of several conferences on the subject of the Roentgenographic examination of the various viscera in which mention was made of the fact that I, as a routine, make Roentgenographic examinations of the stomach and intestines with the patient in the erect posture, Dr. Fowler suggested that in examining these cases of "intermittent hydronephrosis" the collargol be injected first with the patient reclining and a plate made, then the patient placed in the erect posture and a second plate made; while the patient is in the erect posture he is instructed to make various movements of the trunk, such as would be calculated to dislodge a really movable kidney, and at the same time the ureteral catheter is being withdrawn while a further amount of solution is being injected through it, thus showing Roentgenographically the changed position of the kidney and demonstrating the appearance of the ureteral kink; this procedure, as far as we can ascertain, has not been made use of prior to our work.

Mrs. C. R. G. Plate I, Recumbent; plate 2, erect. Operation revealed kink in left ureter to be due to a looping of the



8956 L

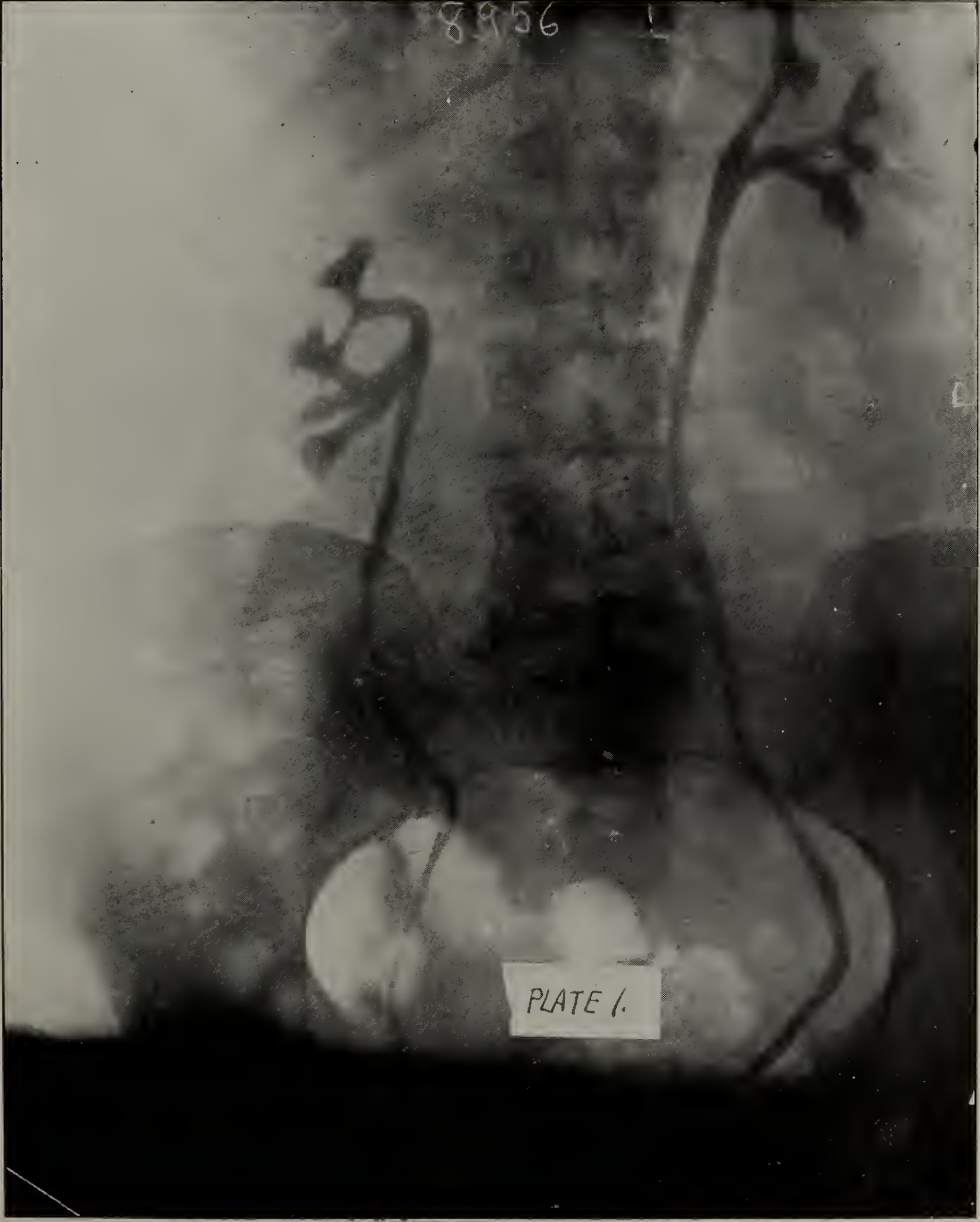
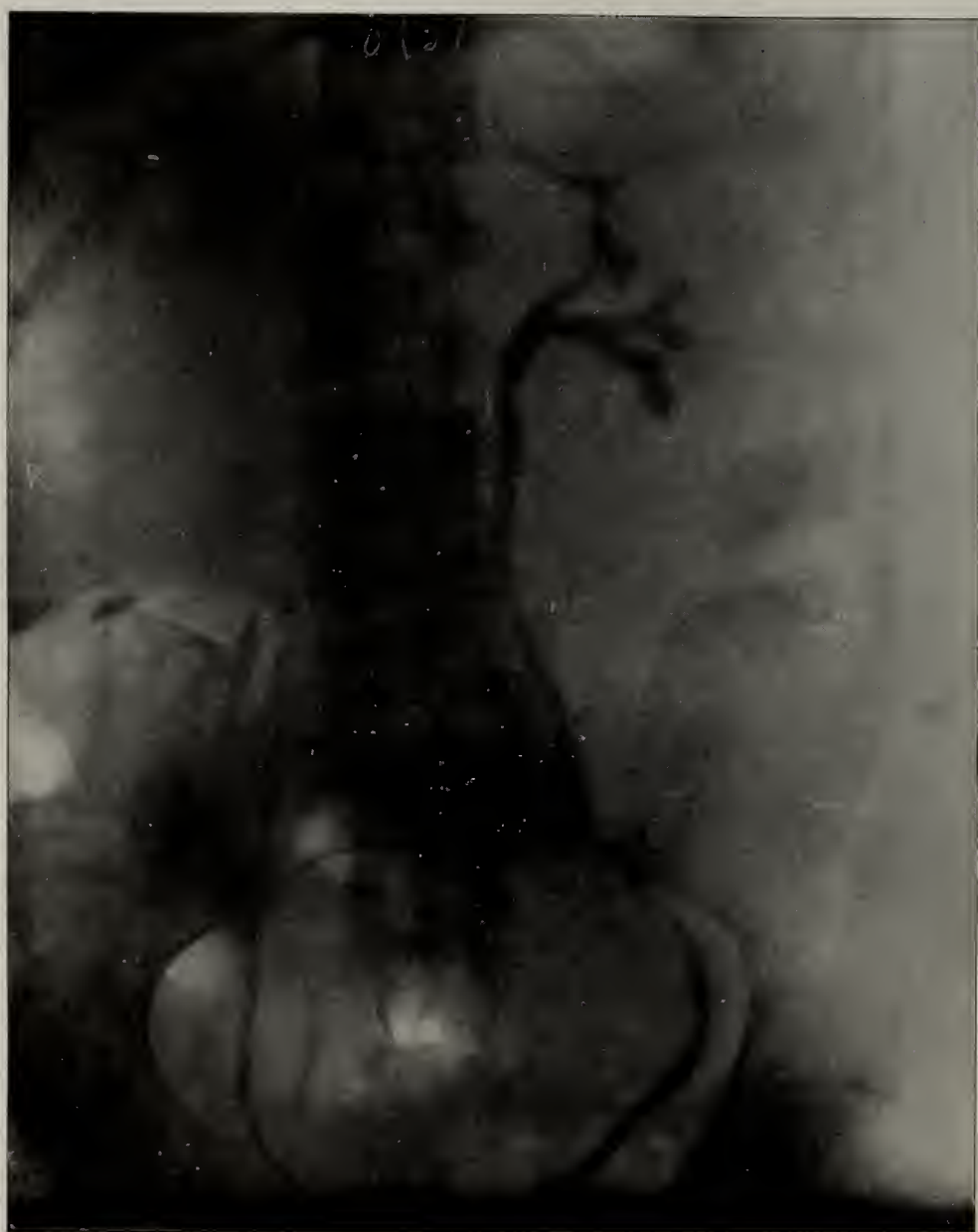

PLATE 1.



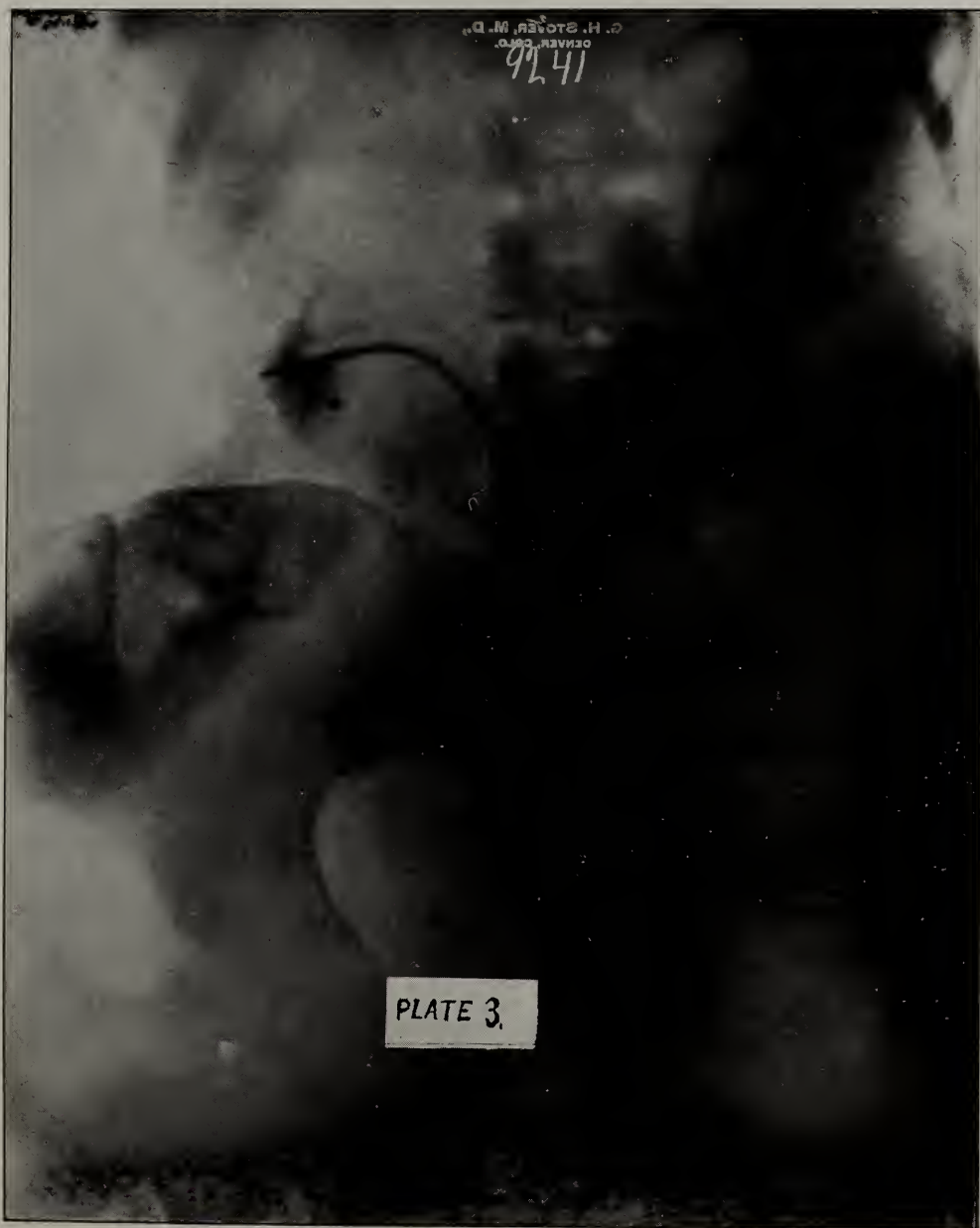
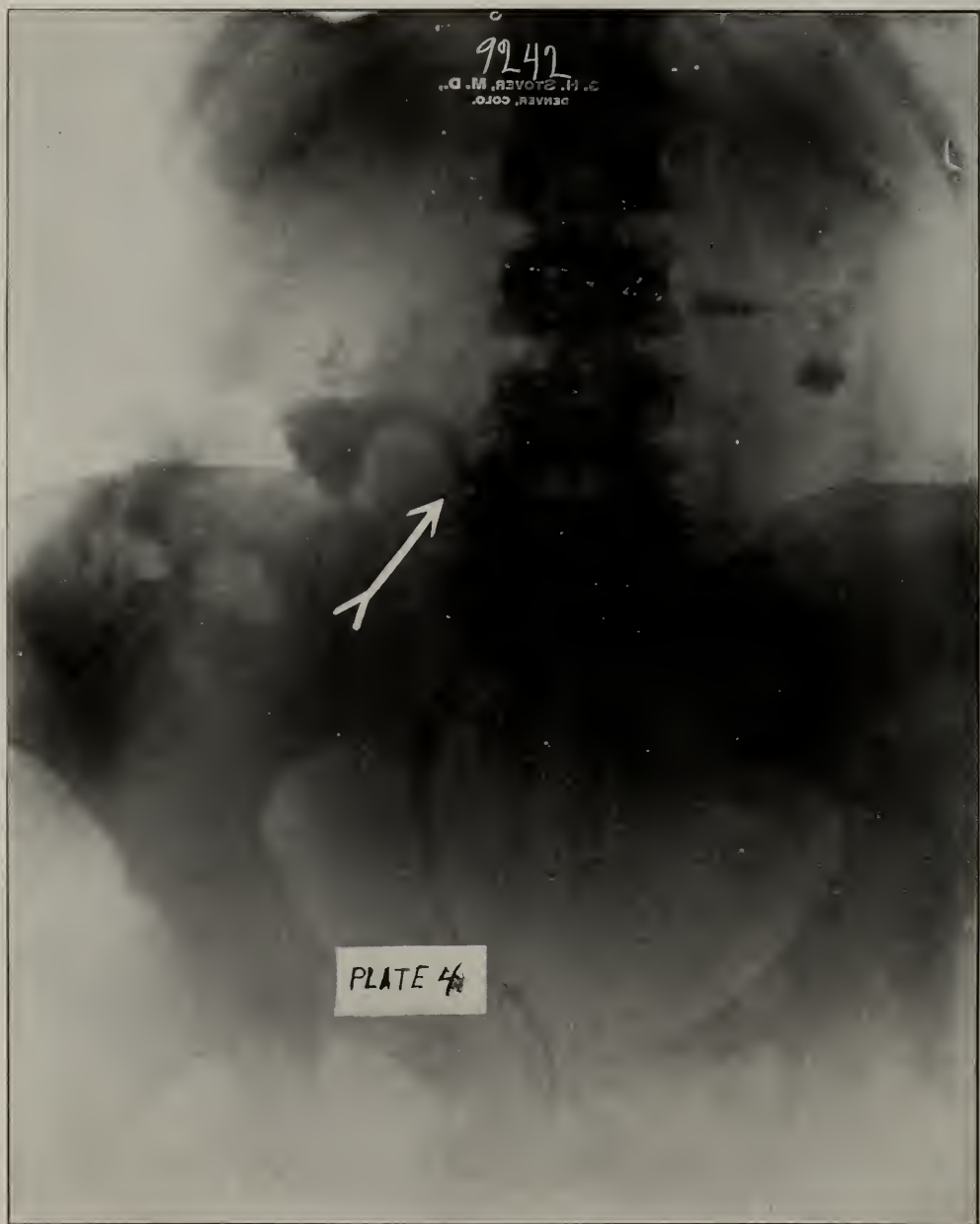

PLATE 3.

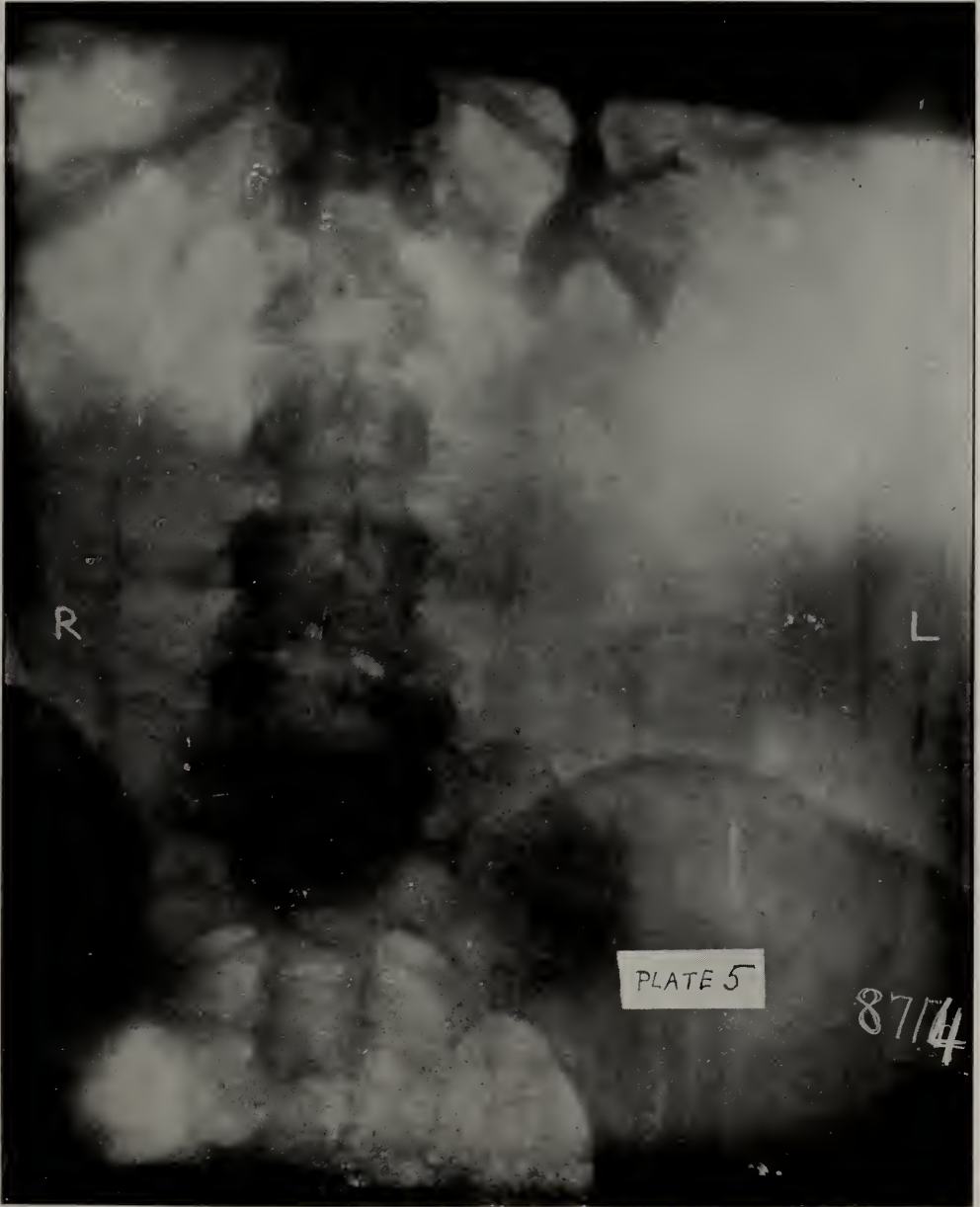G. H. STOVER, M. D.  
DENVER, COLO.  
1476

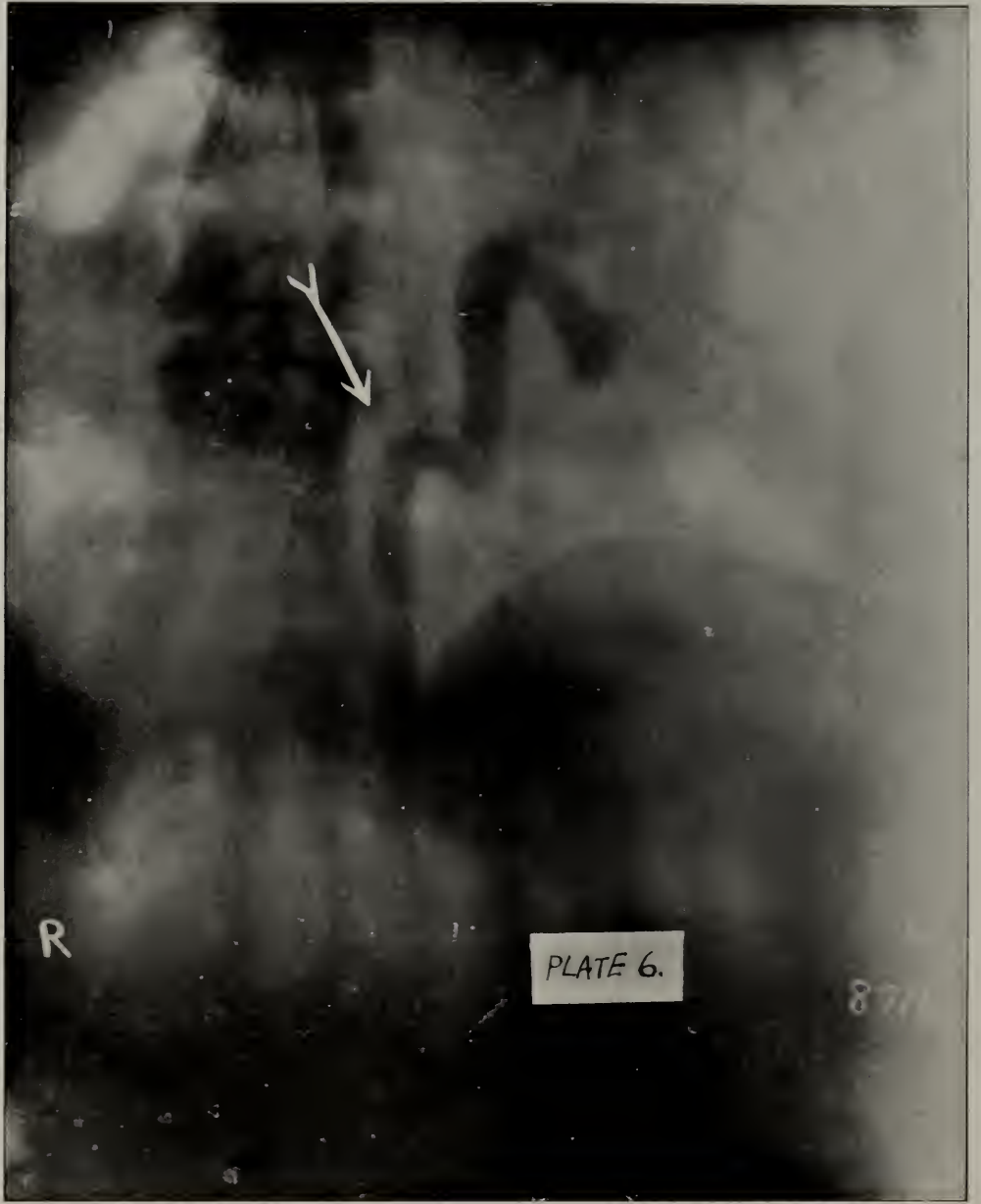

9242  
C. H. STOVER, M. D.  
DENVER, COLO.

PLATE 46



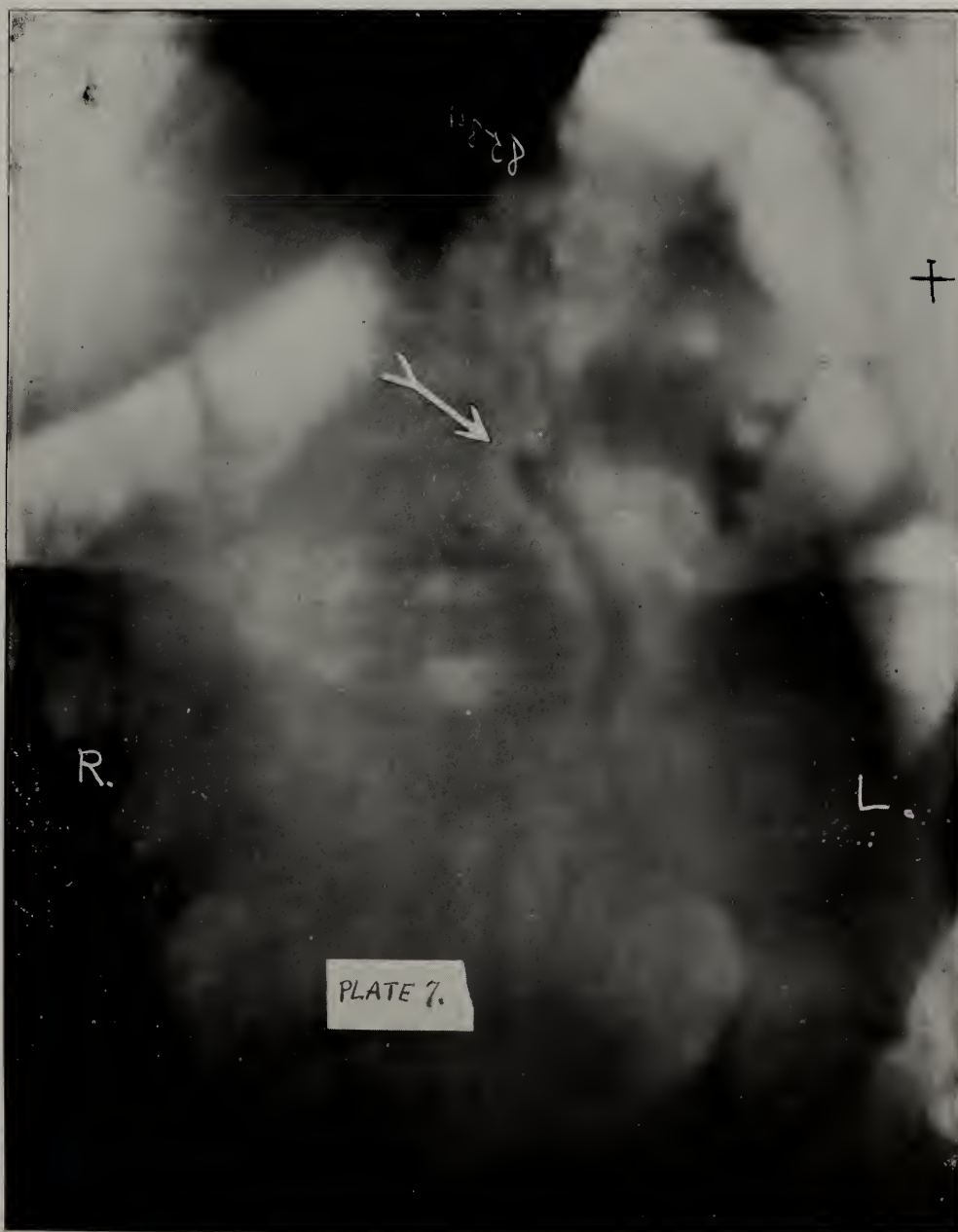




R

PLATE 6.

8711







ureter of the descended kidney over a connective tissue band. This band divided and the kidney elevated and fixed. Complete relief. This patient had a bifurcation of the renal pelvis.

Mrs. R. W. Plate 3, recumbent; plate 4, erect. Right kidney has a double ureter in the upper six inches. Kink due to twisting of the two tubes when the kidney descended. As the left kidney was also movable a double nephropexy was done. Complete relief.

Mrs. S. J. W. Plate 5, recumbent; plate 6, erect. Kink due to aberrant vein over which ureter loops when kidney descends. Vein divided and kidney elevated and fixed. Complete relief.

Mrs. J. F. M. Plate 7, patient erect. Kink due to looping of ureter over aberrant artery, which was divided and kidney elevated and fixed, with complete relief.

Operation has always so far shown the kink to be due to an aberrant vessel over which the ureter loops when the kidney descends.

I take pleasure in presenting illustrations showing our Roentgenographic findings in some of the cases we have examined in this way.

---

## DISCUSSION.

DR. J. H. SELBEY, ROCHESTER, MINN.: I want to congratulate Dr. Stover on his work. Our experience with this work has been the difficulty of making these examinations. It is hard to control the patient unless you also do a cystoscopic examination. Their feet slip and they get very uncomfortable and when the time for the examination arrives, it is difficult to get them into the proper position. I am satisfied that there are quite a few of these cases which could be recognized if we carried out the technic which Dr. Stover has given us.

---

DR. PERCY BROWN, BOSTON: I had a case which clinically was pronounced as a nephroptosis but the Dietl's crises were out of proportion to the degree of ptosis. I made a Roentgenogram and found a kink in the ureter. A ptosis was present but was not startling.

DR. STOVER, CLOSING THE DISCUSSION: Our hospitals in Denver are not provided with proper Roentgen apparatus and all this work is done in my own office. Dr. Fowler makes the cystoscopic examination first. Then the patient is put on her back on an Allison table with the feet in the stirrups. Dr. Fowler makes the colloargol injection, I slip the plate under the patient and make the exposure. Then I get another plate. The patient assumes the erect posture, the doctor withdraws the catheter and I make another picture. The patient leaves the office in from thirty to sixty minutes in excellent condition. In that way we have been able to do this work satisfactorily.

## THE CONTROL OF FRACTURE WORK BY THE ROENTGEN RAY.

BY ROLAND HAMMOND, M. D., PROVIDENCE, R. I.  
Assistant Orthopedic Surgeon to Rhode Island Hospital and St.  
Joseph's Hospital.

It was only a few years ago that a major part of the Roentgenologist's practice consisted in making plates of fractured bones, and even today, with the marked advance of Roentgenology into the special branches of medicine, I imagine much of the routine work of this specialty consists in determining if a bone has been broken, and if so, whether or not the fragments are in proper alignment.

Up to the time of Roentgen's discovery, the treatment of fractures had made but little progress for many years, and time-honored methods, hoary with age, were used. The practitioner in blissful ignorance of the actual relations of fragments, made an apparently good reduction of his fracture, only to be confronted in many cases at the end of his treatment with a stiffened painful joint, or a deformity which stared the patients and his friends in the face, to the lasting opprobrium of the medical attendant. If the reduction has been anatomically perfect, the chances are strongly in favor of a good clinical result. Of course, poor results are occasionally obtained with the best treatment, but they are becoming less common as better methods of diagnosis and treatment are introduced.

The Roentgen ray has changed much of this. We can now determine accurately just what bones are broken and where; if the reduction has been properly made, and oftentimes if a splinter of bone or bit of soft tissue between the fragments prevents a perfect reduction. All this is done without causing the patient the slightest pain. A large proportion of the medical profession recognize these facts, the intelligent part of the laity are informed on the subject, and the courts are becoming convinced of the value of the Roentgen procedure. The time is near at hand when no fracture or joint injury will be considered to have been properly treated if a Roentgen examination has not been made. All this is well known to a body of

men engaged in this special work, but it is in connection with the value of the Roentgen ray in some of the special points of diagnosis and treatment to which I wish to call your attention. It is a well recognized fact that a Roentgen plate should be taken after an attempt at reduction has been made, to see if the desired result has been obtained. Of almost equal importance is a plate beforehand to know accurately with what condition we have to deal—a fact not appreciated by the profession at large. With the knowledge thus obtained, the reduction can often be easily made, and with but slight trauma to the parts. We see just what mechanical force or leverage is necessary, and how to apply it to the best advantage to accomplish the reduction, and without injuring neighboring structures. It is surprising to see the slight force necessary in many cases to reduce a Colles' fracture when we know the exact relation of the fragments beforehand.

In the routine treatment of fractures, I take plates in two planes, and while they are being developed, fit splints to the limb, prepare dressings, and have everything in readiness. Ether is then administered, and reduction is attempted with the plate at hand for reference. If the reduction seems to have been accomplished, the splints are applied temporarily, and another plate taken and developed with the patient still under ether. If the plate shows that the reduction has been satisfactorily accomplished, the splints are more carefully applied and the patient allowed to recover from the anesthetic. If the reduction is not perfect, another attempt is made, and another plate taken and developed, and so on, until the reduction is accomplished, or it is proved that the fracture is irreducible. This procedure occupies from a half hour to an hour at most, and is more satisfactory and much safer than frequent fluoroscopic examinations. The finer relations of the fragments are often missed when the fluoroscope is used, and besides with the plate we have an indisputable record of success or failure. The only drawback is the time consumed, but with well-timed exposures, rapid plates and strong developers the time is shortened, though at the expense of a beautiful negative. One can oftentimes determine if the fracture has been reduced while the plate is developing, but I have found it safer to wait until the plate is in the fixing bath, before making an absolute judgment.

There is a fairly numerous class of cases in which the fragments can not be held in position by the usual splints, and two



courses are open to the surgeon: (1) He can operate and replace the fragments, holding them in position by animal suture, wire or bone plates, or (2) they can be held in place by some external device, usually by extension and counter-extension. In many cases it is absolutely necessary to operate and restore the fragments to their proper position. If the fragments lock together well, no suture or plate is necessary. Oftentimes they can be held by animal suture, which is readily absorbed, and forms an ideal suture material if one must be used. Rarely is it necessary to use bone plates. Mr. Arbuthnot Lane has given a great impetus to bone plating by his remarkable success in these cases. Many cases are plated, however, which I believe could be as well treated by extension and counter-extension, and with greater safety to the patient, if the same thought and energy were used as is employed in operative procedures. We must consider the poor resistance of bones and joints to infection, and the tendency of the wire or plate to act as a foreign body and be extruded before we expose our patients to the risk of suppuration or joint stiffening, or leave a foreign body in the tissues. Most patients prefer not to be operated upon, if as good results can be obtained without taking that risk. These results can be obtained in a large number of cases if the patient will go to bed for two weeks—not much longer than the average operative case is confined.

I have recently treated several cases of transverse fracture of the lower end of the humerus, which could not be held in place by the usual ambulatory splints, or at any angle of flexion or extension of the arm. These were all held by means of extension and counter-extension, and good results obtained. They may serve as examples of this method of treatment in other parts of the body. It is based on the work of Bardenheuer and Graessner who have described their method fully in "Die Technik der Extensionsverbände." The details of this treatment have been further elaborated by my associate, Dr. Frank E. Peckham, to whom I am indebted for much assistance. The patient is put to bed on a Bradford frame with the upper arm in abduction at a right angle to the body, the forearm being held vertically by weight and pulley over the bed. The upper arm is strapped down to a board running beneath the Bradford frame, so that the arm can not be pulled up by the weight on the forearm. Traction is exerted on the arm by a band passing around the forearm just below the elbow, which is attached to a weight passing over the side of the bed. A strap around the

chest and axilla with weight passing over the opposite side of the bed gives the counter-extension. When the apparatus has been adjusted for a day to allow for the effect of constant traction on the fragments, the patient is taken to the Roentgen laboratory in bed and plates made without disturbing the apparatus. In many cases it will be found that the constant pull has reduced the fragment, or ether may have to be given to place the fragment in proper position, after which it is held by the apparatus. In one case too much weight was used, and the fragment was drawn away from the shaft. Removing a couple of pounds' weight allowed the fragment to slip back into its proper relation. Here the Roentgen ray is an infallible guide to the proper adjustment of the fragments, which can thus be made with precision.

Since callus formation does not begin until about the end of the second week, and union is usually firm before the end of four weeks, it is not necessary to put the patient to bed until nearly two weeks after the date of the fracture. Union will ordinarily be firm enough for the patient to be up and free from apparatus by the end of three and a half weeks. Thus we have attained all that could have been accomplished by an open operation, and with none of its attendant risks.

Two cases will illustrate the value of this method:

Case 1—Girl, aged four. Transverse fracture of lower end of humerus one inch above epiphysis. Seen on fifth day after injury, when fracture was reduced under ether, and arm put in acute flexion. Plate showed fragment in position. On seventeenth day plate showed that fragment had slipped out of position. Under ether on the next day it was again put in place as proved by a Roentgen plate. On the twenty-second day a plate showed that the fragment had again slipped. Put to bed the same day with extension and counter-extension. Plate on the twenty-fourth day showed the fragment held in position by the apparatus. Allowed up on the thirty-fourth day with the fragment still in position as proved by the Roentgen plate. The elbow was baked in the hot air oven, and passive movements begun. A month later there was a perfect anatomical and functional result.

Case 2—Boy, aged eight. Transverse fracture of lower end of humerus one inch above the epiphysis. There was marked induration and swelling around the elbow, and the anterior surface of the arm and forearm were covered with blebs, which

prevented treatment by flexion. An attempt was made to hold the arm at right angle by an external angular splint. Though the fragment was reduced it could not be held in place in the right-angled position. The arm was treated for a few days by the family physician until the blebs had disappeared, when the patient was put to bed with extension and counter-extension on the ninth day. A plate the next day showed the fragment much improved in position, but not perfectly reduced. Under ether on the thirteenth day the fragment was easily reduced as proved by the Roentgen plate a day later. Apparatus removed on the twenty-eighth day. The fragment was in perfect position, but induration around elbow still marked. Baking and passive movements begun. Case still under treatment, but marked improvement has been made in motion, and the function ought to be good.

Another difficult class of cases to handle is that involving both bones of the forearm. Here the problem of two broken bones, with four ends lying in as many different positions, taxes the skill and patience of the surgeon to the utmost. In setting one bone the fragments of the second bone may be forced out of place, and in attempting to remedy this, the fragments of the first bone, which have just been reduced, may be again disarranged. Many times it is impossible to make a proper reduction without an open operation. Here again without the Roentgen ray we are helplessly working in the dark. The same method is used as with the previous class of cases, except that I have never found it necessary to put the patient to bed. At times an intermediate plate, taken after one or two unsuccessful attempts at reduction have been made, will give the clue to the situation, and by applying force in the manner indicated by the plate, the bone will slip back into position.

Again two cases will illustrate the method used:

Case 3—Boy, aged eleven. Fracture of radius and ulna  $1\frac{1}{2}$  inches above the wrist in each bone. Reduction attempted unsuccessfully by another physician. Seen in consultation eight days later. Ether given and first attempt at reduction unsuccessful as to the ulna though the radius was put in fairly good position. The appearance of the plate made after this attempt led me to believe that mechanical force applied in a certain direction might effect the reduction. This was done and the subsequent plate showed the reduction satisfactorily accomplished.

Case still under treatment, but as the wrist joint is not involved, I see no reason why we may not expect a good result.

Case 4—Boy, aged eight. Fracture of radius and ulna about  $1\frac{1}{2}$  inches above the wrist in each bone. Reduction attempted twice under ether by a physician of whose skill in fracture work I have the highest opinion. In this case, guided by reference to Roentgen plates, I was able after two attempts to accomplish the reduction, which though not perfect, is satisfactory in a child with growing bones.

We have found in several cases, that reductions in children which seemed unsatisfactory from a Roentgenologic point of view, have shown perfect anatomical and functional results when plates were made a year later. As the bone grows a new medullary cavity is formed, and the bone becomes perfectly straight, usually showing no trace of ever having been fractured.

#### CONCLUSIONS.

The Roentgen ray, properly used, is an infallible control of fracture work.

Plates after reduction are an absolute necessity.

Plates before reduction are of great value in diagnosing the exact condition and in facilitating reduction.

Many cases now subjected to open operation and plating could be treated by extension and counter-extension after the method of Bardenheuer and Graessner with as good anatomical and functional results, and at less risk and greater comfort to the patient.

In many cases which seem irreducible, plates made while the patient is under ether and after successive attempts at reduction have been made, will often give the clue to the situation, enabling the reduction to be made without resorting to an open operation.

Some fractures are irreducible by the above methods and an open operation is necessary. In these cases an absorbable suture material should be used if possible, reserving wire and plates for cases in which the fragments can be held by no other means.



DISCUSSION.

---

DR. ARTHUR HOLDING, ALBANY, N. Y.: This is the sort of a paper we should give to our local medical societies. The laity believes that when the doctor says that he set the fracture he has gotten a perfect result. The majority of surgeons believe that when they have a good appearance on the outside they necessarily must have good approximation of the bone, but when a radiograph of the limb is made, it is often necessary to make some very trying explanations to the patient.

Only recently the use of plaster-of-Paris has gone out of vogue, and many other of the old-time tried methods have followed the plaster-of-Paris. Therefore, I was glad to hear Dr. Hammond speak of extension and counter-extension. In certain fractures this is a very necessary thing to do, and it is our duty to impress on the surgeon that this fracture work must be done differently from what it has, and that it must be controlled by the Roentgen ray. We cannot lay too much emphasis on this point. Fracture work will be more satisfactory to the surgeon and to the patient when it is controlled by the Roentgen ray.

Dr. Hammond mentioned the treatment of several varieties of fractures. I have found that the fractures which require the most attention and study with the Roentgen ray are the fractures at the shoulder and hip. In such cases the routine method of putting them up almost always increases the deformity, and while adequate methods have been described for the treatment of such fractures by authorities like Whitman, as, for instance, fracture of the neck of the femur, these methods unfortunately are used but little throughout the country. Instead of putting the leg up in flexion and abduction, and holding it in position so that the short fragment is in continuity with the long fragment, the general practice is to put the patient in bed and put on Buck's extension.

We must not be ashamed to advise the surgeon to sacrifice his pride and reset a bone when it is shown to be necessary by the Röntgen ray. That is the great trouble we have to confront



all the time. The surgeon has not protected himself in most cases so that he can do the work over. He is afraid to make a plain statement of facts to his patient. Once in a while we are in the trying position in which we have to protect both the patient and his surgeon,—not always a pleasing situation.

I would like to ask the doctor in relation to his treatment of epiphyseal separations at the elbow. One of the set rules of treating a fracture at the elbow is that if the olecranon process of the ulna is not broken, the arm should be put in acute flexion. In my experience that procedure does not work well when I tried it in two cases of epiphyseal separation. Certain fractures when we learn to study them with the Roentgen ray must be regarded in almost the same light as a major operation, and I feel convinced that the doctor is right in putting the patient to bed and putting on counter-extension to get a position of the fragments, and to keep that patient in bed for about as long a time as he would after a major operation. That is an important step in the right direction.

There is only one thing I have to offer in demurring to what Dr. Hammond said and that is with regard to the use of ether and immediately after to use the Roentgen ray. I have seen several instances where the spark has caused serious damage, even though the tube may not have been anywhere near the ether mask or can at all. The spark from the tube jumped to the iron bedstead and from there to the ether can. In one instance a serious conflagration resulted in which the patient was badly injured. I am not prepared to say that we should use chloroform to produce anesthesia, but when it is not contra-indicated I use it. If you use ether, be sure that the ether bottle is out of the room and that the mask is not anywhere near the patient when the tube is excited.

---

DR. LEWIS G. COLE, NEW YORK CITY: I think that Dr. Hammond has stated the principal objection to this method of examination, and that is the long time that it is necessary to keep the patient under the anesthetic if repeated attempts are made to radiograph him.

In the next issue of the Quarterly will be published a procedure which I use and which I think will aid us in overcoming the difficulty. While the method is not new, it may be new to

some of you. It is the use of bromide paper in place of plates. About ten years ago we were all working with bromide paper instead of plates. The advent of the screen has completely revolutionized this as it has stomach work and Roentgenology in general. By the use of bromide papers and the screen it is possible to make a radiograph which shows things with more detail than it is possible to obtain on the plate in from two to three minutes from the time the exposure is made. The first radiograph may be studied immediately after the second radiograph is made. The radiographs can be made as rapidly as it is possible to manipulate the machine.

This applies not only to fractures but to foreign bodies. It applies not only to the hands but to the spine or any other part of the body. The fact that the ray does not have to penetrate through the glass, the thickness of which varies with each manufacturer, naturally gives us a much better picture. I think you will see that the amount of rays which is cut off by this glass or screen is great and it can be done away with by simply passing the ray through the paper. The time of exposure is as short as one can possibly make it. You can use an exceedingly short exposure and use the entire output of the apparatus. For taking a picture of a frontal sinus in the antero-posterior position, the exposure by this method is about two seconds. I have been able to determine conditions by this method which I could not determine in any other way. It is most useful and entirely satisfactory..

---

DR. FRED H. ALBEE, NEW YORK CITY: I wonder whether everyone present today realizes the influence the Roentgen ray has had on the number of discussions held on the treatment of fractures. I think that the general surgeon was quite satisfied up to the advent of the Roentgen ray with the results he was getting in the treatment of most fractures, and it has been the Roentgen ray which has revealed to all of us that the treatment of fractures has been far from satisfactory. In fact it has been inefficient.

I want to speak especially of compound fractures of the hip and shoulder where it is impossible to determine by physical means the kind and extent of fracture or displacement without the Roentgen ray. We should plan the treatment entirely by what we find with the Roentgen ray.

In the case of the ulna there are two kinds of fractures which can be controlled entirely by flexion, without extension,—fracture of the epiphysis or near the epiphysis, the most common one is a separation of the lower corner of the humerus with a displacement of the head of the radius forward. The capsule that controls the head is firmly attached to that part of the lower end of the humerus, and when an injury occurs, with a powerful contraction of the biceps muscle, that piece of bone is pulled off and the corner of the humerus slides forward. That can be controlled absolutely by acute flexion. It pushes the head of the radius backward into position and also the fragment connected with it.

Another common fracture controlled by it is fracture of the upper part of the ulna, a dislocation forward of the head of the radius. Acute flexion will take care of that very nicely. If it is an early case you can by traction and pressing push the head of the radius back, and by acute flexion you can correct the angular deformity of the ulna. It also produces traction on the olecranon and pulls it into position.

As for epiphyseal fracture of the shoulder. Some years ago I was able to find that in a very large number of fractures of the shoulder in the neighborhood of the epiphyseal fracture, the head of the humerus was rolled up and in. The upper epiphysis of the humerus is unique in that all the rotary muscles of the shoulder are attached to it. It is the only instance in the body where that occurs. The action of these muscles pulls the head of the humerus upward and inward. It is impossible to control that upper fragment because no muscles acting on the arm lower down are attached to it. Therefore, traction is without any influence whatever. In my opinion the proper treatment of such a fracture is to place the arm high up on the chest and put on a spica bandage of plaster-of-Paris. It is an excellent material to use and the position is a comfortable one for the patient to endure, besides it is correct. You cannot control the upper fragment, therefore bring the lower fragment into position with the short fragment and hold it there. The long fragment can be controlled to that extent.

Whitman does the same thing in like fractures of the hip just below the great trochanter. These fractures have been treated for years by putting them up in a double inclined plane by abduction and flexion. The short trochanteric muscles pull the upper fragment into that position. The muscles are so powerful that we cannot control them by extension, therefore put



the long fragment into alignment with the short fragment. The same procedure can be applied to the knee.

If there is an epiphyseal separation of the lower end of the femur, the gastrocnemius muscle pulls the upper fragment back into the popliteal space, the epiphysis must get out of the way, so it slides forward. Flex the knee and the determining element in this position is removed.

In fracture of the os calcis, which is not infrequent, the deforming element is ignored by the best surgeons. The foot is put up at right angles to the leg, the tendo Achilles pulls the fragment up, and if the foot is dressed in that position, the patient is bound to have a flat foot of the very worst kind. The arch of the foot is completely obliterated. The only way to put it up is to flex the foot strongly so that the posterior fragment is held down. If you cannot hold it down do a tenotomy on the tendo Achilles and pull the fragment down. Then you will get good union, preserve the arch and save the patient a deformed foot.

---

DR. GEO. C. JOHNSON, PITTSBURG: I am glad that the discussion has taken the trend it has. Why the abdominal surgeon should be competent to treat a case of fracture I have never been able to understand. The only man in my opinion who is competent to do this work is the orthopedic surgeon, the man who controls his results with the Roentgen ray. The treatment of fractures in our textbooks should be rewritten by men who know something about the subject. The principles of applied mechanics are little understood by most men who treat fractures.

There has been one point omitted in the discussion and that is the importance and necessity of making stereoscopic examinations of fractures about the shoulders. There is no other way in which one can make an exact diagnosis of the kind of fracture and the displacement of fragments. If you will do this you can direct the proper setting of such a fracture and get good results and at the same time give the patient comfort during the treatment and a useful arm afterward which must be considered. Practically every case must be treated in a different way.

---

DR. COTTON, BALTIMORE: I would like to emphasize the remarks made by Dr. Johnston and by Dr. Albee. It is the province of the orthopedic surgeon to treat fractures. He has a proper knowledge of the anatomy involved, how deformities are produced, what is necessary to reduce them and the necessary

mechanical ability to retain the fragments in a position so that the result will be a good one. If he also has a knowledge of what use the Roentgen ray is in this work, or has some one associated with him who can help in that direction, all these fractures can be treated in a most successful manner.

I think that this discussion has gone into the realm of general surgery rather than into Roentgenology. This is especially interesting at a time when so many surgeons recommend the open treatment of all fractures according to the method of Lane of London and Huntington of San Francisco and others.

It is a great mistake if men cannot appreciate the points brought out by Dr. Albee, how these deformities are produced and what must be done to reduce them. For instance, in a case of fracture of the upper end of the femur where the upper fragment is pulled upward and is rotated outward. The proper method to control that fracture is to release those muscles, reduce the fracture and keep the muscles relaxed. At the Mercy Hospital in Baltimore we use an apparatus made by Downey of Atlanta, Georgia. We put the limb in flexion and slight abduction and outward rotation. We have used his table in about ten cases and in all we have had good union, good functional result, and in two or three cases there was absolutely no shortening and the patient was able to walk about in two and a half months. So, in fractures of the lower end of the femur if we appreciate that the upper fragment is drawn backward by the gastrocnemius muscle, we will reduce by flexion and not by extension.

The same principle applies to the shoulder and other joints. If we use these principles it is not necessary to resort to wires, screws or nails or any other retaining apparatus or appliance. If one sees the results accruing from the use of these measures, he will still more appreciate the value of conservatism in the treatment of any and all fractures. Another thing which we must remember is that it is absolutely necessary that we get an accurate apposition as well as good functional results. It is here that the Roentgen ray is the only means to be used.

---

DR. CLARENCE E. COON, SYRACUSE, N. Y.: There is no question that the orthopedists can treat fractures better than anyone else, but the fact remains that a large majority of all fractures have been and will be treated for many years to come by the general practitioner and not the surgeon. So that the effort we ought to make should be along the line as suggested by Dr. Hold-



ing, that of talking before the local medical society, give demonstrations of results obtained following the use of the Roentgen ray and show how these things can be accomplished. The Roentgenologist seldom treats a fracture. The proper man to this is the orthopedist, but much can be accomplished by the general practitioner if he will avail himself of the advantages offered by the Roentgen ray both in diagnosis and treatment.

---

DR. HAMMOND, closing the discussion: Dr. Holding spoke about the separation of the epiphysis at the elbow. I think that we must revolutionize our ideas as to treatment of fractures, and treat them not by textbook rules but by what we discover by Roentgen examination. It is stated in the textbooks that fractures of the olecranon should always be treated by extension. I have disregarded that in two cases, treating one with the arm in a right angle position and the other with the arm in acute flexion. If I had followed the textbook rule I would have separated the fragments, whereas by following the Roentgen ray I kept them in apposition. The results obtained in those two cases are proof of the correctness of the treatment.

As to ether and the Roentgen ray, I am very particular about that. The ether is removed to a distance, away over in the corner of the room, covered with wet towels and everything inflammable is removed before the tube is excited.

I was glad to hear Dr. Coles speak of how we can save time in this work. That was a weak point in my technic.

As to acute flexion, most elbow cases can be put in acute flexion, but we found one case which could not be held in acute flexion and it was a question of an open operation or something else, and I chose extension. It did the work, and the patient escaped an operation. The result was satisfactory.

## X-RAY DOSAGE WITH A UNIPOLAR X-RAY TUBE.

BY SINCLAIR TOUSEY, A. M., M.D.

Consulting Surgeon, St. Bartholomew's Clinic, New York.

Unipolar X-ray tubes are intended for use in the mouth, vagina and other cavities. There is only one wire, leading through the insulated stem of the tube to the cathode and transmitting a high potential current from an Oudin resonator or from one pole of a Tesla transformer. The anode or anticathode is fastened to the inner wall of the tube; it has no wire connected with it; but receives an induced or condenser charge when the tube is in contact with the body and the generator is in operation.

The more one works with the X-ray the more important seems the matter of dosage. This is strikingly evident in the case of a single application, where a suitable exposure for radiography will produce no perceptible effect upon the tissues; where a suitable exposure for a single massive dose of X-ray for a therapeutic application will produce the desired effect of depilation in a case of ring-worm or of destruction and cure in a case of epithelioma; and where a single over-exposure either radiographic or therapeutic will produce a terrible burn and ulceration. But even in cases where a series of mild applications are required, the result may be either no effect or a very beneficial effect or an excessive one according to the strength and frequency of the applications.

One should try to measure the intensity of the X-ray produced by a unipolar tube when operated by his apparatus so as especially to find out how many minutes contact exposure would amount to  $5\frac{1}{2}$  Holzkmnecht units or produce erythema.

If one has an ordinary X-ray tube and apparatus and technique which is known to produce this effect in a certain number of minutes at a certain distance, the following test may be made: Expose parts of a photographic film in black envelopes to the ordinary X-ray at one's ordinary treatment distance and for same number of seconds as the number of minutes required for an "erythema dose." Then expose other parts of the same film

in black paper envelopes in close contact with the unipolar X-ray tube for different lengths of time; the same number of seconds as the exposure with the ordinary X-ray tube. Thus there will be four different parts of the plate exposed and from it one may be able to judge whether one-half or the same or twice the time of therapeutic exposure with the unipolar X-ray tube in contact with the tissues will produce the same erythema dose that one's ordinary X-ray tube, apparatus and technique will produce at one's ordinary distance for therapeutic applications.

Two precautions must be taken with the unipolar X-ray tubes; it must be in contact with a conductor having approximately the same capacity as the human body since it does not give nearly as strong a radiance when the end is simply held up in the air; and one must bear in mind that the intensity of the radiance varies universally as the square of the distance from the anticathode. The distance from the anticathode to the mucous membrane is an inch or less with a unipolar X-ray tube and the mucous membrane would on the ground of distance alone receive four times the intensity of radiation received by tissues an inch deep and nine times that of tissues at a depth of two inches. Then again the X-ray consists of vibrations of many different wave lengths and degrees of penetration and if at all a deep effect is desired those soft X-rays should be arrested which would all be absorbed by the mucous membrane and limit the dose to the amount which the mucous membrane could stand without a burn. These soft X-rays must be filtered out by a screen of aluminum or several thicknesses of leather enveloping the end of the tube. This allows only rays of greater penetration to pass, but it must still be remembered that the surface tissues are receiving many times a stronger dose of these than the deeper tissues.

This determines the limit of safety for a single application or as the total of a series applied during a couple of weeks and to be followed by a period of rest lasting two or three weeks. Ordinarily less than this will be applied, while for some ulcerative malignant growth even a considerably larger and therefore destructive dose is desirable.

The important part of this is to know how to produce the effect which the case calls for.

SYPHILITIC MANIFESTATIONS IN THE LUNGS, RESEMBLING PULMONARY TUBERCULOSIS WITH REPORT OF CASES.

R. P. DANIELLS, M. D.

Attending Physician St. Vincent's Hospital, Chief of Staff Thalian Tuberculosis Dispensary, Toledo, Ohio.

H. W. DACHTLER,

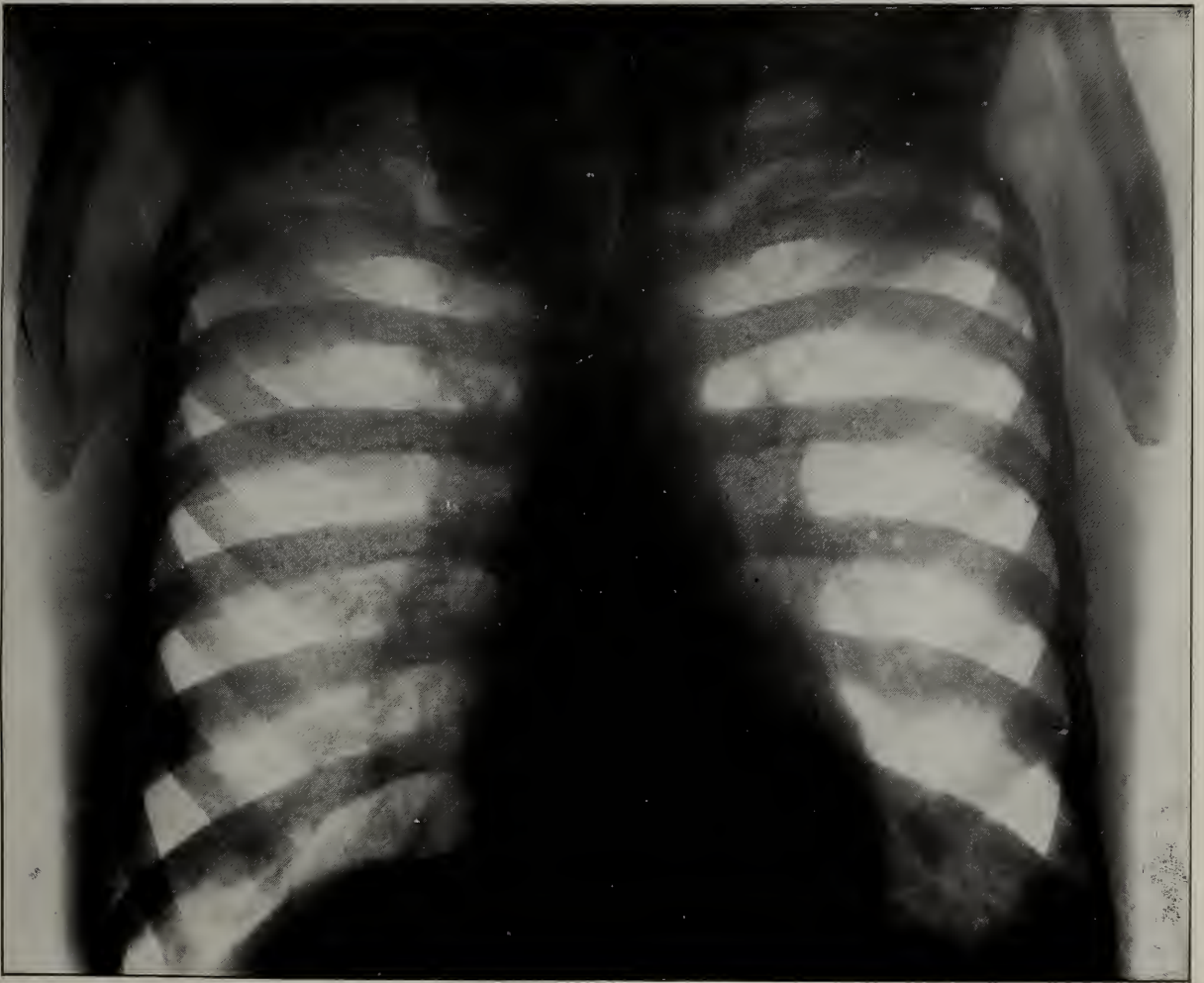Roentgenologist to Toledo, St. Vincent's and Flower Hospitals, and the Thalian Tuberculosis Dispensary.

During the last three years, in examining about one hundred and fifty cases for pulmonary tuberculosis and studying the condition of the lungs with the help of the Roentgenograph, we found most of the cases to be uncomplicated tuberculosis; a few were mixed infections of tuberculosis and syphilis, while eight cases were seen in which the lung changes were due to syphilis, and which might easily have been mistaken for a pulmonary tuberculosis.

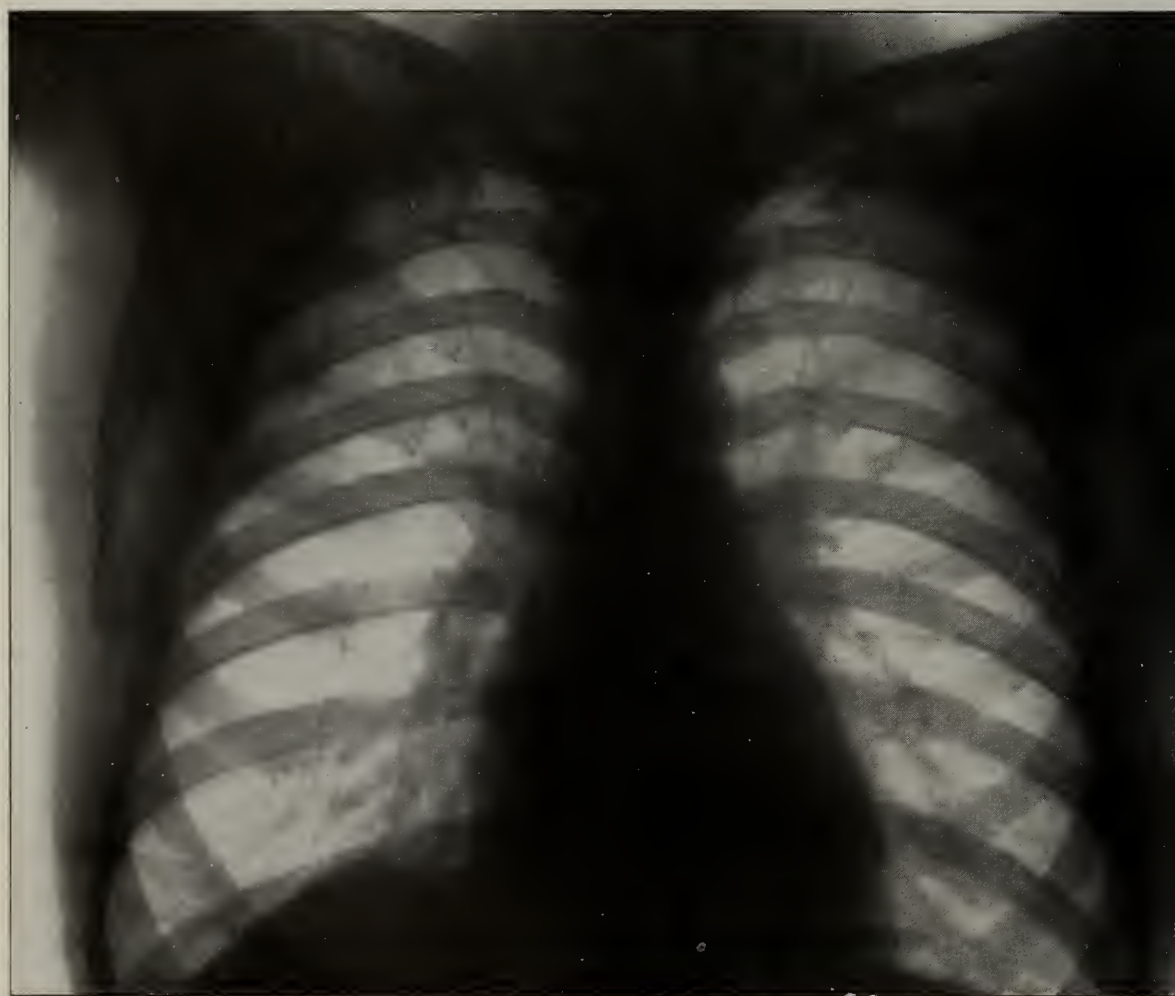These eight cases consulted a physician because they were losing weight, running a slight temperature, some had a little dry cough; all were easily fatigued; and they or members of their families suspected beginning consumption.

These cases are reported because they suggest that a syphilitic condition occurs more frequently in the lung than is usually suspected, and because they may closely resemble the early stages of pulmonary tuberculosis. In all the cases tuberculosis has been eliminated, first, by no reaction to 12 mg. of Koch's old tuberculin given hypodermically, and, second, by no signs of tuberculosis demonstrable in the Roentgenographs.









Moreover, syphilitic infection has been proved either by a direct history of infection, or by a history of miscarriages with other syphilitic signs and symptoms, and in one case by the Wasserman reaction.

---

REPORT OF CASES.

CASE NO. I.—Male, age twenty-one years. C. F. B.

*A. Reason for coming to physician.*—Sent by father who feared patient was beginning to have consumption.

*B. History.*—Young man, single, clerk. Usual weight 175 to 180 pounds. Lost about 10 pounds during last four months. Has coughed for two months with some expectoration. Chills easily. Family history good, personal history negative, except as stated later.

*C. Examination.*—Percussion of lungs showed slight relative dullness in the upper part of right lung both before and behind; vocal fremitus increased over the same area. Crepitant and subcrepitant rales over both lungs. The apex of the heart was in the fifth intercostal space in the nipple line; soft mitral systolic murmur. Systolic blood pressure 105 m. m. of mercury by Stanton manometer. Hemoglobin 80% (Dare). Red blood cells, 4,640,000. Faint traces of albumin in urine, no casts. Slight rise in temperature every afternoon up to 99.5 F. Pulse slightly accelerated.

*D. Proof of no tuberculous infection.*—Did not react to 12 mg. of Koch's old tuberculin given hypodermically. Showed no tuberculous lesions, old or recent, in chest by Roentgenograph. Symptoms cleared up rapidly under anti-syphilitic treatment.

*E. Proof of syphilitic infection.*—History of infection and chancre nine months before. This history was not obtained at first as patient did not wish his father to know of the trouble.

*F. Roentgenographic findings.*—Heart enlarged, position is normal. On the right side the diaphragm curve is normal. On

the left side the diaphragm is obscured by an increase in density of the base of the left lung, probably due to edema. Glands in hilus of lungs diffusely enlarged, but do not present any typical, discrete, caseated, nor calcified nodes, diagnostic of tuberculosis. Normal markings of lungs exaggerated. Gumma of the right clavicle near the sternal junction. No tuberculous infiltration extending along the peri-bronchial lymphatics toward the apices or lung borders.

*G. Remarks.*—There were no signs of syphilis on examination except those in the lungs. The patient had been on mercury intermittently. He was put upon heavy anti-syphilitic treatment and made an excellent and rapid recovery.

CASE NO. II.—Man, aged twenty-eight years. C. C. W.

*A. Reason for coming to physician.*—Sent by family who feared he had consumption.

*B. History.*—Young man, single, engaged in office work. Weight three years ago 149 pounds; weight one year ago 135 pounds; weight at present 125 pounds. Slight catarrh in head, coughing for seven weeks, no expectoration. Chills easily. Family history good; personal history negative except as stated later.

*C. Examination.*—Percussion of lungs showed very slight relative dullness over right apex in front. Crepitant rales over both lungs both in front and behind. Excursion of diaphragm normal. Heart normal with the exception that the first sound was soft and not definite. Ulcer on posterior nasal pharynx. Urine negative. Elevation of temperature up to 100 and 100.5 F. every afternoon. Pulse rapid, 100 to 110.

*D. Proof of no tuberculous infection.*—Did not react to 12 mg. of Koch's old tuberculin given hypodermically. Showed no tuberculous lesions by Roentgenograph. Condition cleared up rapidly on anti-syphilitic treatment.

*E. Proof of syphilitic infection.*—History of infection two years and three months before. This information was not obtained at first examination as some of the family were present and patient would not tell it.

*F. Roentgenographic findings.*—Heart small and vertical, as frequently seen in tuberculosis. On right, adhesions between diaphragm and pericardium. Lung changes not marked, but normal markings exaggerated for this age (twenty-eight years.) No evidences of tuberculous infiltration.

*G. Remarks.*—Patient was put on suitable anti-syphilitic treatment and his symptoms quickly cleared up. There were no signs of syphilis except the ulcer in the pharynx, and the lung condition.

CASE NO. III.—Man, aged thirty-nine years. M. N. T.

*A. Reason for coming to physician.*—He was “running down,” had no energy, looked badly, and was losing weight. Knew he had had syphilis, but did not believe his present symptoms were due to this, as he had taken a few weeks’ cure at Hot Springs and had been told that the disease had been “boiled out.” Thought he might have tuberculosis.

*B. History.*—Losing weight, night sweats, easily fatigued for last few weeks. Had elevation of temperature after exercise. Family history good; personal history negative except as stated.

*C. Examination.*—On percussion, slight relative dullness in upper third of right lung. Crepitant rales over both lungs in front and behind. Excursion of diaphragm good. Apex of heart in fifth intercostal space in nipple line. Heart dullness extended a little to right of sternum. Soft mitral systolic murmur. Hemoglobin 84% (Dare). Red blood cells, 4,560,000. Systolic blood pressure 95 m. m. Hg. by Stanton. Slight traces of albumin in urine, a few granular casts. Rise in temperature each afternoon. Pulse soft, regular, accelerated.

*D. Proof of no tuberculous infection.*—Did not react to 12 mg. of Koch’s old tuberculin given hypodermically. Roentgenograph showed no tuberculous lesions in lungs.

*E. Proof of syphilitic infection.*—History of infection twelve years before.

*F. Roentgenographic findings.*—Heart enlarged. Adhesion of inner border of diaphragm to pericardium. Some increase of density along the larger vessels and bronchi. No lesions char-



acteristic of an old tuberculosis nor any evidence of a new tuberculous infiltration from the peri-bronchial glands. *Roentgenograph of the lungs obtained post mortem did not show the slightest evidence of any tuberculous condition.*

*G. Remarks.*—Patient did not do well on anti-syphilitic treatment. During the last month he developed an acute nephritis on top of his former kidney irritation. Patient grew slowly worse, but was up and around to within a few weeks of his death, which occurred four months after first examination and which was due primarily to a myocarditis.

*H. Postmortem report.*—Autopsy done two hours after death. Lungs were found to be free from pleural adhesions and normal in every respect. Heart showed dilatation, with very little hypertrophy. Fine fibrous threads bound the heart to the pericardium everywhere. The muscle was very soft and flabby, the heart falling over the hand when held up by the apex. The valves did not show vegetations nor atheroma; the aortic valve held water. The aorta showed plaques of beginning atheroma. Coronary arteries showed some hardening. Signs of a chronic pericarditis and myocarditis were well marked, but there were very few signs of an old endocarditis. The kidneys were larger than normal, hard, firm and swollen. The liver was somewhat larger than normal, its surface marked with small pittings like the skin of an orange. Microscopical sections of the liver and kidneys showed increase in connective tissue. In other respects the post-mortem was negative.

CASE NO. IV.—Woman, age twenty-eight years. C. M.

*A. Reason for coming to physician.*—Not feeling well, losing weight, pain in chest, some cough, no expectoration.

*B. History.*—Woman, age twenty-eight, had been married, seamstress. Weight one year ago 135, weight now 108 pounds. Right breast had been removed two years before for carcinoma, no recurrence. Usually well and able to work. Had pleurisy pains in left chest, tenderness along some of the ribs, occasionally had a little fever. Menstruation irregular.



C. *Examination.*—On percussion, relative dullness over upper third of right lung, both in front and behind. Subcrepitant rales more or less all over both lungs. Friction sounds to left of heart in left axillary line. Excursion of diaphragm good. First sound of heart soft and not well defined. Heart not enlarged. Urine negative. Temperature ranged from 97° to 99° F. Pulse somewhat accelerated.

D. *Proof of no tuberculous infection.*—Did not react to 12 mg. of Koch's old tuberculin, Roentgenograph showed no indication of tuberculosis. Trouble cleared up on potassium iodide and mercury.

E. *Proof of syphilitic infection.*—History of infection two years before, with treatment intermittently. Gave a positive Wasserman reaction.

F. *Roentgenographic findings.*—Heart slightly smaller than normal. Some increase in lung density, most marked at hilus. Normal markings much exaggerated for her age. The apparent difference in density of the two sides is due to the fact that one breast has been removed for carcinoma. Gumma of left clavicle at the inner third which had to be differentiated from metastatic carcinoma. No evidences of tuberculosis.

G. *Remarks.*—Pleurisy improved greatly and general condition became much better when put on mercury and potassium iodide. Patient still under treatment and improving.

CASE NO. V.—Woman, age thirty-seven years. B. C. W.

A. *Reason for coming to physician.*—Indigestion, losing weight, running a temperature, cough and expectoration, generally "worn out."

B. *History.*—Woman, married, age thirty-seven. Usual weight 135, weight one year ago 100, weight now 87 pounds. Has cough with expectoration, vomits on account of cough. Appetite fair, has some constipation. Menstruation regular, flows four days. Has had three children living and three miscarriages. Severe "rheumatic" pains in legs.

C. *Examination.*—On percussion, upper half of right lung relatively dull, vocal fremitus increased, moist, crepitant, and sub-

crepitant rales. In the left lung, crepitant rales, old thickened pleura. Heart negative; urine negative. Temperature runs up to  $99.5^{\circ}$  nearly every day. Repeated examinations of sputum showed no tubercle bacilli. Lymphatic glands everywhere enlarged. Liver enlarged. Pupillary reflex gone, patellar reflex gone. Examination of eye showed beginning optic atrophy.

*D. Proof of no tuberculous infection.*—Did not react to Koch's old tuberculin. Roentgenograph showed no signs of tuberculosis in lungs. Improved promptly on potassium iodide and mercury.

*E. Proof of syphilitic infection.*—No direct history of infection could be obtained, but patient had had three miscarriages, had no patellar reflex, no eye reflexes, optic atrophy, and suddenly, while under treatment, had a paralysis of the muscles of the left eye. Patient stood large doses of potassium iodide, 180 grains per day for three months. Rheumatic pains left and patient gained in weight.

*F. Roentgenographic findings.*—Heart normal in size. Calcification of cartilage of first rib. Increased density of lower right lung. No evidences of old tuberculous lesions. Apices clear.

*G. Remarks.*—Lung condition has cleared up. Patient seems to be developing tabes dorsalis.

CASE NO. VI.—Woman, age thirty-four years. L. C.

*A. Reason for coming to physician.*—Cough, suddenly became cross-eyed. Some expectoration.

*B. History.*—Woman, age thirty-four, married fifteen years. Has had slight loss in weight, during last year. Is very nervous, has cough with expectoration. Six weeks before examination suddenly developed paralysis of external oblique muscle of left eye. Has "rheumatic" pains in legs and "all over." Has had cystitis badly. History of sores on labia years ago. History of many miscarriages.

*C. Examination.*—On percussion, both apices dull, vocal fremitus increased on right side. Rales over both lungs, large and moist on left side. Heart negative; urine negative. Elevation of temperature each afternoon.

*D. Proof of no tuberculous infection.*—Did not react to 12 mg. of Koch's old tuberculin. Rapid improvement on anti-syphilitic treatment.

*E. Proof of syphilitic infection.*—History of pregnancies: 1894, miscarriage at 7 months. 1895, child born at term, died at 7 weeks. 1896, child born at term, living. 1898, child born at term, living. Since then has had twelve consecutive miscarriages.

*F. Remarks.*—Is well after continued anti-syphilitic treatment.

CASE NO. VII.—Young man, age twenty-one years. H. A. E.

*A. Reason for coming to physician.*—Losing weight, coughed, had expectoration each morning. Told by his physician that he had consumption.

*B. History.*—Male, twenty-one years, unmarried, office work, weighed one year ago 145 lbs. This is the heaviest he had ever been. Weighed on first examination 133 lbs. Was getting pale, losing strength, had a cough with some expectoration on rising in the morning. He had been to one of the very best sanitariums and health resorts in this country where he was told that he did not have tuberculosis, but the true cause of his complaint was not told him. He was referred back to his family physician, who had sent him away with a diagnosis of pulmonary tuberculosis. Knowing that something was wrong with him, the sanitarium physician telling him he did not have tuberculosis and his family physician telling him he did, he came to us for examination and a diagnosis, sent by one of our old patients.

*C. Examination.*—Slight relative dullness over upper half of right lung in front and behind. Vocal fremitus increased behind, and in supraclavicular space in front. Crepitant rales over both lungs and sub-crepitant over right lung upper half. Excursion of diaphragm normal. Heart enlarged. Apex in fifth intercostal space, one-half inch outside nipple line, first sound of the heart soft and blowing. Blood pressure 120 M. M. mercury Stanton manometer. Temperature 97.4 at 9 A. M. Later the temperature range was found over two weeks to be from 97° to 98.6°. Pulse 92, soft. Haemoglobin 90% (Dare.) Cervical lymphatics enlarged, especially those under the chin and in front of the neck. Trace of albumin in urine. No casts.

*D. Proof of no tuberculous infection.*—Repeated examinations of sputum showed no tubercle bacilli. Did not react to 12 mg. Koch's old tuberculin in one dose.

*E. Proof of syphilitic infection.*—History of chancre on lip 2½ years before, known to have been received from a kiss. Patient did not try to conceal this infection, but did not think of it in connection with his present trouble.

*F. Roentgenographic findings.*—Heart enlarged. Diaphragm normal. Marked ossification in first costal cartilage. No marked increase in density of hilus shadows. No old calcified lesions of tuberculosis. No evidence of a new tuberculous infiltration.

*G. Remarks.*—Patient has now been under our treatment with heavy doses of mercury for a year and a half. Has long been symptomatically well. In six months he reached 150 lbs., a gain of 17 lbs., and more than he had ever weighed before.

CASE NO. VIII.—Man, age twenty-one. F. H.

*A. Reason for coming to physician.*—Coughed, felt very badly, weak, could not work.

*B. History.*—Patient thought he had consumption and presented himself at the Thalian Tuberculosis Dispensary for examination. He had cough, expectoration, fever, sweats, chills easily, lost 12 lbs. in 6 months, appetite poor, no gastric disturbances.

*C. Examination.*—Relative dullness right supra-clavicular region. Sub-crepitant, crepitant and moist rales over lungs. Heart negative. Chest of long narrow type. Further examination negative.

*D. Proof of no tuberculosis infection.*—No bacilli in sputum. No reaction to 12 mg. Koch's old tuberculin given at one injection.

*E. Proof of syphilitic infection.*—History of syphilitic infection one year before.

*F. Roentgenographic findings.*—Increased density of hilus shadows apparently due to diffuse enlargement of glands, otherwise normal.

*B. Remarks.*—Patient has been under active anti-syphilitic treatment for nine months—is to all appearance well, has been working for several months. The only danger is that he feels so well he will not continue his mercury as long as is advisable.



## CONCLUSIONS.

First, that during the secondary stage of syphilis, and even after gumma formation has begun, there may be a catarrhal bronchitis which closely resembles beginning tuberculosis, but which can be rapidly cured by anti-syphilitic treatment.

Second, that the catarrhal signs are general over both lungs and not localized, nor limited to the apices.

Third, that accompanying this catarrh there may be cough and expectoration, moderate elevation of temperature, emaciation, night sweats, loss of strength, and general debility, all of which symptoms resemble pulmonary tuberculosis, but which clear up rapidly upon the administration of mercury; much faster than a tuberculous process could under any treatment.

Fourth, it seems probable that, where cases of pulmonary tuberculosis treated with mercury and potassium iodide have shown great and rapid improvement, the condition has been one of syphilis or of syphilis and tuberculosis combined.

Fifth, from the study of these cases we believe that a syphilitic condition of the lungs occurs more frequently than is usually suspected and that, without doubt, it is often treated for pulmonary tuberculosis.

Sixth, all our cases have shown a relatively low blood pressure.

## CARCINOMATOSIS OF THE BONE, SECONDARY TO A GROWTH IN SOME EPITHELIAL ORGAN.

---

BY RUSSELL H. BOGGS, M. D., PITTSBURG, PA.

Carcinomatosis of the bone has received very little attention from the fact that the bony changes in most cases have not been sufficient to excite clinical notice. Since so much attention is now given to bone diseases, some of these cases are now being referred for radiographic examinations. The disease is never primary, always secondary. For this reason it is seldom recognized until a fracture takes place.

The first case that I saw was a patient who had been operated upon for carcinoma of the breast five years previous. She had had three operations, one three years after the first, and the third a year later. Her first symptoms were of severe pain in the region of the right hip and sacroiliac articulation. She had a few nodules studded over the chest, which cleared up under X-ray treatment. She had complained of the pelvis symptoms a month before she started to take treatment. Her physician insisted that she was hysterical and had become addicted to morphine.

While stepping off an elevator, she made a misstep and complained so much of pain that we were compelled to give her a half grain of morphine. Neither her physician nor myself made any examination of her hip, but a month later she insisted on having a surgical consultation. The surgeon at once pronounced a dislocation of the head of the femur and referred her for an X-ray examination.

The examination revealed bony changes, which might be described as honeycombing of the shaft.

I have seen three similar cases where spontaneous fractures occurred following carcinoma and three more cases where the spine and pelvic bones were affected.

Dr. G. W. Hawley describes a similar case to the one I reported and has dealt in detail with skeletal carcinomatosis in an article which was published in the *Annals of Surgery*, May, 1910.

I would like to mention another case briefly on account of extensive bony destruction in addition to mediastinal involvement.

This patient was operated upon six years ago for early schirrous carcinoma of the breast. She was in fairly good health for three and one-half years. Then she began to complain of pain in the lumbar spine and sacroiliac region. The pain was constant and she soon became bedfast. The radiograms showed extensive bony changes in the pelvis, spine and ribs. About a year later, radiograms were again taken, which showed very little more bony destruction. This patient did not have any external recurrence.

The cases mentioned were secondary to chirrous carcinoma of the breast, and none of the patients had a recurrence in from three to five years. This would seem that carcinoma of the bone is much more common in a slow growing form than a tumor of rapid growth.

I will quote the following in regard to the pathology from Dr. Hawley's article, as he describes it:

"Von Rencklinghausen found that the invasion began in marrow, which was usually found studded with nodules of cancer tissue. In the long bones these occurred most frequently in the expanded extremities; in the vertebrae throughout their bodies. This is in accord with the theory that the invasion of the bone occurs via the blood stream since Lexer has pointed out that the metaphyses are the most vascular parts of bone.

"These cancer nodules (usually found in groups) rarely attained any great size. Occasionally it was more miliary in character.

"This invasion of the marrow leads to a low grade osteoporosis (called by Von Rencklinghausen, 'osteomalacia carcinomatosa') which often extends from the central canal to the periosteum, with nests of cancer cells scattered throughout the Haversian canals. Extension to the periosteum is productive of a fibro-periostitis with formation of new bone. New bone formation also occurs in the marrow. These two processes, osteolastic and osteoplastic, as a rule, are not productive of extensive alteration in the architecture of bone."

In conclusion, carcinoma of the bone is not so rare as generally supposed and it is of clinical interest in connection with lumbago, chronic rheumatism, etc.

It has even been stated that metastasis in the bone is frequently the first evidence of a prostatic tumor.

---

## DISCUSSION.

---

DR. HENRY K. PANCOAST, PHILADELPHIA: I recall two cases of metastatic carcinoma of bone occurring at points distant from the primary lesion. One was a case of carcinoma of the breast of long standing, in which a metastasis occurred in the femur just below the great trochanter eight years after the breast was removed. Another was a case of carcinomatous degeneration of a branchial cyst in which the growth was removed and the patient given post-operative treatment. The metastasis occurred in exactly the same place. The post-operative treatment had been continued for several weeks when the patient complained of pain in the hip. I did not pay much attention to the patient until I saw the first case in which metastasis occurred. I then made a careful examination of the hips and found a beginning area of osteoporosis in exactly the same place as in Dr. Boggs' case.

It seemed significant that both these lesions which came from distant parts should occur in the same place exactly in both cases. I am also familiar with cases of metastases in the vertebrae. I merely mention the two cases because of the peculiar coincidence of the location.



DR. GEORGE E. PFAHLER, PHILADELPHIA: I am sure that if we look for these cases more carefully that we will find them more common than we believe them to be. We will find that these patients who complain of vague rheumatic pains after operation not infrequently have a metastasis in the bones. Unfortunately we do not, as a rule, look for any such trouble, even when there is a recurrence of the primary growth in the scar or elsewhere. Unless the patient has sustained a fracture, the condition is usually overlooked.

Not long ago I saw a patient who had a recurrent carcinoma in the chest. He had fallen and broken an arm. I examined the arm and found evidence of a metastatic carcinoma. I also examined the other arm and found metastasis there as well as in the thigh.

Two excellent papers have appeared in the German literature dealing with metastatic carcinoma in bone, one of the bones in general, the other of the spine. One man studied about 600 cases and his findings are most interesting. I am sorry that I cannot recall the reference in detail.

Another case that was exceedingly interesting, was that of an old woman who fell and struck her hip. It was believed that she had sustained an intracapsular fracture, and the surgeon in charge did not at first deem an examination with the Roentgen ray necessary. When that was done, there was found distinct evidence of a metastatic carcinoma. I then saw the patient and inquired whether she had had an operation at any time, and she answered in the negative. She had never had any symptoms indicating disease in any other viscus. I went over her very carefully and found a very small carcinoma in the breast, proving conclusively that you may have a secondary metastasis before the patient is aware of the presence of the primary lesion.

DR. KENNON, DUNHAM, CINCINNATI: Dr. Baetjer has had quite a remarkable experience with bone cysts. I wish he would point out the differences between these rarefactions and cysts.

---

DR. F. H. BAETJER, BALTIMORE: I have seen quite a number of cases of carcinoma metastases in bone, and it is rather curious how they locate. I have had four cases of carcinoma of the femur where the primary growth was in the breast. The next

place to look for these metastases is in the spine. It seems that the spine and the femur are the most frequent sites for these carcinoma metastases. I have had two cases of metastases in the humerus, both following a carcinoma of the stomach.

About two months ago a patient came to me with an osteomyelitis. The Roentgen examination showed extensive metastatic carcinoma involving about four inches of the bone. It was not fractured. It was moth-eaten. I reported a malignant growth, either sarcoma or carcinoma. The case was gone over rather hurriedly in the Out-patient Department and no growth could be found. She was advised to go to the hospital, but would not do so.

Nearly four months afterward she entered the hospital on the gynecologic side complaining of urinary symptoms. Examination disclosed a carcinoma of the bladder.

In a case of extensive carcinoma of the breast metastasis occurred in the femur and in the scapula. Then, we had one very curious case of carcinoma of the humerus. When we cut into it we were unable to tell whether it was a carcinoma or a sarcoma. It proved to be a carcinoma. The patient died. We were unable to find the primary growth at the necropsy.

As to the bone cysts. These are not malignant growths. They are benign. The only condition with which a bone cyst may be confused is a giant celled sarcoma, and that is practically a benign growth. In the ordinary carcinoma and sarcoma there is a focus in the bone, and on account of the wildness and rapidity of the growth, it spreads outward like spokes in a wheel. In the cyst the cortex of the bone limits the growth to a certain extent. The growth extends upward and downward in the shaft, but does not break through the bone. In the giant celled sarcoma the bone is swollen, bulges, with trabeculae where the bone has not been destroyed entirely. There is a very thin shell which is uniformly bulging. In the case of the carcinoma the growth extends out into the soft tissues. It is essentially a destructive growth, whereas the bone cyst is not.

Now and then you will see a bone cyst where one cannot say just what it is, but as a general rule, a growth that extends up and down the shaft of a bone, without breaking through the cortex is a benign and not a malignant affair.

---

DR. GEORGE H. STOVER, DENVER, COLO.: I have had occasion to examine four patients showing metastatic carcinoma of the bone, and in each case the primary lesion was in the breast. In

two of the cases the metastasis was in the humerus. In one case the condition was discovered accidentally twenty-five years after the original operation on the breast when the patient sustained a fracture of the bone.

---

DR. CLARENCE E. SKINNER, NEW HAVEN, CONN.: One case I saw may be of interest because of the oddity. The patient, a man, was sent to the hospital with a diagnosis of rheumatism of the neck. He held his head very stiffly and he had suffered much pain for about two years. Fourteen years before he had had a tumor removed from his breast. Twelve years afterward there was a recurrence in the scar. That certainly was a rather remarkable case.

---

DR. H. W. DACHTLER, TOLEDO, OHIO: My experience has been that these cases are rapidly fatal. I would like to know whether Dr. Boggs' patient is still alive.

DR. BOGGS: No, the patient is dead, but she lived six years.

DR. PANCOAST: Both the cases I cited were pathologic fractures. One patient lived long enough to get union.

---

DR. J. HUNTER SELBY, ROCHESTER, MINN.: I have had seven cases all together that were diagnosed as metastatic carcinoma. Two were in the upper extremity of the femur. One was a general carcinomatosis, so general, in fact, that we were afraid to make an absolute diagnosis. I rayed every bone in the body, except the head. The patient had been operated on two years before, a radical operation being done on the right breast and about two and a half years after the operation this condition came on. She was brought in on a stretcher and had such intense pain that we could not examine her readily. At last report that patient was still alive, although the prediction was made that she could not live more than two or three months.

I recall another case, one of tumor of the kidney which was removed. A year and a half afterward the patient had pain like sciatica, and she was treated for sciatica. When I made the

first plate I found a total destruction of the os pubes, extending to the acetabulum, and in another to the spine. None of my patients had a metastasis in the humerus.

I agree with Dr. Pfahler that if we look for these things we will find them oftener.

---

DR. BOGGS, CLOSING THE DISCUSSION: Just before leaving home I looked up some of the literature on these cases. I found that 14 per cent of cases of breast carcinoma have bone metastases, and 37 per cent of recurrences take place in thyroid carcinomas; 72 per cent of cases of prostatic carcinomas have no metastases. I think it was Dr. Kaufmann who collected 100 cases of prostatic carcinoma.



THE IMPORTANCE OF THE PROPER UNDERSTANDING OF THE RELATION OF THE ABDOMINAL VISCERA IN THE TREATMENT OF AUTOINTOXICATION AND AUTOINFECTION.

---

BY DR. JOEL E. GOLDTHWAIT, BOSTON, MASS.

The advent of the Rotengen ray set me thinking, and made me realize that while certain things had been met with often before, we had failed to recognize them, and that the Roentgen ray would in all probability help us to discover them and give these patients some relief at least.

My work has to do almost entirely with chronic medicine, and while bone and joint lesions represent perhaps the majority of conditions, how many paralyzes come to the orthopedist sooner or later to get his opinion. My attitude toward the progressive paralyzes has come to be much the same as my attitude toward rheumatism or tuberculous joint diseases; that there is some way out for these patients, and we must find that way. If we can find it, there is some satisfaction in our work which does not consist in putting on braces and giving exercises, which may help temporarily, but shortly cease to be of assistance.

My plea to you is that you study these cases as they come to you, and try to show in the plate all there is to show, because many times plates are seen where there are shown things that are as plain as the a-b-c, and yet the proper interpretation is missed by the medical profession, and even by the Roentgenologist. In other words, I am perfectly sure that if we will try not only to see what the Roentgen ray shows but the relation of what is shown to the general health of the individual, you will improve vastly the specialty in which you are all interested and widen the scope beyond that of mere technical value.

I have a series of plates which will show my feeling in regard to those conditions. In the first place, in the chest and abdomen we have the important viscera of the body, all except the brain, and the proper relation of these viscera, one to the other, determines health or determines disease. The Roentgen ray is of the greatest assistance in determining not only diseased conditions of these organs, but the position of these organs, and

not only the position of the particular organ which may be shown in the Roentgenogram, but the necessary result which must accrue to some other organ because of the position which the organ shown on the plate may have. And it is quite as much that which is not shown, but which we must see by reason and intelligence, that is often of the greatest value in the plate itself.

If the organs of the body are in correct relation to one another, the normal functions go on without interference; if, on the other hand, one organ is out of place, it is not only the one organ that is out of place, because all organs have distinct relations one to the others. The organ which is out of place may not suffer, but it may push some other organ out of place and make that organ suffer very materially. The thoracic organs may crowd and modify by change of posture the abdominal viscera which are more easily affected, because in place of the rigid thoracic wall you have simply a soft muscular wall behind which are more organs than in the thorax, organs which are much more mobile in anatomic relation and in which you have not only the organ itself, but in which you place the food products and material which have a distinct relation to health and the function of the individual part. Remember that one out of every five persons is born without normal supports of the abdominal organs. In the process of evolution the quadruped has a free attachment of its organs; they hang freely from the backbone, and there is no interference one with the other; everything is hanging from one line. When you make the quadruped a biped, you change the relation of these organs, and Nature provided that these organs should have a certain relationship to one another. The scheme of development is a definite one, and differs for each kind of animal only in the degree of progress that is made. The human is the last stage; the fish and bird stage come early; the changes which determine the human from the quadruped come later, and since that is the last stage it is the one which fails most often, and that is why one out of every five persons is born a quadruped.

That necessarily does not do any harm in itself so far as causing disease is concerned, and that is one of the first things I want to emphasize.

There has been a great deal of misunderstanding in that the Roentgen ray may show an extreme degree of ptosis of some organ, or a malposition, and yet that may not be of any special importance as a cause of disease.

A patient came to me with back pains. She was out of poise;

she had a sacroiliac strain because she was standing out of poise, and there was a visceral strain in front which was dragging her forward. If a person's viscera are hung from the diaphragm in the back, it leads to a droop posture, which this patient had. This patient had symptoms coming from this. The stomach was found to be down in the pelvis. To unload that stomach she had to get the waste to a higher level so as to pass on into the duodenum, and she retained her food for a longer time than was necessary, unless she assumed a certain posture. Her colon was practically below the crest of the ileum. That can only happen when there is a free mesentery on the ascending and descending colon. That woman had the visceral support of a quadruped and not of the human species. She got rid of the waste all right so that she did not suffer from auto-intoxication.

In these cases we must not simply see a prolapsed stomach or colon, but the general prolapse which is present. It is not simply the stomach and colon, but there is also a loose liver and loose kidneys. All the organs are free and loose. There is a mobile kidney.

In all of these cases there is no retroperitoneal fat. It either never was present or else it has been absorbed. There is no shelf for the kidney, and it is free and loose. To sew up the stomach is not enough to give relief in these cases.

There are certain ear-marks shown by these patients so that you can recognize the existence of this condition at sight, but you cannot tell the degree of malposition.

In another case the stomach was almost in its normal position. The waste was passed on into the duodenum comparatively easy. The second picture taken of that patient was of interest. The patient had a hypertrophic arthritis of his hip. That man had an acquired ptosis of the hepatic angle of the colon as the result of posture. If a person drops forward the ribs are pushed back; that pushes the stomach and liver back and down, and the hepatic flexure of the colon comes under the liver, and you get what this man had. The waste got into the ascending colon all right, but it was held back at the hepatic flexure and it was very slow in going through the colon.

Another man had a stomach not much lower than normal, as many individuals have, and it need not necessarily cause any inconvenience; but when taken in connection with a series of pictures that was made it is of significance. In six hours the food left the stomach and small intestine and was in the ascend-



ing colon and first part of the transverse colon. Two hours later some of the liquid had been absorbed, but the waste has not traveled any farther. Three hours later, or eleven hours after the ingestion of the meal, the waste is still in the same position, stopping, as before, near the splenic flexure. Twenty-four hours after the first picture was taken, some of the waste is seen in the splenic flexure, where it should be, under the ribs. But whatever has got there is seen to be in scybalous masses; the bulk of the waste is still in the ascending colon and first portion of the transverse colon. That means that there is something wrong. For eighteen hours the waste has failed to move.

A second picture was taken an hour and a half after the first. The stomach is seen to be unloading itself and most of the food is down in the small intestines. It is going through pretty well. In the third picture, taken three hours and fifteen minutes after the first, the stomach is seen to have unloaded itself; the small intestine has completed its work, and the food is in the colon. The ascending colon is down almost below the crest of the ileum; the transverse colon has sagged, but the descending colon is in its normal position. Here Nature's plan has partly worked out.

The next case I studied was that of a child. That shows that this condition is congenital as well as acquired. The child was six years old; all crippled up with rheumatism, a condition which was present since the child was a year and a half old. The child then had dysentary, and after that gradually developed rheumatism. The stomach was way down at the ileum. Of course, that was not the maximum amount of sag, but we can not change the condition of a child born with little support for its viscera. That child could live well as a quadruped. It would not have any symptoms, but as it is, the condition will go from bad to worse. That child is partly human and partly quadruped. There is a freer attachment for the stomach than there should be; the ascending colon is way out of place; the descending colon is in normal position. There is a dragging here all the time, so that the food and waste pass through the bowel with much difficulty. Here the Roentgen ray is of great value in determining the conditions present.

In the work we have been carrying almost every combination has been found, a firmly attached ascending colon with a free descending colon. The ascending colon in one case was free, except for about two inches in its middle, and the upper



part was folded over that and in the sigmoid was a great deal of gas. There are all sorts of combinations, but with the same fundamental trouble behind them all.

In six hours the liquids have been absorbed and the waste is worked together into a bolus. You can see plainly the gas areas in all the pictures taken of this child. In eighteen hours almost all of the waste has been passed through and it is out of the body in that time. But the thing that is striking is that in this ascending colon is still present a part of the bismuth meal. A patient may have a regular movement of the bowels, and yet in the pockets and pouches formed where the colon has been blown up and distended there are masses of fecal matter so firmly caked on the side that a blunt dissector is needed to loosen them.

That is what the Roentgen ray will demonstrate to you in these cases. It will show you what is present and also tell you what must be done to establish normal anatomic conditions, and until you correct these misplacements and malpositions, you can work from now until doomsday and not relieve these patients from their distressing symptoms.

In another case, a stomach large and distended was far down below the crest of the ileum. Usually the stomach is on the left side, but in this case it was on the right side. There was a free mesentery on the ascending colon, but the splenic flexure was in position. If the colon is in place, the stomach can not get out of place; the ascending and transverse colon is the natural ligament of the stomach. In this case, six hours afterward the stomach and small intestine had unloaded themselves; in twelve hours the liquid was absorbed, but the ascending colon was filled with waste, and little of it is seen in the transverse colon. In twenty-four hours most of the material has worked its way uphill, but some of it is still seen in the transverse colon and ascending colon. You can tell at once the rapidity with which the organs are working. In the case of the individual with the hypertrophic form of arthritis the question was what was making his organs work wrongly. Six hours after the ingestion of food there is still a lot of it in the stomach.

These things mean something more than just a picture with a shadow on it, and the thing we must do is to put our minds to work and take a series of pictures. If one picture does not show everything, take another, and study that until you know what the relation of the viscera is. Then stop and think of what

the effect must be on the other viscera, and you will explain a lot of things now only partly understood.

It is easy, for instance, to diagnose gall-stones and remove them. But what has caused their formation? In many of these cases you will find mechanical displacements which easily cause a kink, and which causes all the symptoms. You can not relieve these patients until you get those viscera to work right. The same is true of a loose kidney: Many of these patients can be benefited by the help which you get from the Roentgen ray and with proper training and study you can hold these organs in place. The treatment must be checked up with the Roentgen ray until you get the desired result. These patients must be nourished until you can see the retroperitoneal fat which they all lack. You can not keep these organs up in place when the chest is narrow or the body is compressed by the corset. You must make it possible to have the ribs flare so that these organs can stay in place.

The type of cases in which you have congenital ptosis is perfectly definite and you can recognize them at sight. These individuals lack poise and correct posture. The posture is the result of the ptosis. The Roentgen ray will show you and the patient just what is the trouble, and it indicates the treatment which must be pursued.

In normal cases with the viscera supported properly you have good nutrition. A heavy person, for instance, flops down and the ribs drop in pushing the liver and stomach downward, which may interfere with the colon and many other things. That condition is not congenital; it is acquired and causes quite as much disturbance as the cases in which there is a complete ptosis with absolutely free attachment of all the viscera.

That is the point to remember, and that is one of the chief things we must impress on the surgeon and physician. True, all the people who have these conditions are not sick, but, remember that one out of every five individuals is born with his organs out of place; but there is the functional condition, and it may cause trouble at any time.

## DISCUSSION ON DR. GOLDTHWAIT'S PAPER.

---

DR. PERCY BROWN, BOSTON: Every man will agree with me that such surgical support as this is the highest stimulation to roentgenologic progress. What we have already accomplished with reference to malpositions of the colon, merely is suggestive of what we may expect to do in the future and what additional information we are going to give the surgeon and the orthopedist. What else can we tell him that will help him in his work. What else is there remaining of information which we hope to get by experience. Mere suggestions as to the future are made by two or three observations of physiologic conditions which may prove inevitable.

As to the question of gastric peristalsis. I think that gastric peristalsis serves both as a cause and as an effect. One of the stock forms of information which we should give to the surgeon is information as to the peristaltic waves. We have not been able to do that until lately. We have not had it in our power to observe peristaltic waves sufficiently well before this. However, these waves exist and can be determined.

In the case of the little child whose case Dr. Goldthwait reported, it was only with great difficulty that we could get the child to take the bismuth which its stomach could hold and should hold in order to show peristalsis properly and plainly. Now, as to the question of intensity. Inasmuch as food goes to the ileocecal valve we have a field of the greatest interest to us as well as to the surgeon. At the ileocecal valve itself a new vista is opening up, one which appeals to the orthopedist and to the general surgeon; that is, abnormalities with respect to the passage of food just past the point where the appendix usually is or was. Why? Because many of these appendices are not seen until very much later than they should have been seen. Maybe they have been secreted with and without operation, and adhesions have formed. Right in that immediate region you get a distinct field of abnormality which causes a great deal of trouble. Of course, many of these patients do not come primarily to the orthopedist.

I remember a patient who came to me from one of our general men. She could place her finger right over the painful area

where she had had her appendix removed. Following, perhaps, the method of Dr. Crane, I placed a little piece of tinfoil right over the spot, and the kink was not 5 cm. from the painful point. That points the way for us.

Another interesting situation is just beyond, behind the turn of the colon at the liver, where, as Dr. Goldthwait showed you, the gut suddenly becomes small and the food trickles along.

Hertz, of England, wrote an admirable book on constipation. He calls that condition there one of hyperperistalsis, where apparently the succus entericus is stimulated and everything is ready for the food but none comes. Therefore from that spot on to the splenic flexure there is what Hertz calls a greedy gut, a contraction of the circular muscle fibers. When the food finally does reach this gut it is dry and hard and the contractions of the gut segment the food and it becomes shapeless.

As our technic improves we will observe more in regard to the duodenum, its anatomy, functions and pathology. There is nothing in the outlook for us which is really of more importance than this. Of course, every general practitioner will bring up the relative difference between the abnormal and the normal. It is difficult to say what is normal and what is abnormal. What would be quite normal for one would be distinctly abnormal for some one else. What we are looking for is a palpable cause, something that can be seen. A person presenting symptoms has something abnormal, and we must find out what is wrong with him, but to be convincing the evidence must be visible.

With reference to the little child Dr. Goldthwait showed you, no practitioner could receive a patient of that type without wishing that he could give help. The poor little thing was suffering from Still's disease. She was all tied up in a knot, dragging herself along with no vitality. Such cases are the stimulus to do something, and it is the province of the roentgenologist to render the necessary assistance.

---

DR. GEO. E. PFAHLER, PHILADELPHIA: I wish that the whole profession of the country might have heard this paper, and I hope that Dr. Goldthwait will continue his work because there is so much in it and there is so much more that he could tell if he had the time.

I would like to call attention to the work of Jordan, published recently, in which he spoke of the kink in the duodenum at its



junction with the jejunum which causes a spasmodic condition of the former leading to pain, symptoms of ulcer and sometimes of adhesions. I mention this because it can so easily be overlooked in a single examination. The condition may be present at one moment and not at another. To determine that it is present we must make a series of examinations or do considerable fluoroscopic work.

I have been very much interested in this apparent obstruction or reduction in size of the colon. I have seen all that has been demonstrated and more in my work, as most of you have, but I am confronted by this problem.

The doctor presents his patient. The patient details her symptoms, I point out these things and then the doctor asks me what will he do. I wish that Dr. Goldthwait would tell us what he thinks causes the retention of the feces just beyond the hepatic flexure and just the other side of the median line, the most frequent location, and what he considers the proper treatment for these conditions. If we can point the way for the general practitioner and set him thinking, we will have accomplished a great deal.

In the past week I examined two patients,—one who has had pain in the right side of the abdomen. I found evidences of adhesions between the descending and transverse colon and the sigmoid. One patient had been operated on for appendicitis, the other not, but in both patients the conditions present were the same.

There is a very definite reason for the existence of these conditions and there must also be a definite line of treatment, but when we come to these congenital obstructions, or even the acquired obstruction to the passage of the waste through the colon, it is a great problem to decide just what we are to do. Therefore, anything that Dr. Goldthwait can tell us as to the treatment will help us in our future work.

---

DR. ARTHUR HOLDING, ALBANY, N. Y.: I would like to ask Dr. Goldthwait one question in regard to these cases. They present themselves to us with some pathologic condition. We examine them and find these abnormalities, and then it is sometimes a question as to the relation of these two conditions to each

other. We have found more pathology. I would like to know whether the correction of these abnormalities is successful, that is successful in a therapeutic sense. Perhaps, we will find more pathology in these cases as the condition gets worse.

---

DR. CHAS. L. LEONARD, PHILADELPHIA: In these cases of obscure abdominal lesions where we know that there is some pathology present which is causing the disturbance and which cannot be discovered by the ordinary means, I make stereograms. In one case there was considerable pain at the iliosecal valve. The plate showed a stricture of the ileum. There were no perilead pencil. There was no history of appendical trouble, and the condition was thought to be of syphilitic origin. It is one of those cases referred to by Dr. Brown in which there is a lesion of the small intestine discoverable by the Roentgen ray, and now we are anxious to know what we can do for these patients.

---

DR. F. H. BAETJER, BALTIMORE: I have been fortunate to see many of these cases not only from the standpoint of the general surgeon and orthopedist but from the standpoint of the gastroenterologist, and I have found, as was stated by Dr. Goldthwait that we must examine these patients repeatedly.

I have in mind one patient whom I saw for a period of 179 hours, taking pictures at frequent intervals, trying to get rid of the bismuth in the cecum. I finally gave a drastic purgative.

In these pictures we see varying degrees of prolapse of the ascending colon in all the cases. In my cases there were only two where there was any change in the position of the splenic flexure. In both these cases all the abdominal viscera were in the pelvis; in no case did we get a bit of bismuth above the brim of the pelvis. I have not seen any case where there was a partial prolapse of the descending colon or splenic flexure. Does Dr. Goldthwait get these cases of partial prolapse, and when he finds the splenic flexure is it completely down or not?

---

DR. CLARENCE E. COON, SYRACUSE, N. Y.: We must be expert diagnosticians not only in the interpretation of the roentgenogram, but we should examine the patient by every known means.

We have patients referred to us for examination by the attending physician for examination of the stomach. Nothing else is wanted. These cases almost invariably represent the late types portrayed by Dr. Goldthwait, and I believe that it is our duty to follow the bismuth meal from the time it is ingested to the time it is expelled. In demonstrating these ptoses we have a duty to perform, that of educating the general practitioner, and he is slow to expect these things.

If we can show that there is absorption of toxins in these cases where feces are retained, it does not seem that any sane man could doubt the fact that it may produce a variety and multiplicity of lesions any one of which may be responsible for symptoms presented. These are chronic sufferers and we must give them relief from their trouble. I have found it difficult to convince doctors that in a great number of cases the colon is at fault when the patient was referred to me for an examination of the stomach. In one or two cases I was able to observe the patient for a week and the colon was still almost completely filled with bismuth. Almost invariably it had gone as far as the splenic flexure. Then followed free catharsis and free movement of the bowel. No one could fail to be convinced that there must be something wrong there, and yet we must educate the profession to the reasonableness of what we find and insist that they adopt measures which will give these patients relief.

---

DR. P. M. HICKEY, DETROIT: Some years ago I read Dr. Goldthwait's contribution to what he called rheumatism, and since then I no longer speak of rheumatism. Yet in presenting the plates of the child, he said that the child had rheumatism. I would like to inquire of Dr. Goldthwait what type of rheumatism that child had, and whether the arthritis present was directly due to the condition of the colon.

---

DR. KENNON DUNHAM, CINCINNATI: Dr. Brown referred to the fact that the practitioner is always calling for what is normal. It is not only the general practitioner who is calling for the normal but even the scientist wants to get as close to the normal as possible. Therefore, the normal anatomy of the

colon and of the stomach is something that must be defined thoroughly before we can go to any great length with this work.

In looking over Dr. Goldthwait's plates much was said about the hepatic flexure being so low down, and also that six or seven or eight hours after ingestion the bismuth had travelled only a short distance. I have made pictures of fifty stomachs and colons of people who are apparently normal and the same conditions were present to a certain extent as we saw in Dr. Goldthwait's plates. None of my subjects retained the bismuth in the stomach over seven hours, and in none was the hepatic flexure very high. I do not know just how high up this flexure should be, and I would like to know. It is uncommon in my experience to see the bismuth hurry from the hepatic to the splenic flexure.

The work of Cannon and Holzkecht has been very interesting, and I would like to hear from Dr. Goldthwait what he considers normal. The function of the colon does not seem to be to get rid of waste. I believe that in the first part of the colon there is a function that is far beyond that of merely getting rid of waste. The fat stays longest in the first part of the colon. It is mixed with the digestive juices in the small bowel and then it remains for a long time in the first part of the colon. So that there must be some physiologic function there. It is at the sigmoid flexure that we have the pocket for getting rid of the waste.

---

DR. W. H. EAGAR, HALIFAX, N. S.: I read Hertz's book on constipation and became very much interested in it. I think that he cited a sufficient number of cases to show that we can depend on the arrival of the bismuth meal in certain parts of the colon at certain specified times. He has done enough work on the normal subject to show that there is a definite time for the arrival of the bismuth.

It is a great credit to Dr. Goldthwait and the orthopedists in general that they have taken up this work. They are the ones who are advancing this subject in this country. We know well that in a number of cases constipation for twenty-four hours produces symptoms of what is ordinarily called a bilious attack. There is an acute infection following some stasis in the colon. In Dr. Goldthwait's work we are probably dealing with some intoxication from the colon which is producing the joint troubles. This is not, however, shown in a particularly acute form.



Where does this intoxication come from and where is it particularly located in the colon? That is what the roentgenologist must determine. Why is it that in cases where there is this delay in the passage of the waste just beyond the splenic flexure that there ensues such profound constipation? This does not last for a day or for a month but for many months. Why do not these patients show definite symptoms of intoxication. I have been very much interested in this subject and we owe Dr. Goldthwait a debt of gratitude for showing what he has accomplished in this line. It ought to stimulate us to further research.

---

DR. ROLAND HAMMOND, PROVIDENCE, R. I.: I am familiar with much of Dr. Goldthwait's work, and I want to add my tribute to the valuable work he is doing. I want particularly to emphasize the value of the treatment in these cases. I have observed many times that although we may not change the position of the viscera by our supportive and stimulative treatment we have at least given the patient relief from his symptoms. We may not have pushed up the stomach, but we have taken off the strain, the sag, and that is what the patient needed. By restoring the normal physiology by supportive apparatus and stimulating exercises, getting the musculature back to normal, we have accomplished what we intended to do.

I hope you will not lose sight of the fact that many members of this society were among the first to demonstrate this ptosis of the viscera, but it took the genius of Dr. Goldthwait to demonstrate the association between these joint lesions and this ptosis.

---

DR. JOEL E. GOLDTHWAIT, CLOSING THE DISCUSSION: It was not I who first called attention to the colon as the source of infection in these cases. Other men have pointed out the existence of this condition; for instance, Metchnikoff and Lane. I got a part of the suggestion which led me to take up this work from the members of this society. First of all, I wish to apologize for using the word rheumatism. The child in that case had Still's disease, or, as we term it, chronic infectious arthritis. It was being poisoned, although the primary infection did not come


from the intestine. That is what I want you to try to do when you study these cases,—use your common sense and don't say that it is the colon or the stomach. The patient is a human being with a lot of organs, whose balance and interrelation must be worked out.

I agree with Dr. Coon that it is the function of this society to educate the doctors in regard to this work. I am perfectly willing to help along the good cause.

In regard to the child. It had a condition which a few years ago I would have regarded as a tonsillar condition. Most of the cases of Still's disease are cases in which we find enlarged glands, with a stiff spine, so that the diagnosis can be made quite readily. However, chronic infectious arthritis is a far better term to use than Still's disease. That child had large boggy tonsils, and it had a chronic joint trouble. My work is in chronic medicine. Most of my patients represent the failures of my profession. I believe that there is a way out for all of them. They are human problems capable of solution by human intelligence, otherwise the scheme of the universe is wrong,—and it is not wrong.

There was something causing the joint symptoms but they were not causing all the trouble. If we had paid attention to that only, we would have been treating the patient from now until doomsday. The patient was sent to many different men, a throat man, an internist, and finally to Dr. Brown. My report to the parents was that I thought the child could be cured. I did not mean that the child would get normal ligaments on the colon, which I explained to the parents perfectly, and that was only one of a lot of things wrong, but I believed that we could put that child in a condition where the functions of the body would be performed normally; they would represent health. The first thing to do was to attack the tonsils.

A number of years ago we would have contented ourselves with only that, and then we would have wondered why the patient did not get well. That child had bad tonsils, and I believe that the primary infection in that case came from the tonsils, but there was something besides the tonsil. If there is a deranged stomach, there is a coated tongue; the whole pharyngeal wall is in the same condition, which we are apt to forget. That means that the crypts of the tonsils, which are small anyway, are closed, and the result is the infection. Many times a tonsil inflammation acts that way, and while the tonsil may be the place where the conditions become chronic, there is some-



thing wrong elsewhere, and that puts the child in a condition susceptible for an infection of any kind. A lot of other things come in the same way. It is our duty to ascertain all the trouble and say that it is only the tonsil or the colon.

I told the parents to have the tonsils removed, and that the child would probably be better for a few days but not to be disappointed if the child got worse again shortly afterward. The immediate improvement after the operation is not the critical thing, because that is only temporary. The child passed through the operation, was better for a few days, then gradually got worse as she began to take food. Then we began to give foods which made bulky stools and stretch the colon, obliterating the pockets and unloading the bowel. We are making that child do a lot of things to control the obstruction and infection.

With the organs out of place the duodenum may be pressed on and if the child has a loaded stomach it shuts off the duodenum and in the congenital ptoses you ought to know before the patient is operated on that there will be a gastromesenteric ileus unless you pillow the patient up in bed or place him on his side so that the duodenum can empty itself. That is very important. If you constrict the abdomen or allow the patient to rest on the abdomen, you obstruct the pancreas, and perhaps, that is a cause of sugar in the urine. I have only a theory about that, but some men believe that mechanical interference with the function of the pancreas is the cause of glycosuria. That is only a theory, but I know that the pancreas can be disturbed, especially by customing.

Dr. Pfahler spoke of the location of the kinks. Of course, if you have everything dragging down, the place where you get kinks is where the peritoneum makes alignment to hold certain parts back. It does that at the first and second portion of the duodenum, low in the ileum, close to the cecum where Lane described his kink, and third, where the sigmoid ceases to be sigmoid and begins to be rectum. Here the peritoneum holds the bowel up and pressure downward makes a kink, and frequently an ulcer forms at that point. Ulcer of the stomach and duodenum may be associated with this condition, and we must see whether it has something to do with it.

As to sewing organs in place, if done intelligently, it is all right, but if we sew up the stomach only, it will go down again to where it was in a few months. If you sew the kidney only, it, too, will return shortly to its normal position, as soon as the



new ligaments are stretched. If there is a special reason which makes suture desirable, all right; but it must be followed up by other treatment. The same is true of operations done to drain the bowel. The short-circuiting of the bowel which Lane is doing so much is faulty in that Lane sees chiefly the colon and not the other viscera, and while he gets some good results, they are not what they might be if he saw all the pathology in the case.

It is not only the colon which is causing the mischief. For instance, one reason why bacteria multiply in these cases is that there is not the normal amount of intestinal antiseptics, such as bile and pancreatic fluid. The bacteria may ascend into the duodenum, where they should not be. It is a complex subject, and we must hold to the idea that we are dealing with a human being made up of a lot of parts, and approach the case as one that is curable, capable of solution, and get rid of all ideas which our fathers put up to us that it cannot be cured because it has not been cured. Give up all terms which mean nothing, and you will get better results.

As to the prolapse. I have seen the same thing on the left side as I showed you on the right,—a free descending colon with a rigid ascending colon. Sometimes this occurs on one side and sometimes on the other.

As to results. We must use common sense. You cannot make normal individuals out of these patients, but unless there is some hope for them, medicine is pretty discouraging. These people will propagate, and their progeny will have these things; then we will have a weaker instead of a stronger race. There, again, Nature's laws come in. In breeding animals you can breed out one species and breed another in. So here. If we can prevent the acquired thing from forming, there will be a much lessened congenital trait. You cannot prevent the congenital condition, but you can treat the acquired cases and thus lessen the number of congenital cases.

My youngest boy has a congenital visceral ptosis. He is nine years old. He is never sick, but he has never been robust and well nourished. He was always having trouble; losing his appetite, followed by a ravenous appetite, clay-colored stools. After awhile we approached the problem from the common sense point of view, doing the things which really helped him, such as wearing a pad over the lower abdomen. Then he lies down with a pillow under his back, or humped up as he terms it. It tightens



the cervical fascia, the supporting ligaments of the diaphragm; it flares the ribs; tightens the abdominal wall; pulls up his stomach and colon. When he is digesting his food for half an hour after his noon meal, he lies that way. Then he turns over on his face over the end of the bed so that his thighs are separated, and hangs head down for five minutes, long enough for his muscles to relax. He sags down and lets everything fall down. He has been doing that for a year and a half, and since then he has had only one bad bilious attack, the result of going without his support, and he had filled himself up. The attack was cut short at once by simply standing him on his head. As soon as he leaves off his belt he has trouble.

I feel now that I can approach my patients and say that this or that is the source of the difficulty, and if we can only get it straight so that the organs work right, they will get well. You cannot always do it, but many times you can. The great difficulty is to get the physician and surgeon to look at these cases broadly. They see only a stomach or a colon or something else; that is not enough. It is only a part of the disturbed organism. You must nourish these patients; correct their posture, until the retroperitoneal, a sub-cutaneous fat tissue present, shows that the fat metabolism goes on as it should normally.

This is a tremendously big problem, and it is largely the work that you can do that will make the medical profession see these things as they are. We, who are working in chronic medicine appreciate this more than anyone else.

PRELIMINARY ANNOUNCEMENT OF ANNUAL  
MEETING.

---

The next annual meeting of the American Roentgen Ray Society will be held at Niagara Falls, N. Y., during the 11th, 12th, 13th and 14th of September, and the headquarters will be the International Hotel. It is the earnest wish of the Officers and the Executive Committee of the Society to make this meeting as great a success as any yet held, and to surpass all previous ones if possible. Those in charge will make every effort to attain this end, but just as much will depend upon the individual efforts of each member of the Society. It is hoped, therefore, that every member will do his or her part by at least attending the meeting.

The program is by no means full as yet, and anyone who contemplates presenting a paper is requested to send the title and a short abstract to the Chairman of the Executive Committee, Dr. Preston M. Hickey, 32 Adams Avenue, Detroit, Mich., as soon as possible.

It is our desire to have the exhibition of radiographs—both negatives and prints—an essential feature of the meeting. Every member will receive a request from the Exhibit Committee before long, but in the meantime begin to collect any plates or have any prints made which you wish to exhibit. Please begin this work now, and do not put it off until the last moment.

Another important feature will be a lantern slide demonstration. Each member who wishes to show slides will be allowed five minutes for his demonstration. Please do not put off getting your slides ready, but begin now.

It has seemed wise to follow the plan instituted last year of continuing the sessions through four days. There are many advantages to be derived from the addition of the extra day. All of us realize that the attempt to hurry through the usual program without any time for relaxation is tiresome, both physically and mentally, and that the mind is far better able to grasp and retain new ideas and important facts when refreshed by occasional periods of relaxation for body and mind. Then, too,

the extra day allows more time for discussions, which are often as valuable, or even more so, than the papers discussed. Furthermore, a few spare hours between sessions offer numerous opportunities for informal talks and discussions among small groups of members, and many of the most valuable ideas acquired originate from such informal discussions of the personal experiences and views of our friends.

It was decided at the Richmond meeting to hold no evening sessions this year, partly with the above idea in view, and also to give better opportunities for the study of the radiographic exhibits and inspection of the manufacturers' exhibits. Moreover, the social aspect of our meetings should never be disregarded. Although our Society is a scientific body, it is unique in many ways. We have been especially unfortunate in the loss of a large number of our members who have been martyrs to their profession and specialty, and this has created and should always maintain a strong bond of fellowship among us, and as many of us meet but this one time each year, the social side of our meetings is indispensable in the attainment of this end.

There is much of interest to be seen at Niagara Falls, and in order that all may have the opportunity of sight-seeing without interfering with the attendance of the sessions, it has been decided to devote one afternoon to one or more of the numerous excursions about the vicinity.

LEONARD RUE,  
Chairman Local Com.,  
841 Smith Street, Buffalo, N. Y.

DR. CLARENCE E. COON,  
Chairman Plate Exhibit,  
Syracuse, N. Y.

F. H. BAETJER,  
President.

H. K. PANCOAST,  
Secretary.

P. M. HICKEY,  
Chairman Executive  
Committee.

THE NEW ILFORD X-RAY PLATES appear to satisfy the requirements of the most exacting radiographer. The following is the report of an X-Ray specialist who was asked to give us an opinion of the comparative value of the new plates.

"I have tested these plates on every class of subject, from the simplest to the most difficult, and have not the least hesitation in saying they are quite the best I have used."

—ARCHIVES OF THE ROENTGEN RAY

# The Ilford

## X-RAY PLATE

*E. B. Meyrowitz*  
INCORPORATED

General Distributing Agents for America

104 E. 23rd Street

∴

NEW YORK

AGENTS CARRYING STOCK AT

*Chicago, Ill.*

*Atlanta, Ga.*

*Cleveland, O.*

*Washington, D. C.*

*St. Paul, Minn.*

*Pittsburg, Pa.*

*Philadelphia, Pa.*

*Los Angeles, Cal.*

*Buffalo, N. Y.*

Please Send for Particulars, Prices and Addresses of Agents





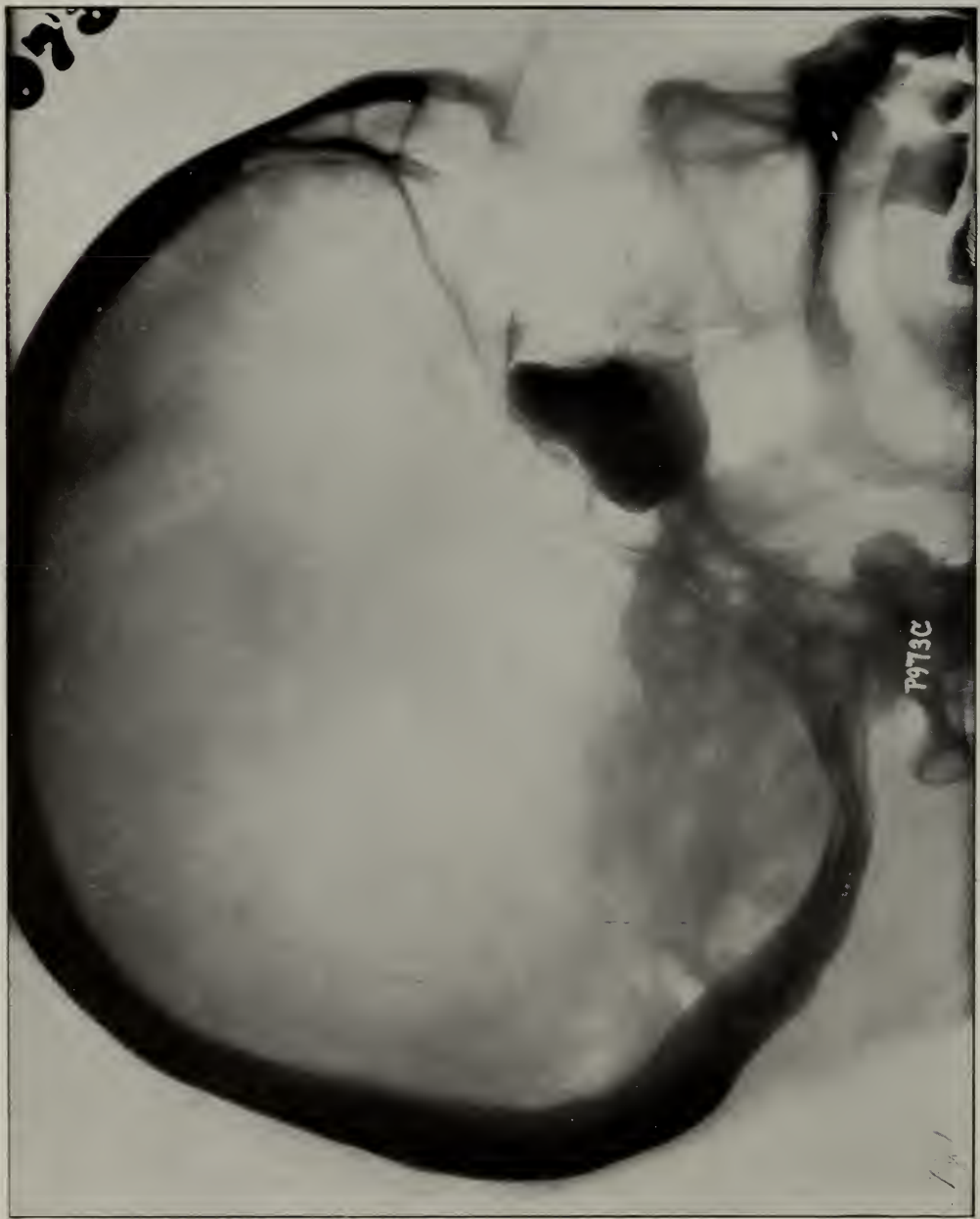

Fig. 1.—Shows lateral view of a skull in a cadaver, with the right sphenoidal sinus injected with bismuth contrast. Notice that the left sphenoidal sinus is not filled with contrast.

# American Quarterly of Roentgenology

*Editor, P. M. Hickey, M. D., Detroit*  
*Associate Editor, F. C. Zapffe, M. D., Chicago*

---

---

Vol. IV

NOVEMBER, 1912

No. 2

---

---

## THE ROENTGEN RAY AS AN AID IN THE DIAGNOSIS OF DISEASES OF THE SPHENOID SINUS

BY GEORGE E. PFAHLER, M. D.,  
PHILADELPHIA, PA.

In the introduction to this subject before the American Rhinological, Laryngological and Otological Association in May, 1912, Dr. Skillern very ably set forth the needs of aid in the diagnosis of the sphenoidal sinuses, in which he said that the diagnosis of sphenoidal diseases at best is not an easy matter, and oft-times requires repeated examinations before we can trace a purulent secretion to its origin. General symptoms may be marked and the local symptoms mild or entirely absent. A resection of one or both turbinates is often necessary before the sphenoidal wall is accessible to inspection and subsequent instrumentation.

The recognition of disease of the sphenoidal sinuses by means of the Roentgen Rays follows naturally the study of diseases of the other sinuses and involves only an amplification or refinement in the technique which has so successfully demonstrated disease in the other accessory sinuses. Therefore all of the long list of investigators who have contributed to the study of the accessory sinuses in general have paved the way for the demonstration of disease in the sphenoidal cells, and for this reason are included in the bibliography.

The general impression among Rhinologists and Roentgenologists has been that the rays are of little value in demonstrating disease of the sphenoidal sinuses. This impression must

arise either from faulty technique or from lack of skill in interpretation of the negatives that were made, and I believe the chief fault has been lack in interpretation. I find among my negatives made six and eight years ago distinct evidence of sphenoidal disease which I had not recognized.

Special work has been done along this line by Pfeiffer, Spiess, Scheier, Rhese, Bertini, Brunzlow, Marseblich and Schuller. Rhese has recorded more particularly the end results of the Roentgenological Studies. In his sixty-eight cases with Roentgenological studies, seventy-seven ethmoid labyrinths were found diseased in fifty-three patients, which were confirmed by operation. Among these cases the Roentgenogram showed no evidence of disease in two, in which disease was found at operation. In two others the evidence of disease was only slight, as shown by the Roentgenogram.

In thirty-one patients who came for operation forty sphenoidal sinuses were found diseased. Of these four were not recognized by the Roentgen rays. In none of these cases in which the disease was unrecognized was there a complete examination. Rhese lays great stress on the importance of the oblique view and concludes that where a postero-anterior and oblique view show no evidence of disease there should be no extensive operation undertaken.

He also calls attention to the fact that among the cases studied four showed disease Roentgenologically which was not found at operation. He concludes that previous disease probably resulted in granulation tissue which gave a cloudy appearance to the cells.

*Technique.* In the first place I believe we should always make our studies complete and I believe that a complete study of the sphenoid involves the other accessory sinus as well. This of course increases the time consumed as well as the expense, but it will go far toward eliminating error, and will at the same time I am sure often show more extensive disease than would otherwise be expected and by so doing the Rhinologist is given full information concerning all of the sinuses, and can treat at once all of them more skillfully, thus lessening the duration of the illness and in the end being distinctly economical.

In my judgment a complete study involves two postero-anterior exposures, two lateral (made stereoscopically) and two oblique. In certain cases to this might be added an antero-posterior and a vertical. When the exposures must be limited as much as pos-



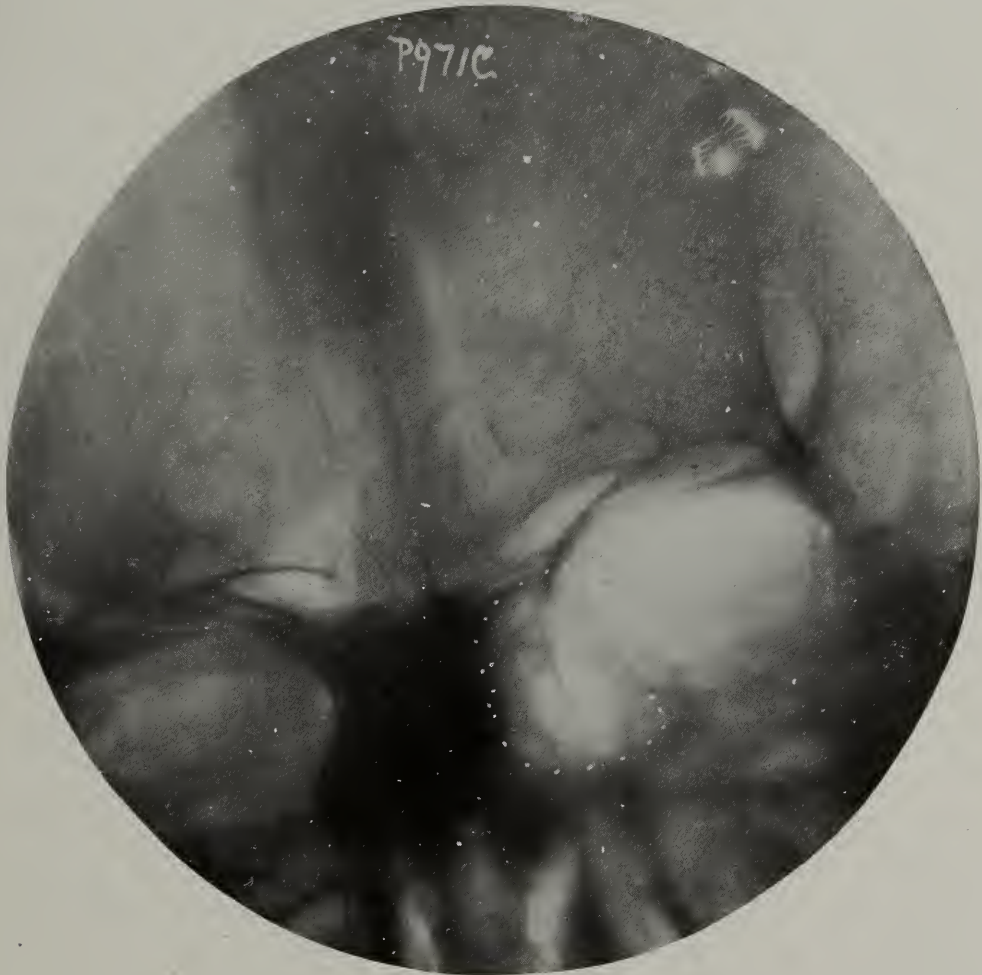

Fig. 2.—Right sphenoidal sinus injected with bismuth paste in a cadaver. Postero-anterior view. Notice the dotted outline of the left sinus which shows as clearly as the one injected.



sible on account of either the expense or condition of the patient one postero-anterior and one lateral view will give most information and in most instances will suffice for a diagnosis.

*The Postero-anterior View* (No. 1) is made by placing the patient in a prone position. (When circumstances actually demand it the patient may be allowed to sit up or may lie upon his back, but this will involve unusual or improvised appliances.) The plate is placed under the face so as to include the frontal sinuses and the maxillary sinuses. The tube is placed over the occipital region at a distance of 22 inches and located so that the central rays will pass through the median line and in a postero-anterior plane which extends from the base of the nose through the external auditory meatus. This position must be exact, otherwise if the tube is placed too high the area of the sphenoidal sinus will be projected downward over the middle turbinated bones, and if too low they will be thrown over the shadow of the cribriform plate of the ethmoid.

If the proper position has been used and a good plate obtained the reading of the negative from above downward will be as follows: (1) Frontal bone and brain tissue; (2) Frontal sinuses, not well shown; (3) Cribriforms plate with a few small ethmoidal cells below; (4) On each side of the median line (in a normal skull) a triangular transparent area, with rounded corners, the base of the triangle being in the median line or septum. These areas are approximately one-half to three-fourths inch in diameter. If they are diseased they will be opaque in proportion to the amount of exudate or tumor tissue contained. They may be irregular, deformed or absent. Their walls may be broken down by disease (such as syphilis) or they may be excessively dense as from osteoma; (5) On either side of the sphenoidal cells one will see the projected shadows of the posterior ethmoidal cells and below them the anterior ethmoidal cells; (6) Below this area are the nasal cavities with the middle turbinated above and the inferior turbinated below; (7) On either side of the nasal cavities are the large triangular transparent areas of the maxillary sinuses; (8) Projected into these sinuses one sees the shadow of the atlas bone.

*Postero-anterior Position* (No. 2) is made particularly to demonstrate the frontal sinuses and thereby find confirmatory or additional information. For this the patient is kept in the same position, the tube is kept in the median line, but is moved about two inches above the occiput. This will vary somewhat

with the shape of the head. The chief features in this negative will be the frontal sinuses above, and the lateral ethmoid cells below, lying just above the upper orbital brim. Below this are found the structures enumerated under position No. 1.

*The Oblique Position* is used for each side, and both sides should be made for comparison. The patient's head is placed so that the brim of the orbit is resting upon the plate. This will make the weight of the head rest upon the superciliary ridge, the nose and malar bone. The tube is placed at a distance of twenty-two inches from the plate and in such a position that the central ray will enter the opposite parietal region about two inches posteriorly and one and one-half inch above the external auditory meatus and projected toward the centre of the orbit.

If this plate is properly made the optic foramen will occupy the centre of the orbit, and to the outer side will be found the sphenoidal fissure. Then toward the median line will be projected the sphenoidal sinus— anterior to the optic foramen. Above this will be seen the upper brim of the orbit and above the orbit the frontal sinuses.

*The Lateral View* should be made stereoscopically when possible, because it will give clearer and more definite information concerning the sphenoidal sinuses, the ethmoidal cells and the sella turcica above.

When only one exposure is made the supposed affected side of the skull should be placed upon the plate. The tube is located at a distance of twenty-two inches so that the normal central ray will pass through the middle of a line drawn from the external auditory meatus and directed perpendicularly toward the plate. When stereoscopic plates are made this same central position should be found, and then the tube should be moved one and one-fourth inch anteriorly or posteriorly from this central point.

In the negatives or stereoscopic views one will then see posteriorly (1) the external auditory meatus, and anteriorly to this (2) the temporomaxillary articulation; continuing forward from this point is (3) the zygomatic arch, and above the zygoma are (4) the sphenoidal sinuses. The sphenoidal sinuses are bounded above by the sella turcica, below by the zygoma, posteriorly by the petrous portion of the temporal bone, and anteriorly by the anterior wall of the sinus; anteriorly to the sphenoid one recognises (5) the posterior ethmoidal cells; (6) the anterior eth-



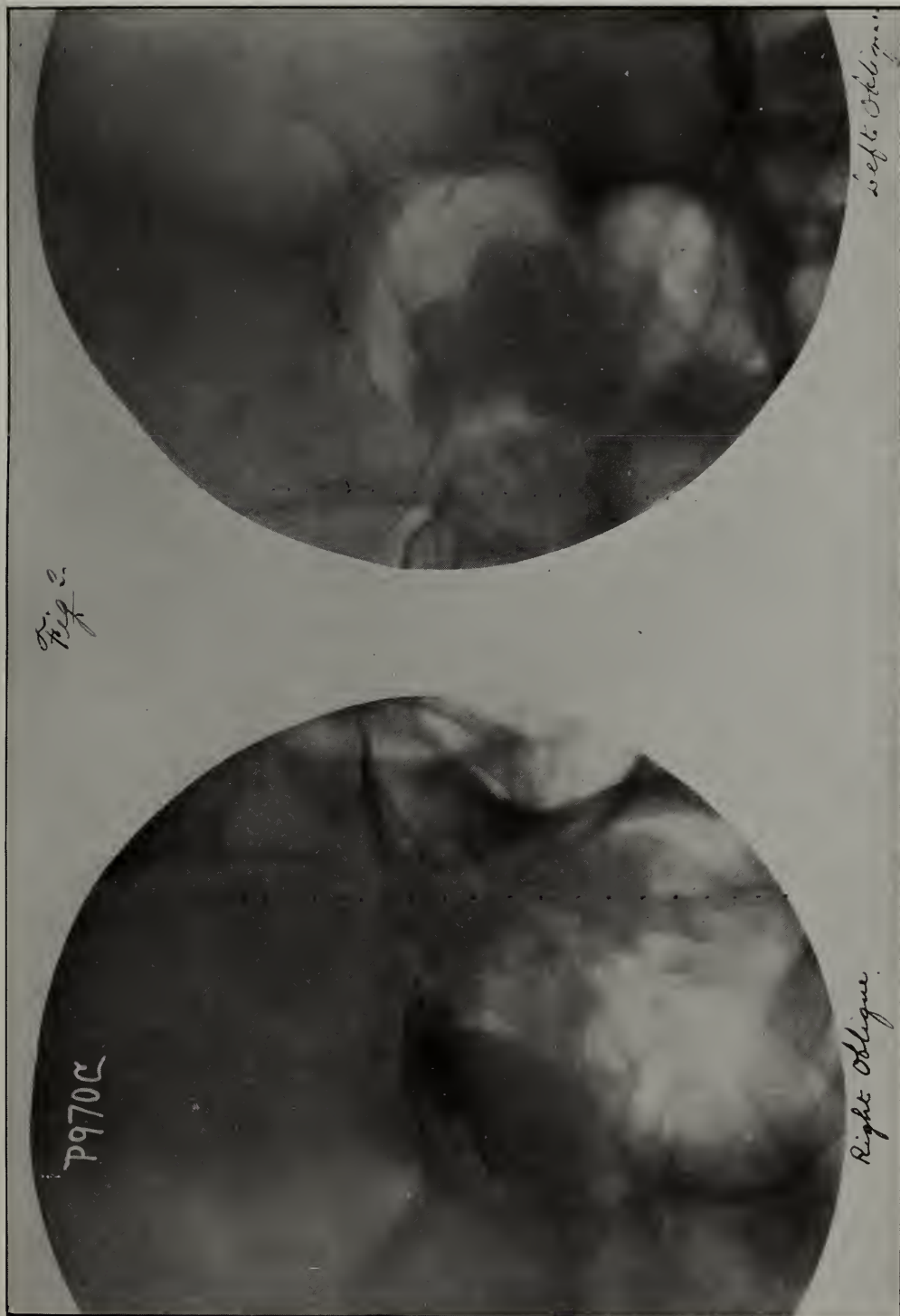


Fig. 3.—Right and left oblique view of injected right sphenoidal sinus. Notice how much further the injected sinus is thrown from the median line in the right oblique view. In the left oblique view the left sinus which is thrown into the outer side of the left orbit is perfectly clear.



moidal cells, and above and anteriorly to these cells (7) the frontal sinuses; through the ethmoidal cells can be traced the outline of (8) the orbit, and below the orbit (9) the maxillary sinus.

*The Antero-posterior View* is used in exceptional instances—when on account of the physical or mental condition the patient is neither able to sit up or lie upon the face, such as would occur in fracture of the base of the skull, abscess of the brain or marked dyspnoea. This position has been recommended by Marseblich and Schuller. The patient is placed upon his back, with his occiput upon the plate. The tube is then centered over the base of the nose. This will project the transparent areas of the sphenoid through the occipital region, and between the outlines of the orbits. An opacity of one or both of these areas, in a plate which showed good detail elsewhere, would indicate disease or exudate in one or both sinuses.

#### REMARKS.

The various accessory sinuses are recognized by the greater degree of transparency as compared with the surrounding tissues. Generally disease of these sinuses is associated with an exudate, which will diminish the transparency. When the sinus of one side only is involved, it forms a distinct contrast with the opposite side which should be clear. If both sides are involved, this fact can be recognized, providing the negative is good. A good negative will show clear lines elsewhere, even though the sphenoidal area may be quite opaque, and all lines may be obliterated.

If both sides seem to be diseased as is indicated in the postero-anterior plate, this fact can be more positively shown by the opacity of the sphenoidal sinus as is shown in the lateral, or stereoscopic views.

Not only are the Rays useful in diagnosing catarrhal and purulent disease of the sphenoidal sinuses, but valuable information will be obtained also in demonstrating the extent of new growths, and thus complete operation can be done when advisable, or a meddlesome operation may be avoided. (Marschick and Schuller have studied three cases of malignant disease of the sphenoidal sinus in which the floor of the sella turcica was absorbed.) Such new growths will include carcinoma, sarcoma, osteoma, exostosis, fibroma, cysts and mucocele. Infections such as tuberculosis and lues may be studied.

Other indications for a Roentgenological examination are to determine (1) the variety of the sinuses, whether to determine the absence of normal sinuses or to determine abnormal pneumatic space (Recessus supra orbitalis and hollow septum nasi); (2) accidents to the skull—foreign bodies, fractures or collections of blood in the sinus resulting from fractures at the base of the skull; (3) tumors of the accessory sinuses as well as of the base of the skull; (4) intracranial disease, especially hypophyseal tumors.

### CONCLUSIONS.

1. The demonstration of disease of the sphenoidal sinus by means of the Roentgen rays depends upon good technique and good negatives. Fluoroscopy need not be considered.

2. As much or more will depend upon the proper interpretation of the negatives as in the making of them.

3. The examination should include all of the sinuses and in each instance should be thorough. This will involve at least four different exposures and usually six or more.

4. Under the above conditions we believe that inflammations (catarrhal or purulent), infections (tubercular, luetic), and new growths (benign and malignant) can be diagnosed in most if not all instances with great accuracy.

### BIBLIOGRAPHY.

- Beck, Joseph C., *Photographic Atlas of radiography of the mastoid region and of the nasal accessory sinuses.* St. Louis, 1911.
- Bertini, *Anatomia radiografica sui seni sfenoidali,* Torino, 1911.
- Bornhaupt, *Ein Fall von linksseitigem Stirnhohlenosteom,* Langenbeck's Archiv, 1881, 26. Bd.
- Brunings, *Neue rontgenographische Darstellungsmethode der Nebenhohlen und Schläfebeine.* Verhandlungen deutscher Laryngologen, Dresden, 11. u. 12. Mai, 1910.
- Brunzlow, *Die Darstellung der Nasenhohlen und ihrer Erkrankungen im Rontgenbild,* Fortschritte auf dem Gebiete der Rontgenstrahlen, 1911, Band 17. Heft 4.
- Burger, *Die Bedeutung der Rontgenstrahlen in der Rhinolaryngologie.* Referat auf dem 1. internationalen Rhinolaryngologen-Kongress, Wien, 1908. (Als Monographie erschienen unter dem Titel: Was leisten die Rontgenstrahlen auf dem Gebiete der Rhinolaryngologie? 1908.)
- Caldwell, *Skiagraphy of the access, sinuses of the nose.* Amer. Quart. of Roentgen. January, 1907.
- Chiari, *Eine Modifikation der Schöfferschen Operation bei Hypophysentumoren,* Wiener klin. Wochenschrift, 1912, Nr. 1.



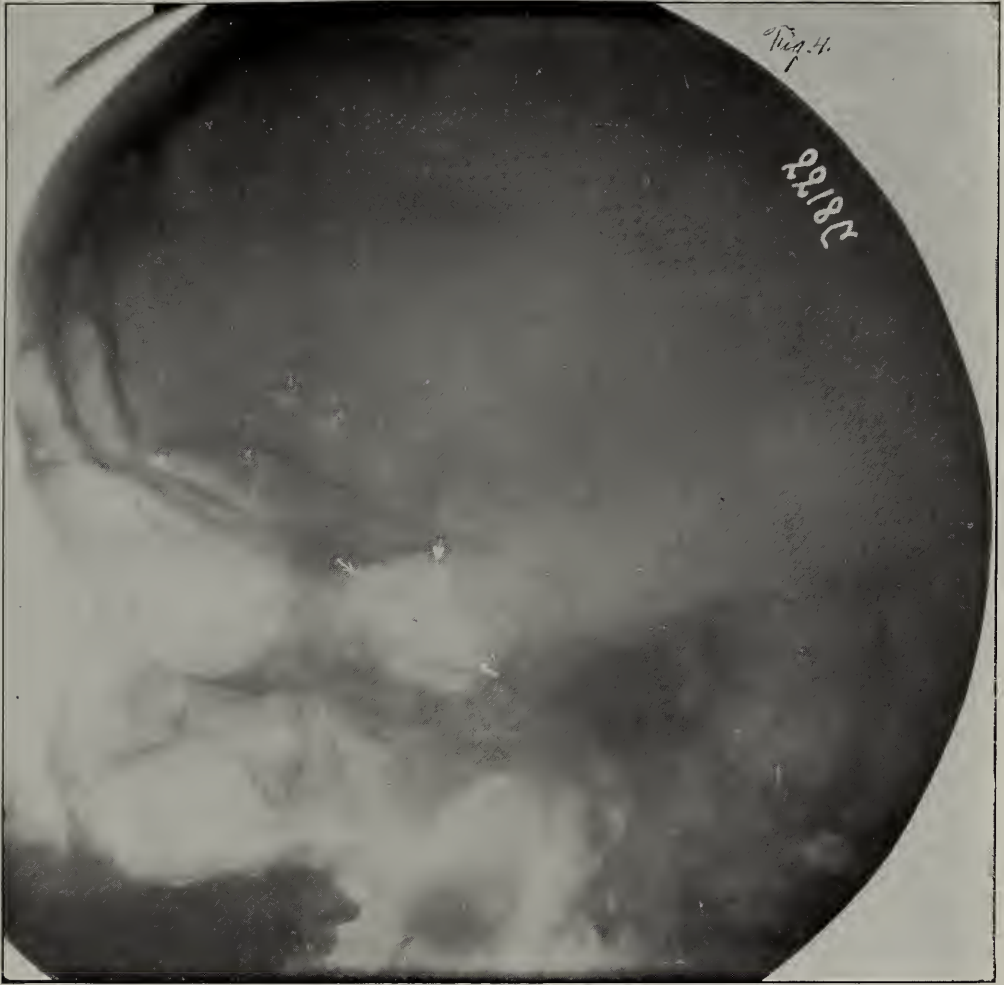


Fig. 4.—Lateral view in living subject, showing smaller left sinus, which contains slight amount of exudate projected inside of the larger right.



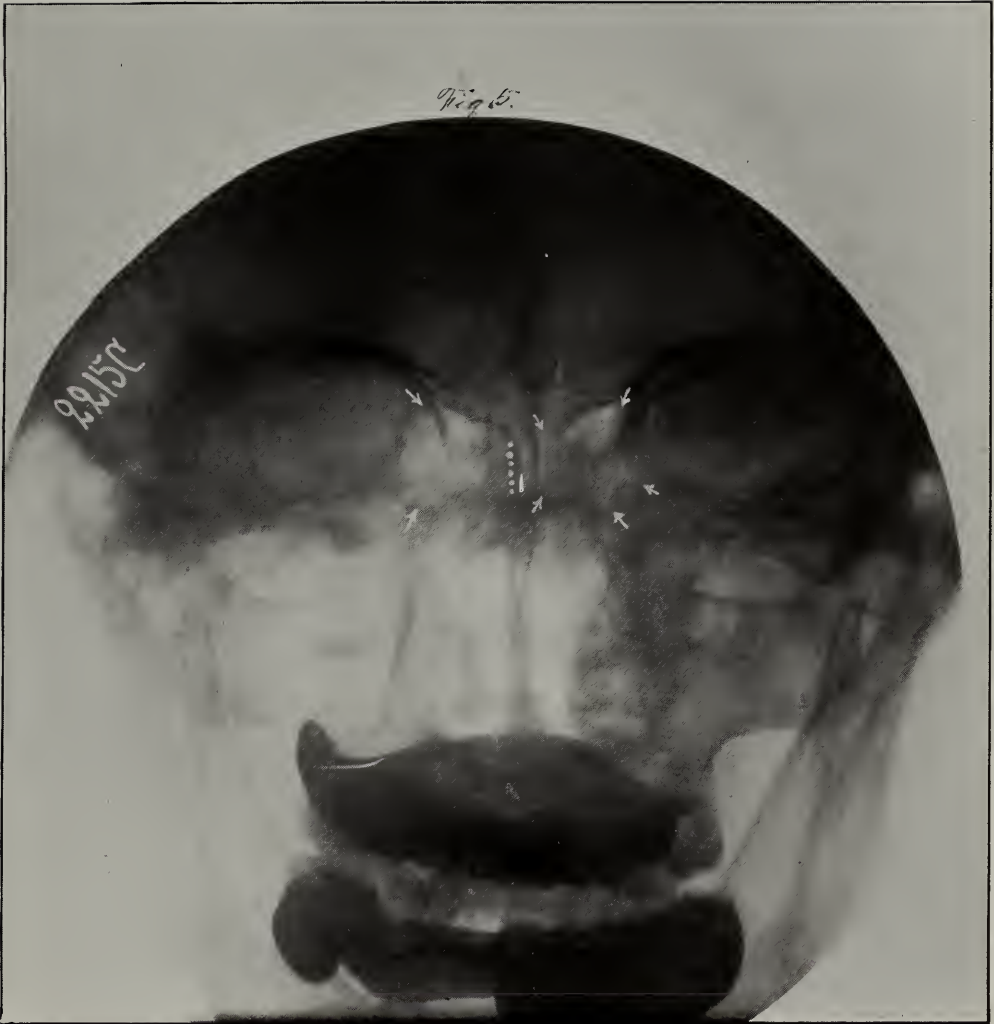

Fig. 5.—Showing postero-anterior view of same patient as Fig. 4. The left sinus is smaller than the right and shows slight amount of exudate.

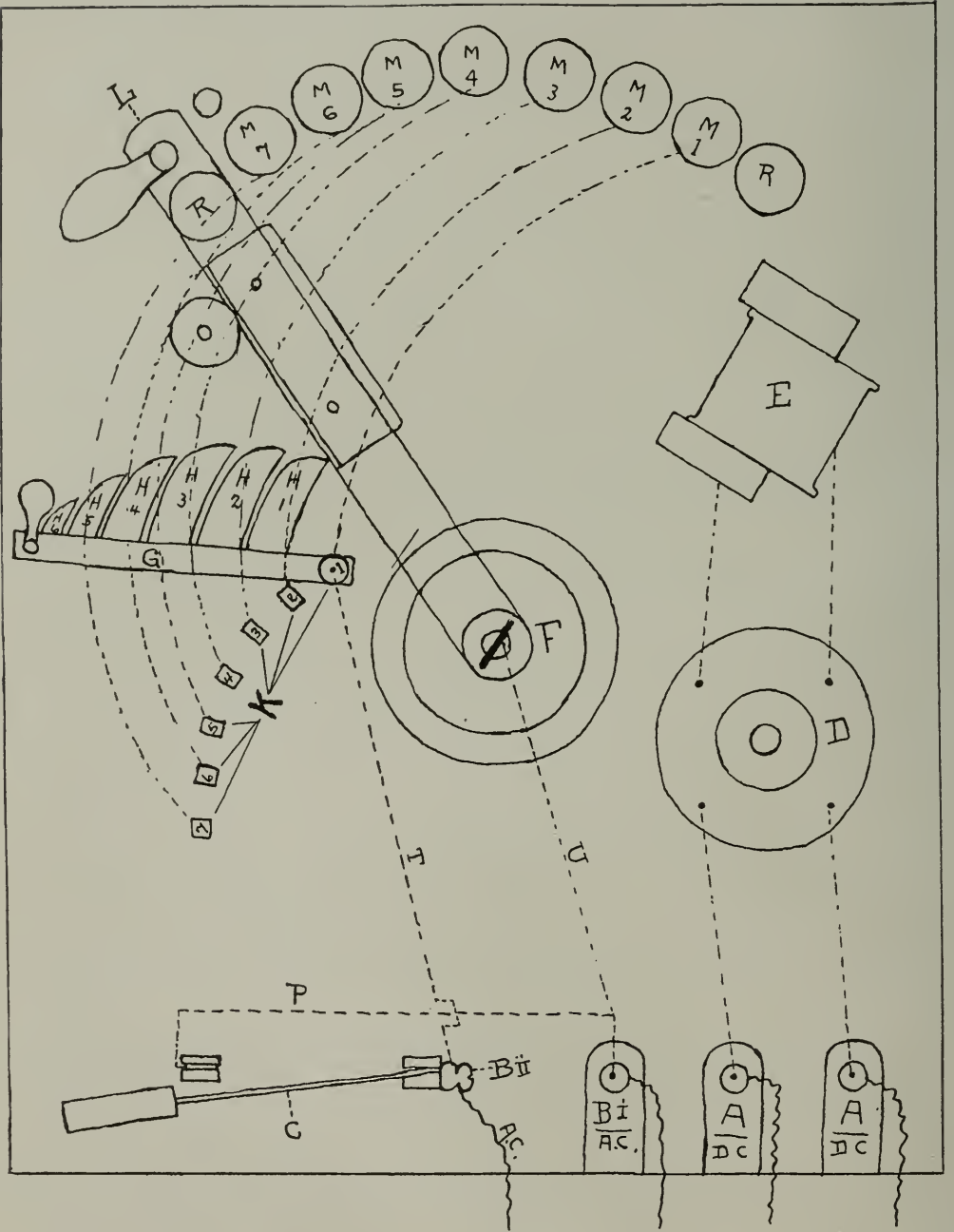




- Chiari und Marschik, Nasensarkom, Differentialdiagnose mittels Röntgenstrahlen, Annales des maladies de l'oreille, 1907.
- Ciezyński, A., Über extrakranielle Kieferaufnahmen mittels Röntgenstrahlen, Fortschritte auf dem Gebiete der Röntgenstrahlen, 1911, Heft 1, Band 18.
- Cryer, Use of the Roentgen-rays in the studies of the normal and pathological anatomy of the internal structures of the faces. Amer. Jour. of Medical Science, February, 1905.
- Destot, Röntgenbilder bei Sinusitis maxillaris, Soc. de chirurgie de Lyon, 22. März, 1906.
- Fabiunke, Beiträge zur Röntgendiagnostik der Mund und Kieferhöhle, Berliner klinische Wochenschrift, 1909, Seite 571.
- Fischer und Hald, Röntgenuntersuchung der Nasennebenhöhlen, Ref. Zentralblatt für Ohrenheilkunde, 1908.
- Goldmann und Killian, Über die Verwendung der X-Strahlen für die Bestimmung der nasalen Nebenhöhlen und ihrer Erkrankungen, Tübingen, 1907.
- Haenel, F. Osteombildung in sämtlichen Nebenhöhlen der Nase, Gesellschaft für Natur- und Heilkunde in Dresden, 20. Februar, 1904.
- Hajek, Pathologie und Therapie der entzündlichen Erkrankungen der Nebenhöhlen der Nase, 1909.
- Hirsch, O., Über Methoden der operativen Behandlung von Hypophysistumoren auf endonasalem Wege. Archiv für Laryngologie, Band 24, Heft 1.
- Jansen, Was leitet das Röntgenverfahren auf otaatrischem Gebiete für die Diagnose. Deutsche Zeitschrift für Chirurgie, 1909.
- Jungherr, Die bisherigen Leistungen der Röntgenphotographie auf dem Gebiete der Rhino-Laryngo- und Otologie. Zeitschrift für Elektrologie und Röntgenkunde, Band 9, Heft 4-7.
- Kahler, Ein überzähliger Zahn in der Nase, Wiener klinische Wochenschrift, 1905, Nr. 40.
- Killian, Die Röntgenphotographie in Dienste der Rhinologie. I. interlaryn. rhin. Kongress, Wien, 1908.
- Kirchhoff, Osteom der Stirnhöhle, Inauguraldissertation, Bonn, 1907.
- Krotoschiner, Radiogram der Nasennebenhöhlen, Brealauer chirurgische Gesellschaft 12. Juli, 1909, Ref.: Berliner klinische Wochenschrift, 1909, Seite, 1672.
- Kuttner, Die entzündlichen Nebenhöhlenerkrankungen der Nase im Röntgenbilde, 1908.
- Marschik und Schuller, Beitrag zur Röntgendiagnostik der Nebenhöhlenerkrankungen. Fortschritte auf dem Gebiete der Röntgenstrahlen Band 28, No. 4, 1912.
- Onodi, Röntgenaufnahmen der Stirnhöhlen, Verhandlungen des 1. intern Laryngologenkongress, Wien, 1909.
- Peckert, Das Antrum in Röntgenbild, Deutsche zahnärztliche Wochenschrift, 1907, No. 16.
- Perthes, Die Bedeutung der Röntgenstrahlen für die Diagnose und Operation der Stirnhöhlenosteome. Archiv für klinische Chirurgie Band 72, Heft 6.
- Peyser, Die Röntgenuntersuchung der Nasennebenhöhlen, Archiv für Laryngologie, Band 21, Heft 1.

- Pfahler, Die isolierte Aufnahme einer Oberkieferhalfte und die isolierte Aufnahme des Processus styloideus. Fortschritte auf dem Gebiete Röntgenstrahlen, Band 17, Heft 6.
- Pfeiffer, Eine neue Röntgenographische Darstellungsmethode der Keilbeinhohlen. Archiv für Laryngologie und Rhinologie, Band 23. p. 420-428, 1910.
- Philip, The X-rays in determining the limits of the frontal sinus, Jour. of Amer. Med. Assoc., 1902.
- Preisig, Spongiosierung der Stirnhohlen, Zeitschrift für Laryngologie, Rhinologie und ihre Grenzgebiete, 1910, Band 3, Heft 4.
- Reiner, In die Nasenhöhle aberrierter Zahn. Berliner laryngologische Gesellschaft, 21. Mai, 1909.
- Reynier and Glover, Radiographic researches on the topographical relations of the brain, the Frontal and Maxillary sinuses and the venous sinuses of the Dura mater to the walls of the skull. Lancet, 1900.
- Rhese, Die Diagnostik der Erkrankungen des Siebbeinlabyrinthes und der Kielbeinhohlen durch das Röntgenverfahren. Deutsche medizinische Wochenschrift, 1910.
- Rhese, Die chronischen Eutzündungen der Siebbeinzellen und der Keilbeinhohlen mit besonderer Berücksichtigung ihrer Beziehungen zur allgemeinen Medizin und ihrer Diagnostik durch das Röntgenverfahren. Archiv für Laryngologie und Rhinologie, Band 24, 1911.
- Scheier, Über die Verwertung der Röntgenstrahlen in der Rhino- und Laryngologie. Archiv für Laryngologie, Band 6.
- Scheier, Die Diagnostik der Empyeme der Nasennebenhohlen und das Röntgenverfahren. Archiv für Laryngologie und Rhinologie, 1909, Band 21, Heft 3.
- Scheier, Zur Untersuchung der Kielbeinhohlen mittels Röntgenstrahlen. Berliner klinische Wochenschrift, 1911, Seite 37. Archiv für Laryngologie und Rhinologie, Band 24, 1911.
- Spiess, Die Röntgenuntersuchung der oberen Luftwege. Atlas von Groedel, 1909.
- Underwood, An inquiry into the anatomy and pathology of the maxillary sinus. Jour. of Anatomy and physiology, 1910, Vol. XLIV.
- Uyeno, Das Osteofibrom des Oberkiefers, eine typische Geschwulst. Beiträge zur klinischen Chirurgie, Band 65, December, 1909.
- Voss, F. Das Sarcom des Keilbeines, ein typisches Geschwulst Krankheitsbild. St. Petersburger medicinische Wochenschrift, 1910. Seite 205.
- Wasserman, Die Bedeutung des Röntgenverfahrens fuer die Diagnose Siebbein- und Stirnholeneiterungen. 16. Versammlung der otologischen Gesellschaft. Bremen, 1907. Arztlicher Verein. München, 1907, 12. Juni, und Internationaler laryngologisch-rhinologischer Kongress. Wien, 1908.
- Wasserman, Die Bedeutung des Röntgenverfahrens auf dem Gebiete der Rhinologie und Laryngologie. Fortschritte auf dem Gebiete der Röntgenstrahlen, 1908.
- Wasserman, Sammelreferat. Centralblatt für Ohrenheilkunde, 1907, S. 429.
- Watsch, Stereoskopische Skiagramme der Nebenhohlen. Londoner laryngol. Gesellschaft. Jänner, 1907.

- Weil, Rontgenaufnahmen der Nebenhohlen nach Injektion von schattengebenden Massen. Wiener klinische Wochenschrift, 1903, Seite 1471 und 1904, No. 2, Seite 61.
- Weil, Rontgenbild mit dem Nachweis der Kommunikation beider Stirnhohlen. Wiener laryngologische Gesellschaft, 13. Mai, 1908. Ref. Wiener klinische Wochenschrift, 1908, Seite 1893, No. 34.
- Wiegmann, Ein Fall von Osteom des Siebbeines. Zeitschrift fur Ohrenheilkunde und Krankheiten der Luftwege, Band 62, Heft. 1.
- Winkler, Eitrige Erkrankungen der oberen nesalen Nebenraume des Gesichtsschadels. Fortschritte auf dem Gebeite der Roentgenstrahlen. Band 6, Seite 79.
- Winkler, Falle von nasalen Nebenhohlenerkrankungen. 73. Naturforscherversammlung in Hamburg, 1901.
- Winkler, Die Orientierung auf dem Rontgenbild des Gesichtsschadels und das Studium der oberen Nasennebenhohlen auf demselben. Fortschritte auf dem Gebeite der Rontgenstrahlen, Band 5, S. 147.
- Winkler, In welcher Weise kann bei eitrigem Erkrankungen der oberen Nasennebenraume des Rontgenbild des Gesichtsschadels den Operationsplan, dies Hohraume durch aussere Eingriffe freizulegen, modifizieren? Fortschritte auf dem Gebeite der Rontgenstrahlen. Band 6.
- Witt, Ausbreitung der Stirnhohlen und Siebbeinzellen uber die Orbita. Anatomische Hefte, 1908, Band 37, Abtg. 1.





## DEMONSTRATION OF AUTOMATIC SWITCH

BY LEONARD REU, M. D.,  
BUFFALO, N. Y.

Construction: The construction of most of the Switch you are all familiar with, in that the foundation is the face plate of a Cutler-Hammer starting box for a motor. The addition of a button switch, single throw single pole switch and a multiple contact switch and the necessary wiring makes an ordinary face plate into an Automatic Switch. The resistance coils in a starting box are not used. Direct current is used to operate the electro-magnet, the current can be taken from the ordinary controlling board, providing the magnet is wound for the voltage used in the machine. The button switch is in series with the electro-magnet. The single throw single pole switch is connected so that the Automatic Switch can be thrown in or out when desired. The contact buttons are connected to points on the multiple contact switch which is made up of a strip of iron having connected to it half moon shaped pieces of brass and which can be adjusted so that one or all the contact buttons can be used.

Technique: In order to operate the Switch it has to be attached in series with the current which passes through the primary of the X-ray machine. If the controlling board is so arranged that it has a pole changer, one of the wires leading to one of the terminals on the pole changer is disconnected at the terminal end. Then two wires are used, one being attached to the terminal end, the other to the wire end, and the two wires are connected to the Switch at the terminals marked B 1 and B 11. In order to operate the electro-magnet the direct current is brought to the two terminals marked A. The electro-magnet must be wound for the voltage of the current which is run into it. The purpose of the single pole single throw switch C, is to allow the use of the X-ray machine as ordinarily used and does not allow the use of the Automatic Switch. This condition is brought about when switch C is closed and the current passes in, say at terminal B 1, passing through wire P, through switch C, and out at the terminal B 11. In order to operate the automatic Switch, switch C must be left open. The

contact points M 1-7, are connected respectively to contact points K 1-7. Wire U connects terminal B 1 with terminal F at the base of the starting handle L. Wire T connects terminal B 11 with contact point K 1. The points marked R are "dead" points.

To operate the Switch, begin first by opening the switch which controls the current passing through the primary of the machine, then open switch C, bring the starting handle L across to the electro-magnet E which holds the handle on the dead point R. Then set the multiple contact switch so that only K 1 is connected. Then close the switch which controls the current to the primary and everything is ready for the exposure. In order to make the exposure press on button switch D, this breaks the current passing through the electro-magnet E and allows the starting handle L to speed across the contact points M 1-7.

The path that the current takes is as follows: Say for instance, it comes in at terminal B 1, passes through wire U to terminal F, along starting handle L which makes contact with contact point M 1, then passes through wire T to terminal B 11.

The length of exposure depends upon the number of contact points M 1-7 and K 1-7 that are connected by the half moon shaped pieces H 1-6.

I must apologize for not having taken the time to compute the speed of the switch, but so far I have found that by using the contact points M 1-7, I have been able to make exposures short enough to give sharp cut definition of pericardial structure and lung markings, using an intensifying screen. The exposure is so short that there is no screen mottling to be seen.

Uses: I have used the Switch principally in chest work, using the intensifying screen, and to a certain extent in children, using no screen. For stomach work the speed is too fast and it can be done better by hand exposure.

1104 Main St., Buffalo, N. Y.

## ROENTGENIZATION FOR NON-MALIGNANT LARYNGEAL VEGETATIONS\*

BY A. L. GRAY, M. D.  
RICHMOND, VA.

To those of us who have had the opportunity of observing an extensive throat clinic, the picture of a child lacking the cheery voice of his or her playfellows or witnessing the efforts of an infant to supply itself by gasps with enough of Nature's free air to keep it alive, is not an unfamiliar sight.

In a considerable percentage of these cases, the cause is found to be the presence in the larynx of a greater or less number of papillomatous vegetations. These growths interfere with the function of the vocal cords or even so nearly fill the lumen that, either by narrowing the passage or by a valve like action, air is prevented in large measure from passing in one or both directions. Although this distressing condition is not frequent, yet every laryngologist of an experience covering a few years is able to report one or more cases that have come under his professional observation.

For the relief of the sufferer, innumerable means have been employed. Brilliant surgery, as well as medicinal measures both constitutional and local, has been exhibited, but the results have been uniform to an astonishing degree. Whatever the method adopted for the removal of these vegetations, or however thoroughly they may have been extirpated, recurrence seems to have been inevitable in the great majority of instances, and the procedure has to be repeated at longer or shorter intervals for an indefinite period.

With these facts in the mind of the specialist, the first case that I shall report was referred and treatment was begun with the full knowledge on the part of the parents that it was purely an experiment, but based on some degree of rationality.

That the etiology of laryngeal papillomata is unknown is evidenced by the fact that almost every conceivable cause has been

---

\* A preliminary report of the cases 1 and 2 were read by invitation at a meeting of the American Laryngological, Rhinological and Otological Society, Southern Section, in Richmond February 12-13, 1909, and published in the *Annals of Otology, Rhinology and Laryngology* June, 1910.

assigned for them. It is probably this fact that is responsible for the lack of greater success in treatment.

A papilloma is defined as "a non-malignant epithelial tumor of the cutaneous or mucous surface." Microscopic examination shows it to consist of epithelial cells on a reticulum of connective tissue. The proportion of epithelial cells to the connective tissue may vary greatly so that a tumor which appears to be a true papilloma may, in fact, be more nearly a fibroma. This fact may be a determining factor in the result of the X-ray treatment.

The location of these growths in the larynx seems to be quite inconstant, though the anterior portion of the vocal cords or the anterior commissure seems to be the most frequent site. It is rare that a single tumor attains a relatively large size, but this occurs in some instances. Not infrequently multiple growths are found to involve the epiglottic and tracheal mucous membranes as well as the larynx.

Of the cases that I report, two were single; one involved the anterior portion of the right ventricle and the right vocal cord; the other involved the middle of the right cord. The others were multiple: one involved both cords and extended to the epiglottis and trachea; the other was multiple on the right cord.

Having treated four cases with uniformly favorable results, I am presenting this report, not with the claim that I have a specific, but with the hope that I may arouse sufficient interest to cause the X-rays to be tried in a considerable number of cases so that we may determine its true value and if there be virtue in the method improve the technique and render relief more speedy and certain. All four of these cases were referred by Dr. John Dunn of Richmond, Va., from his private practice.

Taking them in the order in which they were treated, I wish to report:

Case 1. S. C. White, female, age 3 years 2½ months, residing in a distant state, was referred on July 6, 1906.

Her family and personal history were excellent and presented nothing bearing upon the etiology. Three months after birth hoarseness began. This persisted in spite of all efforts to relieve her "bad cold" until the first week in July, 1905, when her respiration became so obstructed that she was brought to Richmond on July 11th. So great was her dyspnoea that a tracheotomy was performed by Dr. Dunn one hour after her arrival.



The following winter, after "a cold" she presented marked evidences of obstruction to her respiration even with the tracheotomy tube *in situ*. This continued without improvement until July, 1906, when she was brought to Richmond and received her first X-ray treatment on July 6th. As the laryngoscope showed extensive bilateral involvement, I planned giving her treatments daily on alternate sides until I should approach the reaction limit, but owing to an intercurrent intestinal disorder and exceedingly inclement weather I was prevented from the strict execution of my intention.

The treatments were given with a static machine, which was capable of passing from one-half to three-fourths of a milliamperere through the tube, which read about Walter five. The rays were directed through a lead glass shield to each lateral aspect of the throat at a point corresponding to the larynx, the child being seated in her mother's lap. Each application was of ten minutes' duration, the target of the tube being ten inches from the skin. She was given thirteen treatments within a period of twenty-five days.

In June, 1907, she again returned, this time much improved. Nine treatments were given in nine days, alternating the sides treated. On November 3, 1907, she began her third series and received eleven treatments in nineteen days. At the expiration of this series, the base of a single papilloma that had been present when the series was begun had disappeared entirely. This little tumor lay immediately behind the flange of the tracheotomy tube and was thereby in a great measure protected from the rays.

The tracheotomy tube was permanently removed by Dr. Dunn July 21, 1908. A letter from her mother, dated January 26, 1909, reported the child as "fine, can talk as loud as anyone would have her," although the tracheotomy wound was not then entirely closed. This, however, healed a short time thereafter, and the child remained in excellent health and presented no evidence of recurrence until November, 1911, when she suffered an acute infection of the tonsils and died on November 16, 1911, following an operation upon her pharynx, the nature of which I have been unable to ascertain.

Case 2. J. McL. White, male, age 6 years. Multiple papillomata of right cord. Referred on July 30, 1908. Tracheotomy had been performed by Dr. Dunn two years previously. The laryngoscope showed that the condition of his larynx was prac-

tically unchanged since the operation. Treatments were begun immediately, using an induction coil with mercury interrupter, tube reading Walter five, three-fourths to one milliamperes in the tube circuit, target fifteen inches from the skin, duration of each five minutes. Daily applications were made, alternating the sides treated. Patient received eight treatments in eight days. His parents were instructed to bring him for a second series after six weeks. Owing to illness in the family and for financial reasons the patient was kept at home in a distant city.

A letter from his physician, dated January 21, 1909, stated that "his improvement has reached a point where he can now breathe through the pharynx fairly well with the tracheotomy tube removed and the opening closed with the finger. I doubt whether it would be safe yet to leave the tube out permanently as there is still some obstruction to his respiration."

By reason of a change of residence and the obscurity of the family, I have been unable to ascertain the present condition of this case. The last report received was the publication under glaring headlines in a daily newspaper, of the wonderful cure of J. McL. effected by another physician, who had continued the X-ray treatment.

Case 3. R. P. White, male, age 10 years. Referred May 4, 1911. Hoarseness began "about Christmas," 1909. This continued and in July, 1910, a "specialist operated on him for enlarged tonsils." His condition did not improve and in December, 1910, he contracted laryngeal diphtheria, requiring intubation. The patient made an uneventful recovery except that his voice did not return. When referred to me, he had a single comparatively large papilloma, located in the center of his right cord.

Ten treatments were given in twenty-three days, the technique being the same as in case 2 except that the target was placed at ten inches instead of fifteen, and treatments were directed to the front of the larynx instead of laterally. He was instructed to return in six weeks for further treatment. A letter from his father three weeks after the end of the series stated that there was little or no improvement in his condition. I had heard nothing further from him until August 6th of this year when in reply to a letter asking for a report on his condition and for some points in his history that were not quite clear I received from his mother a letter, from which I quote as follows: "I waited for him to improve until he was taken with diphtheria

the following December \* \* \* \* and [you] are familiar with the remainder until you treated him last August.\* He began to improve after that, and gradually got better until his voice is almost, if not quite, normal. I should have taken him back to you as suggested, but my little girl had a spell of typhoid fever right about the time set for him to go, which, of course, prevented my doing so."

Case 4. F. T. White, male, age 11 years. Now under treatment. Personal and family history, good.

He has noticed a slight hoarseness for the past four or five years. Hoarseness gradually increased until one year ago his voice was entirely lost. He had consulted several physicians in his home town without receiving specific information. The correct diagnosis was first made by Dr. Thomas Edmunds of Danville, Va., who made local applications without benefit. He was sent in April of the present year to Dr. Dunn, who immediately referred him to me for X-ray treatment.

The laryngoscope showed a single relatively large papilloma emerging from the right ventricle and involving the anterior third of the right vocal cord.

The first series consisted of eleven treatments in twenty-one days. There was no material change in his voice, nor was there reduction in the size of the tumor following this series. An accident to the tube in which I placed most confidence necessitated the use of another which I considered not so well suited for this treatment, and I am sure from the subsequent course of events that the tube was largely at fault.

The patient returned in seven weeks, and the tumor was found to be slightly larger than before the first series. The second series was begun on June 19th, and nine treatments were given in seventeen days. About the middle of this series the voice began to improve, and when the boy left for his home, his phonation was practically perfect, and the tumor was found to be reduced to approximately one-third of its former size. This improved condition, however, remained only about two weeks, and when he returned to me on August 19th, phonation was about as bad as before. I have just completed his third series, and his voice has again returned. I shall not repeat his treatments for perhaps six months in order to observe the effects of the raying already done.

---

\* My records show that she is mistaken in the month.

As mentioned previously, I can easily conceive of a case in which the vegetations may appear to be simple epithelial tumors but which by reason of a great preponderance of connective tissue may resist the treatment and result in absolute failure.

In the cases first treated, there was little attention paid to the thyroid gland, but thus far no untoward results have been noticed. Where only one side is involved, the opposite lobe of the gland may be easily protected, but in the involvement of both sides, protection would be imperfect.

In case 4, which has received more raying than any of the others within the same time limits, I have been protecting the lower portion of the right and the entire left lobe.

Whether the apparent cures in the first three cases were merely instances of the spontaneous recovery that is occasionally, though rarely met with, or whether my efforts were responsible, I know not. I am, however, forced to believe that the transient improvement in case 4 has been produced by the action of the rays, and I only hope that following the last series given him the improvement may be permanent.

312 E. Franklin St.



## CIRCULATORY OPACITY

## A PRELIMINARY REPORT

BY E. H. SKINNER, M. D.,  
KANSAS CITY.

The ability to witness the circulation of the blood would offer much to physiology and diagnosis. The use of opaque media in the blood stream would be necessary. Media opaque to the X-ray at the present time consists of: 1. Bismuth salts in emulsion. 2. Silver salts in solution. 3. Iron preparation in emulsion and solution. 4. Mercury salts in emulsion and solution. 5. Lime salts in solution.

Our present knowledge permits the use of a 5% solution of colloidal silver in the blood stream for septic conditions. Citations: Plehn (Krankenhaus des Urbans. Berlin), *Deutsche med. Wochenschrift*, December 24, 1908; Seidel (Surgical Division of the Dresden Hospital), *Deut. med. Wochenschr.*, July 30, 1908; Bonneau, *Presse med.*, 1909, No. 28; Lee and Terry, *Long Island Medical Journal*, November, 1908; Parks, "Principles and Practise of Modern Surgery," (Lea Bros. & Co., Philadelphia, 1907); Dunger, *Munch. med. Wochenschr.*, Sept. 3, 1907.

The writer furnishes the preceding references to indicate that the intravenous injection of colloidal silver may be feasible and harmless.

It is a fact that a solution of colloidal silver will produce a distinct shadow upon the Roentgen negative. The applicant has demonstrated this, and the confirmation subjects the following authorities:

1. Injection of the kidney pelvices for the diagnosis of hydronephrosis by the Roentgen method. Voelker and Lichtenberg, *Munch. med. Wochenschr.*, 1909, No. 18. Von Bergmann *Mediz Klinik*, 1909, No. 11.

2. Volker und V. Lichtenberg, *Roentgenographic des Nierenbeckens nach Collargal Fullung*. *Munch. med. Wochenschr.*, 1906, No. 3. 1906, p. 105.

3. Lichtenberg und Volker. *Pyelography*. *Kongress der Rontgengesellschaft*, Berlin, April 3, 1910.

4. Haenisch, Dr. G. Fedor. Rontgendiagnostik des uropoetischen systems. 1908.

5. Braasch, W. F. Deformities of the Renal Pelvis, *Annals of Surgery*, March, 1910. Vol. LI., No. 4.

6. Uhle, Dr. A. A.; Brahler, Dr. G. E.; MacKinney, Dr. W. H.; Miller, Dr. A. G. Combined Cystoscopic and Roentgenographic Examination of Kidneys and Ureter. *Annals of Surgery*, March, 1910, Vol. LI., No. 4.

The only previous work along this line which the writer has discovered has been published by Dr. O. Franck and Dr. W. Alwens, entitled, "Kreislaufstudien am Rontgenschirm." *Munch. med. Wock.* Year 57, No. 18, May 3, 1910.

While no attempt has been made to produce X-ray negatives in the living subject by the use of the colloidal salts of silver in the blood stream, we have injected the blood vessels of an amputated arm and obtained fair views of the blood vessels and capillaries. The negatives were made with a twelve inch coil and could no doubt be wonderfully improved with a transformer and intensifying screen.

X-RAY STUDIES OF THE ILEOCECAL REGION AND  
THE APPENDIX

BY JAMES T. CASE, M. D.

Roentgenologist, Battle Creek Sanitarium-Hospital, Battle Creek,  
Michigan.

The investigation of the upper alimentary tract by means of the X-rays has engaged the attention of leading Roentgen workers ever since the advent of the bismuth meal, and the various details of the examination and the limitations of the Roentgen method in studying the pathology of the esophagus, stomach and duodenum have now received proper recognition among Roentgenologists. Much the same can be said of the X-ray examination of the colon, though the information obtainable by this method is so promisingly helpful in addition to the older methods that one is only stimulated to renewed endeavors to work out the details of technique and interpretation which are still unsatisfactory. Perhaps one of the least explored fields of gastro-intestinal Roentgenology at the present time is that centering in the ileocecal region, including the terminal ileum, the ileocecal valve, the cecum and the appendix vermiformis.

Among the earliest studies of the ileocecal region was that presented by Holz knecht in 1907 concerning the value of the Roentgen investigation of the bismuth-filled alimentary tract in the diagnosis of the ileocecal region. During the preceding year Albers-Schönberg called attention to appendical concretions as a possible source of error in the diagnosis of ureteral stone, and Fittig and Weisflog each reported a case of appendical calculus diagnosed radiographically. X-ray studies of the appendix have also been reported by Bennett (1908), Béclère, Leven and Barret (1909), Aubourg, Liertz, and Jordan (1910). Stierlin's work on the ileocecal region has been particularly helpful as has also the work of Dietlen, Kienböck and Haenisch.

One of the most important lessons taught by the careful researches of the foregoing is that the X-ray investigation of any part of the alimentary tract must include a careful study of the entire digestive system. Just as in radiography of urinary calculi, one does not feel justified in reaching conclusions with-

out having carefully searched the entire urinary tract, so also in gastro-intestinal Roentgenology one should not voice conclusions until the entire alimentary tract has been studied. The importance of the recognition of this necessity is ably demonstrated in Jordan's work on the ileum, showing the relation between intestinal stasis and various symptoms located in the stomach and duodenum. The technique which follows is only part of the routine pursued in the writer's method of examination of the gastro-intestinal tract, and no opinion is expressed on any single part of the digestive tract until after the entire examination has been carried out.

**Technique.**—As the opaque medium in intestinal work the writer has used various compounds of bismuth and lately barium sulphate. Bismuth subcarbonate was first used but later the oxychloride, as being perhaps less likely to alter the chemical reaction of the gastric contents and less likely to interfere with the influences controlling the pylorus. A number of European Roentgen workers have introduced the use of barium sulphate, not only for bowel injection but also as a substitute for bismuth in the ordinary Rieder test meal. Schwartz, of Vienna, has given the barium by mouth for over a year without any untoward effects. Koehler, of Wiesbaden, has used the barium sulphate without any untoward results; and was able to report only two cases in which the use of the barium has proved harmful. In each of these cases, a soluble salt of barium was used in place of the insoluble barium sulphate by physicians not accustomed to routine X-ray examinations. The writer has not yet succeeded in obtaining from a wholesale supply house a preparation of barium sulphate which is guaranteed safe from contamination with minute quantities of the soluble barium salts. Accordingly, bismuth oxychloride has been continued as an opaque medium for test meals but the barium sulphate now obtainable is used for the bowel injections. Barium is many times cheaper than bismuth which makes its use certainly desirable.

In studying the ileocecal region, it is important to examine *both after the ingestion and after the injection of bismuth*. The most favorable time after the bismuth meal is from the fourth to the twenty-fourth hour. In many cases, the bismuth begins to pass through the terminal ileum into the cecum by the end of four hours, and in nearly all cases, before the end of six hours.



Two ounces of bismuth added to the Rieder meal is sufficient. Jordan, of Guy's Hospital, administers four to six ounces, thereby lengthening the time required for the stomach to empty itself. No untoward effects have been observed after such a dose. The administration of the bismuth oxychloride meal is carried out in the usual manner. One may employ any of the oriental clotted milks for sale throughout the country under various names, such as Yogurt, Fermolac, Biolactyl, Lactone, Kephir, etc. These serve as better vehicles than ordinary milk or buttermilk, since they keep the bismuth in suspension for a much longer time. The clyisma consists of ninety grammes of barium sulphate in a liter and a half of warm water.\* Singer and Holzknrecht recommend the use of a potato starch preparation as being a desirable vehicle. The clyisma is employed only for studying the mobility and relations of the colon and for determining the competency or incompetency of the ileocecal valve. For a study of the motility, a test meal is preferable.

No cleansing enemas are ordered before administering the Rieder meal, but before the injection, it is important that the bowels shall have been cleaned out very thoroughly by means of proper laxatives or by thorough enemas or both. The preliminary cleansing enemas should not be large, but the patient should be asked to retain each one ten or twenty minutes before evacuating, thus better cleansing the upper colon.

The patient lying supine upon the trochoscope, the barium suspension is placed in a container about two feet above the patient and allowed to flow by gravity through an ordinary enema tube and rectal point into the bowel. The rectal point should be introduced only past the sphincter—not more than two or three inches. No attempts should be made to push the tube for a number of inches up into the bowel. It is well to attach a bulb such as accompanies a bulb syringe for added force in case the barium suspension should sediment and clog the tube. Under these conditions, the head of the barium column reaches the cecum as a rule within two or three minutes. Where hindrance is encountered, it may be necessary to force the clyisma, either by means of the bulb, or by turning the patient upon the right side, or by using manipulations combined with deep respiratory efforts on the part of the patient.

---

\*To 2½ dr. of gum tragacanth add about 1 oz. of alcohol. Shake well. Add 20 oz. of warm water and shake. Add 3 oz. of barium sulphate, then 20 oz. of water, shaking well each time. This mixture should be made up fresh shortly before using.

The use of the Haenisch trochoscope or some instrument equally good is a requirement for satisfactory bowel study. Most important of all, perhaps, is an easily adjustable diaphragm, permitting at will a large field of illumination or localizing the ray to a smaller area as in the study of some localized point of special moment. The infinitely clearer screen shadow afforded by limiting the illumination to the exact area under scrutiny, makes possible the detection of important details which might otherwise be lost. The use of a protective apron and gloves, even with the Haenisch trochoscope is a feature with which the writer has not yet felt willing to dispense in spite of the fact that many European workers continue, as they have for years, working over these different forms of apparatus without any more protection than afforded by the apparatus itself.

The writer uses a specially constructed fluorescent screen fourteen by seventeen inches square with a border about three inches wide on all sides, protected with lead. By means of proper handles, this screen can be placed over the patient in any desirable angle and with any desirable pressure. During the introduction of the barium clysma, the screen should not be allowed to rest heavily upon the patient's abdomen but should be supported by an assistant or by some suspensory device.

Before beginning fluoroscopic work, preparation of the eyes by a few minutes' stay in an obscure light or in a totally dark room is an absolute essential. Professor Bécère, of Paris, who has made precise experimental observations, states that after ten minutes in the dark, the sensibility of the retina to the light of the fluorescent screen becomes fifty to one hundred times greater than on emerging from broad daylight and after a longer interval it still increases.

A very great convenience in radiosopic work is an overhead green light connected with the foot switch attached to the coil. Whenever the tube is not in use, the overhead light is automatically turned on, but the moment the pressure of the foot turns the current through the tube, the overhead light automatically goes out. It is also convenient to graduate the intensity of the overhead light by means of an ordinary rheostat on the wall.

The great majority of our trochoscope examinations after bowel injection have been made between 10:30 and 12:00 A. M. and between 4:30 and 6:00 P. M. An effort has thus been made,

by carrying out the examination at an almost uniform time after meals, to make constant whatever influence may be exerted upon the opening or closing of the ileocecal valve by the relation of meals to the time of injection.

Everything having been made ready and the eyes thoroughly prepared, the clysma is started and its progress watched, inch by inch, as it ascends the colon. The temperature of the clysma should be one hundred degrees as being best tolerated by the patient. Should a pause be noted in the onward flow of the barium column, one first makes sure that there is not a kink in the rubber tube or a clogging of the tube. At intervals during the inflow, special points may be studied by manipulations under the screen with the protected hand or by means of a wooden spoon (Holzknecht) or by having the patient turn from one side to another. Radiograms or tracings may be made at important moments to record special phases of the situation.

In cases where the preliminary cleansing has not been complete, small collections of fecal matter may be accumulated by the stream in its progress upward and may cause the filling of the cecum to be imperfect or slowed. Careful observation will easily eliminate these sources of error.

Whenever special features are noted in a given case, it is important that the examination should be repeated at some later date—better after several days—in order to place a reliable check upon the conclusions drawn from the previous observation.

The actual exposure of the patient to the ray during fluoroscopic work is practically negligible, provided one has means at hand for immediately cutting off the current the instant it is not needed. A convenient foot switch makes this very easy. By interposing between the tube and the patient filters of aluminum or leather (Pfahler) and the canvas upon which he lies, the likelihood of a dermatitis following the examination, even when considerably prolonged, is not serious. In the writer's experience, there has not occurred a single instance of Roentgen dermatitis following radiosopic examination.

Haenisch who employs a mixture of bolus alba, bismuth and water, urges that after the examination, thorough enemas should be employed to eliminate the Fuller's earth from the bowels. In the writer's formula, in which the Fuller's earth is omitted, it is not found necessary to take special precautions to remove the barium except in cases of actual obstruction where the patient is unable to expel it spontaneously.



After studying the patient on the trochoscope, first supine, next lying on the right or on the left side, or with the hips elevated, he is then placed in a vertical fluoroscope and observation is made in the erect position. The observations upon the barium-filled colon being concluded, the patient is allowed to evacuate the clysmas, after which observations should be repeated to determine how successful the evacuation has been. Haenisch withdraws the enema instead of allowing the patient to expel it. While this is particularly helpful in the study of the lower colon, it is probably of minor value when investigating the ileocecal region.

It may be well to repeat that the barium clysmas gives valuable information regarding the size, relations and mobility of the bowel, and, when used according to the careful technique worked out by Haenisch, information concerning stenosis of the bowel or bowel motility, but in pursuing the studies of interest in this paper, the Rieder or some similar test meal is an essential. It was only after the writer began to study the bowel and especially the cecum, following the Rieder test meal that he observed that the lumen of the appendix was very frequently filled with bismuth. In the last three hundred bismuth meal examinations, I have been able to demonstrate the bismuth-filled appendix radiographically in thirty-eight cases, but I have rarely seen the appendix filled in connection with the bismuth clysmas. With the bismuth meal, the cecal shadow is more dense, more complete, and the bismuth by mouth is more convenient and less distasteful to many patients than the injection, and the determination of adhesions and points of localized tenderness about the cecum may be more easily made. On the other hand, during the barium injection, the process of filling the cecum may be watched under the screen, the competency of the ileocecal valve may be determined, the presence of filling defects is more easily made out, and the actual capacity of the colon is better determined.

**Examination of the Terminal Ileum and the Ileocecal Valve.**—In the majority of cases, bismuth does not begin to pass from the ileocecal valve until four hours from the time of ingestion. Under certain circumstances, viz: duodenal ulcer, achylia gastrica, carcinoma of the stomach producing pyloric insufficiency, and in cases of perigastric adhesions especially about the pyloric end of the stomach, the head of the bismuth column may reach as far as the middle of the descending colon



within four or five hours. Usually, however, observation four or six, twelve and twenty-four hours after the test meal will give ample information concerning the state of the terminal ileum.

The presence of stasis is easily determined at a glance at these observations. The presence of adhesions about the terminal ileum is not so easy of determination. The following maneuvers are helpful in determining the presence of ileal adhesions which produce stasis:

First.—Inspection of the ileocecal region reveals the terminal ileum distended with bismuth but separated from the cecum by a more or less constricted area of ileum.

Second.—During the movements attending deep respiration a point in the ileum may be observed which does not change its position although the adjacent bismuth-filled bowel moves up and down. It should be remembered, however, that where adhesions exist between the cecum and the terminal ileum, their presence cannot be determined in this manner.

Third.—By palpation under the screen with the protected hand or with a wooden spoon, the position of the various mobile shadows may be changed while the fixed point remains immovable. The fixed point is often the seat of pain on pressure. In determining the presence of adhesions, between the cecum and the terminal ileum in this manner, one may note whether the shadow of the tip of the cecum and of the terminal ileum may be moved independently of each other.

Fourth.—By performing the above maneuvers with the hips elevated as in Trendelenburg's position.

Fifth.—Examination with the patient lying on the left side.

Sixth.—Examination with the patient erect shows in many cases a descent of the cecum and movable ileum towards the true pelvis while the fixed point in the ileum remains only slightly or not at all changed in its position. In a certain number of cases, however, the cecum itself is also fixed so that this point of the examination often fails.

Seventh.—In a considerable number of cases the making of stereoradiographs gives additional information invaluable in confirming a diagnosis of adhesions.

The report from the attending physician or surgeon as to the presence or absence of tenderness, enlargements or adhesions of the right uterine appendages and an inquiry into the history of the patient give further necessary points of differentiation.

The ileum may be fixed at more than one point, and in a large number of cases, the fixation is attendant upon a perityphlitic inflammation which limits the possibility of determining definitely the exact location of ileal kinks.

In the study of ileal kinks, the clyisma as well as the Rieder meal is of value when the ileocecal valve is incompetent. Kraus has found in 150 autopsies after deaths from all causes, twelve cases presenting incompetency of the ileocecal valve. Out of a series of the last two hundred gastro-intestinal cases referred to the writer for Roentgen examination, thirty-three have shown the ileocecal valve incompetent as determined by the barium clyisma.

Singer and Holzknecht remark upon the relative frequency of the insufficiency of the ileocecal valve—three out of fifteen cases examined by clyisma presenting this condition. Sometimes only a few inches of ileum are filled and at other times, the clyisma may ascend many feet of the small intestine. When this has occurred, it is best to allow the patient to expel the clyisma from the colon, after which he returns to the table and detailed study of the terminal ileum is thus more satisfactorily made without the confusion of overlying shadows of the barium-filled colon. Radiographs, especially when made stereoscopically, again afford valuable information.

Ileal stasis may be observed, not only associated with ileal kinks, but in colon obstruction from any cause and is more marked the nearer one finds the obstruction to the cecum.

Sometimes the distension of the terminal ileum causes it to drag heavily upon the mesentery and in this way indirectly produces duodenal stasis and dilatation, with corresponding dilatation and stasis in the stomach. Such cases have not been at all uncommon in Jordan's wide experience. Our experience confirms Jordan's opinion that there are at least a certain number of cases in which this combination of pathological findings may exist. Comment should also be made on Bloodgood's idea that not only may the drag upon the mesentery be due to ileal stasis but it may also be due to prolapse of the right half of the colon.

In the differential Roentgen diagnosis between a true pyloric stenosis and gastrectasis dependent upon ileal stasis and drag upon the mesentery, it may be said that in the former, there will usually be some pressure pain point associated with the pyloric shadow, absence of ileal stasis and absence of distension of the

duodenum. The writer has not observed anti-peristalsis in any case of gastrectasis due to ileal stasis and mesenteric drag.

The determination of incompetency of the ileocecal valve must be of great importance. Anatomists agree that the valve is normally competent, preventing the return of gas or fluid cecal contents into the ileum. The work of Cannon, particularly as regards anti-peristalsis, makes it very probable that this view of the matter is correct. Surgical experience shows numerous confirmations of the fact that the normal ileocecal valve is thoroughly competent.

Groedel before the Eighth Congress of the German Roentgen Society, 1912, read a paper on the Pathological Changes in the Region of the Ileocecal Valve in Cases of Ileal Stasis, in which he states that with rectal injection, the contents of the bowels are frequently seen to pass upward through the ileocecal valve into the ileum and he believes that where this is well marked, the incompetency is due to chronic perityphlitis. Haenisch, Holzknicht and others have noted the comparative frequency of this incompetency.

As above noted, Kraus found the ileocecal valve incompetent in only twelve cases out of one hundred and fifty examinations. He states that the ileocecal valve in new born infants is patent, but in a child of five, it was found, postmortem, to be competent. The writer observed that the ileocecal valve of a pig and of a dog was competent, withstanding enormous distension of the colon. Kraus found that the bowels with incompetent valves showed the following particulars: First.—The colon and cecum broad (in all of them). Second.—Colon quite straightened (Straight anterior taenia). Third.—The three haustra are in apposition. In other words, in bowels with insufficient ileocecal valves, he found the same changes as in incompetency artificially produced. The writer has found that, in the main, the above holds good, but one sees frequently the valve competent with a large, widely distended cecum, and, *vice versa*, incompetency of the valve in the presence of a cecum of normal size and shape.

During the injection of the colon it will sometimes be observed that after the barium clyisma has proceeded without interruption clear to the cecum, the stream passes on through the ileocecal valve before there has been time for an accumulation of pressure through distension of the cecum. In these cases, the barium stream passes through the ileocecal valve just as the



first swallow of a bismuth-water mixture is often seen to pass through the pylorus. This observation certainly eliminates, in these cases at least, the factor of distension through overfilling as being the cause of incompetency of the ileocecal valve. In other cases, however, it is seen that the barium clyisma does not pass on into the ileum when it first is injected, nor even during the time required for close inspection of the ileocecal region, but after the patient has evacuated the clyisma and has returned to the trochoscope, it is seen that the barium has meanwhile penetrated into the ileum and that the valve has been patent, indicating some relaxing influence associated with the effort at bowel evacuation. Again in numerous cases it is observed that even though there is marked distension of the bowel the ileocecal valve remains competent. It seems, then, that there are at least three classes of cases of patency of the ileocecal valve:

First.—Incompetency of the valve associated with over distension of the walls of the cecum, which, as Kraus has so clearly pointed out, interferes with the mechanical factors connected with the closing of the valve.

Second.—In many of the instances of valve incompetency, even where the cecum is not at all enlarged and where the element of over distension has been avoided, from the history and other findings in addition to the X-ray findings it is evident that there is a peritoneal inflammatory process in the region of the ileocecal valve which exerts an influence upon the closure of the valve.

Third.—There are probably a number of physiological and pathological factors which operate to open the valve. Gruetzner has observed that when starch emulsion is injected into the bowel along with normal saline solution, starch granules can be washed out of the stomach four to six hours afterwards. Sutherland has failed to corroborate this finding in the majority of cases, although in a certain percentage, insoluble particles such as charcoal could be washed out of the stomach where charcoal was added to the nutritive enema. Examples, such as Church's, where in a case of duodenal fistula the soap and water of the enema invariably flowed through the fistula, are isolated instances and are probably pathological. Swiezenski confirms the observation of Gruetzner that substances introduced with salt solution by enema may afterwards be found in the stomach. Magnus in a paper before the twenty-ninth German Congress for Internal Medicine, makes the statement that with nutritive



enemas, there is frequently seen an opening of the ileocecal sphincter and passage of the nutritive stream into the small intestine. In the case of the bladder, according to von Zessl, the sphincter vesicae opens not only in a passive way, but also by irritation of the *nervi erigentes* even after the detrusor had been cut through. It seems probable that there are various influences which operate normally to open an intact ileocecal valve through its innervation.

The Roentgen observer frequently sees the whole of the bismuth meal accumulate in the terminal ileum up to the fifth or sixth hour after the meal, not any having passed into the cecum. The patient then takes a second meal and within one or two hours, the head of the bismuth shadow has reached the pelvic colon and the ileum is emptied. This is a frequent observation and indicates that the taking of meals operates to influence the opening or closing of the ileocecal valve. It is probable, therefore, that there may be cases of spasmodic closure of the ileocecal valve, the etiologic factors being similar to those which operate to produce spasm of the pyloric sphincter.

**Examination of the Appendix.**—It was only when the writer began to devote special attention to the ileocecal region making the examination of this part chiefly with the patient in the reclining position, that he began to expect to find the appendix shadow, and he is now able to report more than sixty cases in which the appendix has been seen and studied during the bismuth examination. Most of the Roentgen workers have, on more than one occasion, accidentally found the shadow of the appendix. The writer must say that he has seen many so-called appendix shadows which were really ileal shadows mistaken for the appendix.

Professor Rieder before the 1912 meeting of the German Congress for Internal Medicine, dismisses the Roentgen study of the appendix by the statement that it is attended by many difficulties. Desternes and Belot report a case of chronic appendicitis in which two radiographs, one with the patient standing and the other with the patient reclining, showed a displacement of the cecum by one centimeter in change of position, while the bismuth filled appendix remained at the same point, from which they conclude that in chronic appendicitis, the X-ray examination of the cecum and appendix gives valuable information concerning the presence or absence of adhesions in the region of the cecum and ascending colon. In the case reported by

Belot, there are no operative confirmations of the findings. Jordan states that he has observed some bismuth in the appendix on several occasions and he cites one case in which the whole of the appendix was very clearly shown. There was a sharp bend of the terminal portion of the appendix which remained unaltered during the few hours that the appendix was visible. In this instance, the appendix emptied itself while there was still a considerable amount of bismuth in the cecum and it did not fill again, thus demonstrating, according to Jordan, the fact of active contraction of the appendix. Jordan concludes, therefore, that the appendix is in a state of tonic contraction alternating with atonic relaxation. At the operation, the appendix was found to be firmly constricted and the end kinked sharply as shown in the skiagram. The kink was due to adhesions and was permanent. In only two or three instances has the writer been able to confirm Jordan's observation that the appendix emptied itself while there was still a considerable amount of bismuth in the cecum.

McEwen, who has made observations upon the cecum and the appendix, states that in some patients, immediately upon taking food into the stomach, there was a cecal movement commencing from below upwards as if expulsive and therefore regarded as probably due to reflex action. McEwen claims that some of these cecal movements originate in the appendix, the undulating movement running upwards from the appendix and causing contraction of the cecum.

That there is often a valve formation at the cecal orifice of the appendix is a common observation. The prominence of mucous membrane caused by an increase of the lymphoid tissue forming a small valve was first described by Gerlach in 1847. In a certain proportion of cases, moreover, the appendix enters the cecum obliquely, forming a valve in the same way that the ureter enters the bladder. The question arises as to whether or not there may be a competency or incompetency of the valve of the appendix just as there may be disturbance of the competency of the ileocecal valve.

Be that as it may, and whether or not the contents of the cecum are normally able to flow into and out of the appendix, authors agree that probably the most important factor in the etiology of the appendical inflammation is poor drainage. Hence, while there may be a doubt as to the actual pathological state of an appendix which permits the bismuth to fill its lumen, it

seems to the writer that there can be no question of the potentiality for danger where the appendix retains the bismuth shadow for many hours and sometimes even for many days after the rest of the bismuth has entirely left the colon. Therefore, the question of surgical treatment should at least be considered in every case where the appendix is visible in the X-ray examination.

Where the appendix shadow is visible a number of points may be determined, (a) by palpation under the screen, (b) by turning the patient this way and that, (c) by radiographic studies, and (d) especially by stereoscopic radiography. Adhesions between the appendix and the cecum, the length of the meso-appendix, the length of the appendix, the caliber of the lumen of the appendix and the position of the organ as related to the cecum are among the points which may sometimes be determined. Occasionally one will find a fleck of bismuth which can be freely moved about within certain limits. A number of such instances have been observed by the writer (and in a few operated upon, the observation has been confirmed) in which it seems evident that the fleck of bismuth was in the freely movable tip of the appendix.

When the bismuth shadow in the cecum is very dense, a retrocecal appendix, even though it contains bismuth, may escape observation, hence it is well to have all patients return at six hour intervals until the bismuth shadow has passed on when it may be that the appendix will still remain visible. In several cases, the writer, by watching at frequent intervals until the cecal shadow has become gray, has been able to determine the position of a retrocecal appendix, closely adherent, and sharply bent upon itself in the form of a staple. The shadow of the appendix may persist for from twenty-four to forty-eight hours to a week. In one case the appendix shadow was still visible on the tenth day after bismuth was ingested. It is a common observation to find bismuth in the appendix two and three days after the rest of the colon has been emptied.

On numerous occasions, examination has been repeated and in some cases, repeated the third time to see whether or not the appendix was again visible. On the other hand, in a number of cases, where the appendix was not visible, the examination has been repeated and most searching observation failed to find the appendix shadow.



Palpation with the wooden "palpatorium" or the gloved finger over the appendix shadow may reveal an area of severe localized pain on pressure. Sometimes the entire ileocecal region is tender but the point which coincides with the appendix is frequently by far the most tender. When the cecum and the appendix shadow is moved by manipulation, the point of localized tenderness moves correspondingly. In this palpation, one must be careful to exclude other sources of pain, such as kinking of the ileum, disease of the uterine appendages, ureteral lesions, etc.

In other cases, the appendical shadow seems to be associated with only moderate pain on pressure or perhaps no pain at all. Even in these cases, if the appendical shadow persists for a long time—for several days even after the rest of the colon shadow has disappeared—one must conclude that the appendix is a potent source of danger through its lack of proper drainage. One should not lose sight of the fact that the appendix may be only one of several manifestations of intestinal stasis, as pointed out by Lane and frequently demonstrated radiographically by Jordan.

In the differentiation between urinary stones and appendical calculus the X-ray examination of the bismuth-filled ileocecal region may be valuable, especially should it happen that the appendix is patent. The writer has had one such case in which a suspected calculus was proved to be appendical by the fact that the bismuth entered the upper part of the appendix for a part of the way, and, though the bismuth shadow in the appendix did not quite reach nor coalesce with the shadow supposed to be calculus, yet by manipulation, it was satisfactorily determined that the two shadows were both in the appendix.

Occasionally small collections of bismuth are found in the lower end of the cecum which radioscopically resemble very closely the shadow of the appendix. Careful manipulation under the screen and a radiograph may be necessary to differentiate.

Study of the cecum after appendectomy frequently gives valuable information regarding the presence or absence of adhesions and the presence or absence of cecal stasis. In the majority of instances, in which pain in the right side has persisted after appendectomy, X-ray examination has revealed more or less fixation of the cecum with a varying degree of stasis in the cecum lasting from twenty-four hours to several days after the rest of the bowel has been emptied. Many of these cases are



associated with adhesions about the terminal ileum. The cecal shadow is frequently deformed by these adhesions.

Summarizing, therefore, the writer has observed that in cases where the appendix shadow has been visible following the bismuth meal, he has always been able to show up the appendix following the second or even the third bismuth meal given after an interval of at least a few days, except where acute inflammation has intervened. The appendix has not been found after the second bismuth meal when it was not found following the first. The bismuth shadow sometimes persists in the appendix for many days after the rest of the bismuth has been evacuated. The appendix shadow is frequently coincident with the point of severe localized pain on pressure. In a fair percentage of cases, the appendix has been visible and yet not the seat of severe localized pain on pressure. Nevertheless when the bismuth shadow persists for days and for sometimes more than a week, the conclusion seems inevitable that such an appendix though not distinctly pathological, possesses a potentiality for danger through its poor drainage. Even in instances where the appendical shadow is not visible through competency of its valve—should such exist—or through obliteration of its lumen by pathological processes, palpation in connection with the Roentgen examination renders great service when appendical disease is suspected by determining definitely the outline of the cecum and permitting much more intelligent and satisfactory study of the relation of the pain point to the cecal shadow and to the shadow of the terminal ileum. Certainly the diagnosis of left sided appendicitis can be more certainly made when examination is practiced in this way.

**Tuberculosis of the Ileocecal Region.**—Ileocecal tuberculosis is a condition which in a certain number of cases can be almost surely diagnosed by the X-ray examination. Stierlin of Basle has described the Roentgen findings in ileocecal tuberculosis in seven cases. Extensive fixation or constriction of the terminal ileum with more or less fixation and deformity of the cecum and ileum, especially in connection with radioscopic signs of tuberculosis in the lungs, is very suggestive of a tuberculous process. There may be simply the appearance of distended coils of small intestine forming ropy, blotchy shadows rather than the symmetrical shadow of the terminal ileum frequently seen in the true pelvis, or there may be a palpable tumor associated with the cecal shadow in connection with the widely distended small

intestine. In the latter case, the ileum may have such a caliber as to resemble very closely the colon. According to Jordan, the occurrence of tuberculosis in the ileal region is much more common than is generally supposed. In two of our cases, the ileocecal tuberculosis seemed to have its effects in an acute purulent appendical inflammation. In both the proven cases (by operation) there have been evidences of active tuberculosis in the lungs. In at least three of Stierlin's cases there was found pulmonary tuberculosis.

**Adhesions of the Cecum and Ascending Colon.**—"Agglutinations," probably of embryonic origin, may cause close adherence of the posterior wall of the cecum. The appendix may be involved in such adhesions without having been the seat of inflammation. True adhesion bands, the result of chronic pericolicitis or other forms of inflammation, are most often found on the posterior external border of the cecum although they may involve any portion of this organ. The writer has seen one case where there existed a true veil behind which the cecum was tucked away as though in a pocket which had been made for it.

The perityphlitic adhesions which are set up by pericolicitis (Jackson) or appendicitis are frequently found to cause curious distortion of various parts of the colon. I have seen a case in which the distal loop of the sigmoid colon was adherent to the diseased appendix and the top of the sigmoid loop adherent to the gall bladder, in a case correctly diagnosed before operation. In this instance, the stereoradiographs were of the greatest importance and led to a recognition of the situation. The X-ray did not reveal the gall stones which were present. The sigmoid was retrocecal and retrocolic, measuring from ileopelvic junction to rectum, fifty-four inches by actual determination at post-mortem, the patient having died on the second day in uraemic coma associated with extensive cystic degeneration of the kidneys.

In another instance, the sigmoid loop was shown by stereoradiographs to be procolic, passing up in front of the cecum as far as the gall bladder region, adherent to both the cecum and gall bladder.

In certain other cases, the sigmoid colon occupies an anomalous position in the abdomen which, from the radiograph alone, might be suspected as being associated with adhesions.

**Cecum Mobile et Atonicum —Typhlatomy.**—This condition, which has been described by Wilms, Fischer and many others,

is easily recognizable radiologically. Associated with abnormal mobility, varying degrees of dilatation and elongation, there is stasis in the cecum long after the remainder of the colon has been emptied. There is often great tenderness elicited by palpation over the cecal shadow. This dilated, elongated cecum is not always mobile, being often associated with adhesions.

**Fistulous Tracts Associated With the Cecum.**—The injection of Beck's paste through the external orifice of fecal fistulae is also likely to give very helpful information especially when the radiosopic examination is supplemented by stereoscopic plates. Beck's paste has proved more satisfactory for the purpose than the ordinary bismuth or barium suspension in that it causes a denser shadow by its larger percentage of bismuth and it holds its form better after it has cooled. The injection should always be carefully made after Beck's technique. Following the injection of the bismuth paste, the colon may be filled in the usual manner and the relations of the fistulous tracts studied.

**Malignant Tumors of the Ileocecal Region.**—When the new growth causes stenosis of the ileocecal valve, there is naturally an ileal stasis of varying degree which in its extreme form is typical of complete ileocecal valve obstruction, the distended coils of small intestine having a caliber equal to or greater than that of the colon. In these cases, the chief characteristics are a persistent filling defect in the cecum, usually associated with a palpable tumor, the seat of pain.

Thanks are due Dr. J. H. Kellogg and Dr. R. H. Harris for permission to utilize the reports of cases referred for X-ray study and later operated on by them.

## REFERENCES.

- Aubourg. Presse medicale, 1910, No. 43.  
 Beclere. Bull. de la societe de radiologie medicale de Paris, Oct., 1909.  
 Bennett. The Lancet, 1908. Vol. 1, p. 1461.  
 Desternes and Belot. Bull. de la societe de radiologie de Paris, December, 1912.  
 Dietlen. Transactions of the Deutsche Röntgengesellschaft, 1911.  
 Fittig. Fortschr. a. d. Geb. d. Röntgenstr., Bd. XI, p. 356.  
 Haenisch. Münchener med. Wochenschr., 1911, No. 51, p. 2768.  
 Holzknacht. Wiener med. Wochenschr., 1908, No. 2, p. 102.  
 Jordan. Archives of the Roentgen Ray, 1911, No. 126, p. 295; The Practitioner, April, 1911; The Lancet, December 30, 1911; The British Medical Journal June 1, 1912.  
 Kienböck. Transactions of the Deutsche Röntgengesellschaft, 1911, Vol. VII, p. 76.  
 Köhler. Personal communication.  
 Kraus. The Lancet, Feb. 24, 1912.  
 Leven and Barret. Presse medicale, 1909, No. 96.  
 Liertz. Deutsche med. Wochenschr., 1910, No. 27, p. 1269.  
 Pfahler. Archives of Physiological Therapy, Nov., 1905.  
 Schwartz. Personal communication.  
 Singer and Holzknacht. Münch. med. Wochenschr., 1911, 48, p. 2537.  
 Stierlin. Münch. med. Wochenschr., 1911, No. 23.  
 Weisflog. Fortschr. a. d. Geb. d. Röntgenstr., Bd. X, p. 217.



## DESCRIPTION OF PLATES.

**Plate I.** FIGURE 1. The appendix is long, tortuous and not adherent, but retains the bismuth longer than 96 hours, 32 hours longer than was required for emptying the rest of the colon. There was slight sensitiveness to pressure over the appendix. Typical Lane's kink was present in this case, with adhesions about the cecum.

FIGURE 2. A long, narrow appendix, freely movable in all its parts. No adhesions nor kinking demonstrable, but severe pain on pressure limited to the appendical shadow.

FIGURE 3. A long, narrow appendix, kinked and adherent within its first inch. Retained bismuth three days after the rest of the bowel was emptied. Seat of localized pain on pressure.

FIGURE 4. Appendix long, curled upon itself, retaining the same position at all examinations. Considerable tenderness on pressure exactly coinciding with the location of the appendical shadow. The patient gave a history of several attacks within the last two years, attended by nausea and vomiting, gas in the stomach and bowels, and frequent bowel movements, with constipation in the interim. The X-ray examination showed the stomach to be radiologically normal.

**Plate II.** FIGURE 5. The appendix shadow does not represent the entire appendix, the distal portion having been obliterated. The proximal half which shows was adherent both to the cecum and to the ileum, and the cecum itself was bound down by adhesions. There was stasis of bismuth in the cecum and the appendix long after the rest of the colon was emptied. The patient gave a history of repeated attacks which had been diagnosed as recurrent appendicitis.

FIGURE 6. Appendix shown retrocecal, bent upon itself and adherent. The appendix shadow corresponds exactly with the spot at which the patient always complained of pain on pressure and described by the patient as "the" spot. Careful examination was made in this case during the appendix operation but no other abnormalities could be discovered. No ileal adhesions were found in this case.

FIGURE 7. Appendix kinked and adherent in its mal-position. No localized pain on pressure. The appendix retained the bismuth only one day.

FIGURE 8. This appendix was retrocecal, adherent and its shadow corresponded exactly with the patient's pain point.

**Plate III.** FIGURE 9. This appendix is characteristic of a type which the writer considers dangerous, having a lumen wide in its distal portion, but much narrowed near its cecal end. Although the rest of the bowel emptied completely in 53 hours, the appendix was still filled with bismuth. The appendical shadow coincided exactly with an exceedingly tender spot.

FIGURE 10. Another appendix of the class mentioned under Figure 9, dilated in its distal portion, and constricted in its proximal third. Certainly an appendix potent for danger, although up to the present time nothing in the history suggests appendical disease. In this case there was only moderate tenderness on pressure over the appendical shadow. The bismuth meal was repeated on two succeeding occasions and the shadow was seen at all examinations.



FIGURE 11. Appendix shadow seen behind the outer, lower border of the cecal shadow. The appendix was fixed in its bent position, retaining the same shape at all times, adherent to the cecum, but freely movable with the cecum. Although the rest of the colon was empty at the end of 46 hours, the appendix shadow persisted.

FIGURE 12. Appendix shown in Figure 11 after the rest of the bowel had been emptied. This patient had, for years, been subject to aching pains in the lower right abdomen, complicated with three attacks of pneumonia and lung abscess three years before. Prominent internists diagnosed his case as neurasthenia.

**Plate IV.** Stereoradiogram of the pelvis showing the pelvic colon, the cecum and a fistulous tract between the lower angle of an old appendicectomy wound and the sigmoid. The fistula was filled with Beck's paste, considerable of which passed into the sigmoid (note the denser shadow). The colon was then injected in the usual manner. The patient had an appendicectomy some years before followed by long suppuration and the formation of a fistula. Note the ease with which the fistulous tract can be followed from the skin to the bowel. Observe the subcutaneous blind pouch branching off toward the suprapubic region.

**Plate V.** Stereoradiogram showing stomach, colon and terminal ileum in a case of ileal adhesions. Note the dilated ileum reaching up out of the pelvis with the constricted three or four inches of terminal ileum separating the dilated ileum from the cecum.

**Plate VI.** FIGURE 15. Typical Lane's kink of the ileum associated with ileal stasis. The hiatus between the shadow of the dilated ileum and the cecum represents the portion of the ileum which was bound down by fibrous bands.

FIGURE 16. Typical kinking of the terminal ileum about an inch and a half from the ileocecal valve, associated with ileal stasis.

FIGURE 17. Distortion of the terminal ileum associated with adhesions, ileal stasis, and fixation of the cecum.

FIGURE 18. Another case of Lane's kink of the terminal ileum showing ileal stasis.

**Plate VII.** FIGURE 19. Very much dilated, elongated cecum, freely movable and the seat of stasis. Colon filled by injection.

FIGURE 20. Cecum elongated, freely movable and atonic. Bismuth ingested.

FIGURE 21. Case of incompetency of the ileocecal valve which permits the bismuth enema to pass through the ileocecal valve, filling many feet of the small intestine. This condition was found on repeated examinations.

FIGURE 22. Elongated, dilated cecum, with fixation and kinking of the terminal ileum following pelvic peritonitis.



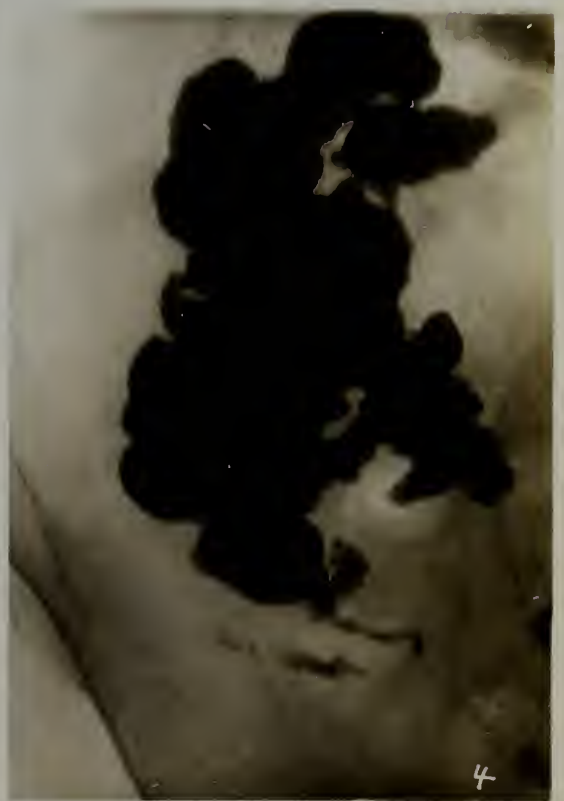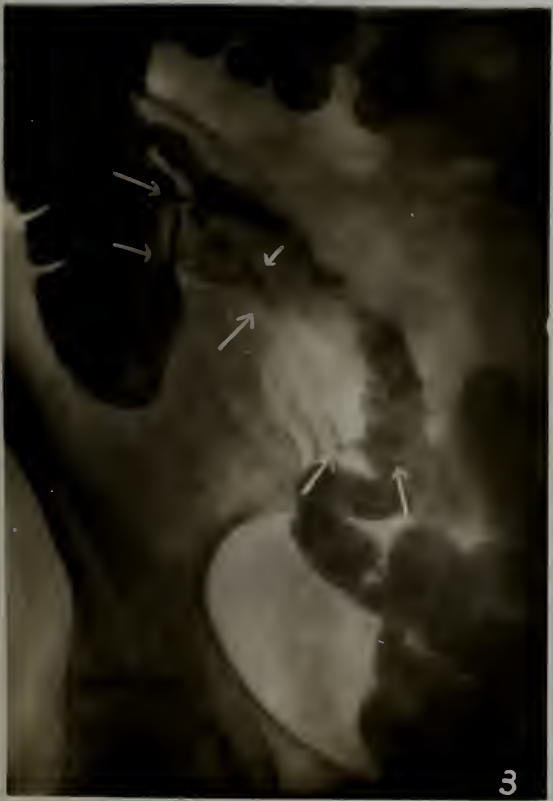

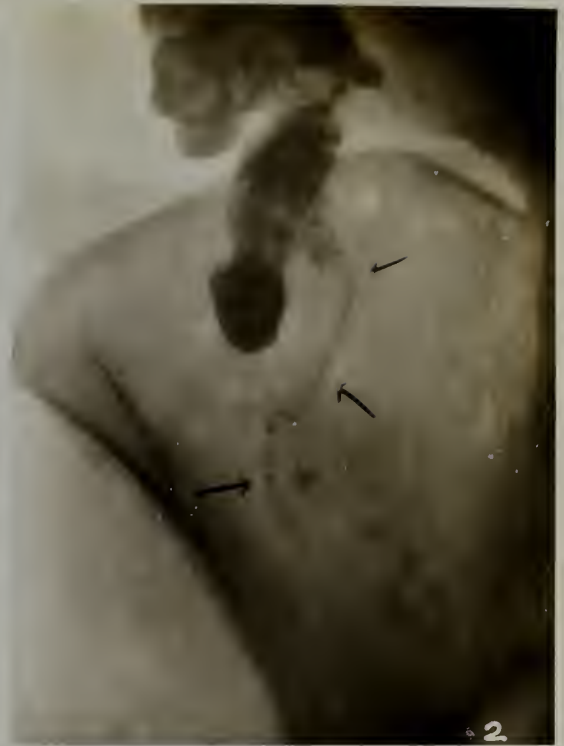
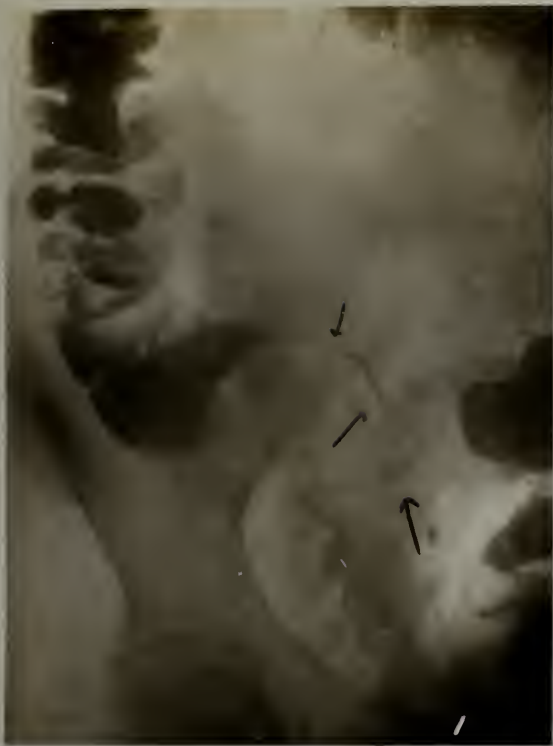PLATE I.

FIGURE 1  
FIGURE 3

FIGURE 2  
FIGURE 4







PLATE III.

FIGURE 9  
FIGURE 11

FIGURE 10  
FIGURE 12



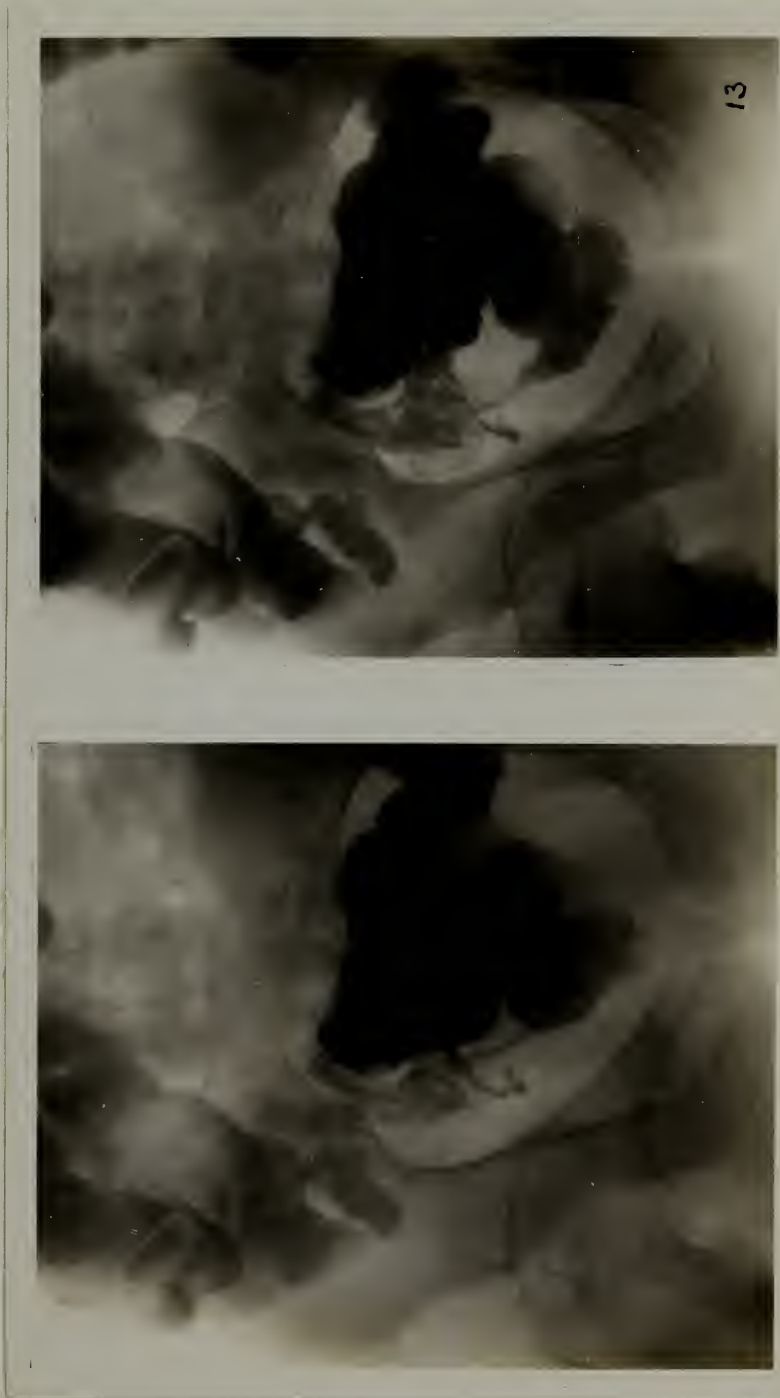


PLATE IV.





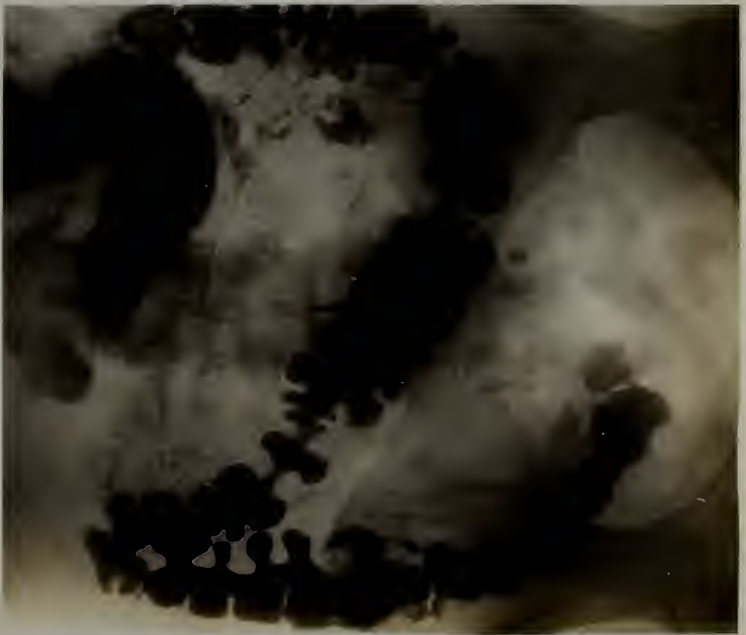
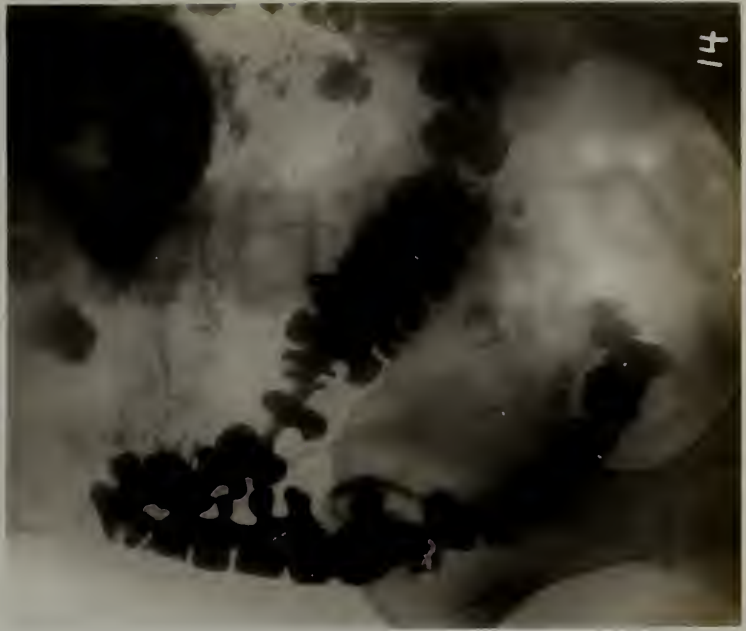

PLATE V.



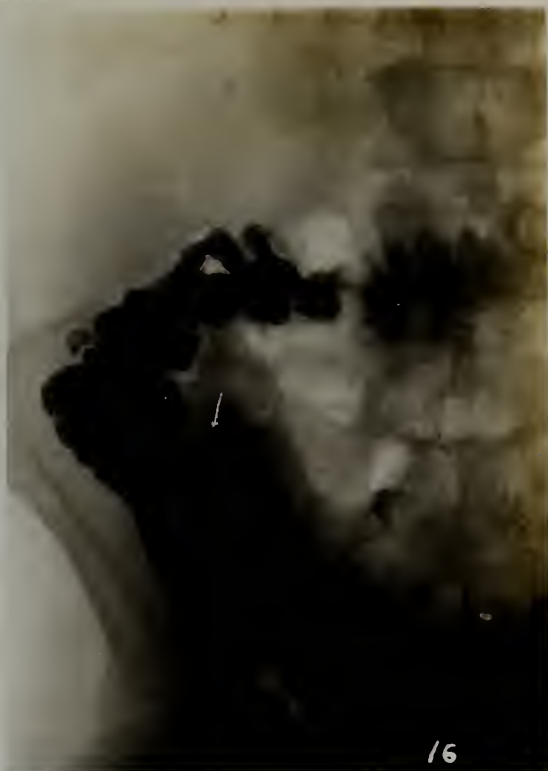
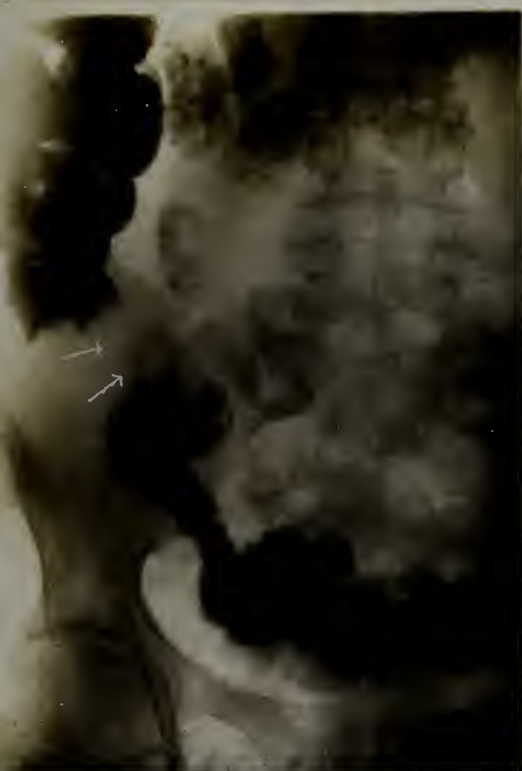
FIGURE 15  
FIGURE 17

FIGURE 16  
FIGURE 18





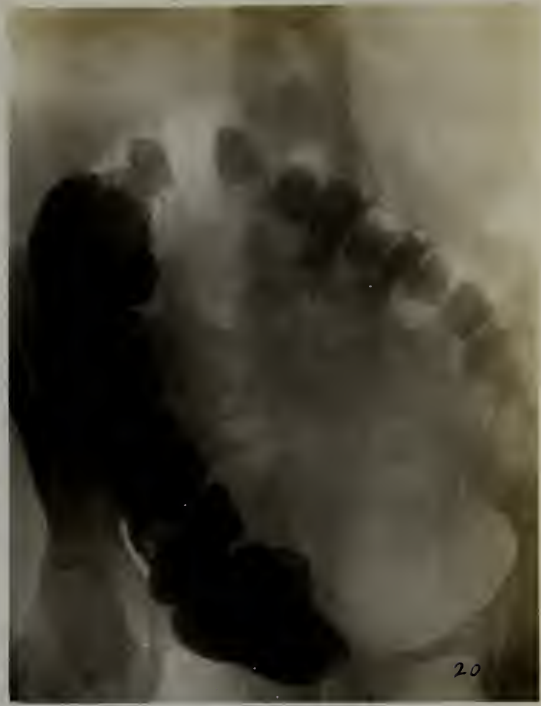

PLATE VII.

FIGURE 19  
FIGURE 21

FIGURE 20  
FIGURE 22

## EDITORIAL

Following the suggestion of the retiring secretary, Dr. Pancoast, a motion was introduced by the executive committee calling for the appointment of a committee on nomenclature. After the resolution was carried the president appointed the following committee: Dr. Zapffe, Dr. David R. Bowen and Dr. Percy Brown. This committee certainly has an important task to perform and its deliberations will be looked forward to with interest. The report of the committee will probably appear in some future number of the *QUARTERLY*. At present a confusion exists among writers on Roentgenologic subjects in their choice of terms for the products of their work and the means with which they work. As was pointed out by Dr. Zapffe this leads to great confusion. The compilers of the various indices of medical literature have great difficulty in classifying the subjects inasmuch as so much confusion exists in the titles of papers. If this committee which has been appointed suggest a nomenclature which meets the formal approval of the society it will certainly tend to obviate much confusion. As our society is the recognized leader in Roentgenology in this country, its attitude would probably be recognized as authoritative by medical journals and their compilers.

Another important committee appointed was the one upon the beginning of an international work upon standards. As appointed by the president this committee was not designed to carry out the experimentation themselves, but rather to interest physicists and laboratory workers and also to secure the cooperation of various other societies of kindred aims, so that an international movement might be started which would be productive of a good work. At present the absence of standards of radiant force is one of the deepest felt wants of the Roentgen worker. The committee would certainly welcome suggestions from the members of the society as to the beginning of this most important work.

## CURRENT LITERATURE.

**The Roentgen-Ray Diagnosis of Intraabdominal Neoplasms by Means of the Displacement of the Large Intestine.**

(*Die Röntgendiagnose intraabdominaler Neubildungen aus der Verlagerung des Dickdarms*)

EDOUARD STIERLIN, Basle.

*Deutsch Medizinische Wochenschrift, August 1, 1912.*

Stierlin advocates studying abdominal tumors by means of the X-ray after having filled the colon with bismuth (per os or per rectum). He believes that tumors of various organs and regions have characteristic influence on the colon, displacing it in definite directions, so that the location of the tumor is possible. His article is illustrated with a number of interesting diagrams. He draws the following conclusions: The diagnosis of intra-abdominal tumors (new growths and abscesses) can be definitely located by means of displacements they cause in the large gut, as shown by means of the X-ray. Psoas and iliacus abscesses appear to cause a characteristic displacement of the ascending colon toward the mid-line. In right-sided pelvic tumors the cecum is lifted upward and toward the mid-line. The typical mesial displacement of the colon in tumors of the kidney is shown much more clearly by this method than by the customary method of colonic inflation.

**A Step in Roentgen Technic.**

At the last Roentgen Congress in Berlin Dr. Christen of Berne demonstrated an instrument which he had devised to measure the action of the Roentgen rays on deep-seated organs. The instrument gives direct readings of the intensity of irradiation at the depth required, and can be used with any type of Roentgenograph. Dr. Christen uses as the standard of measurement the thickness of a layer of tissue which will absorb precisely one-half of the incident beam, whilst permitting the other half to pass through, i. e., that thickness which will reduce the Roentgen ray beam to half value. The thicker this so-called "half value layer" the more penetrating or "harder" is the radiation. The introduction of this absolute scale of measurement in lieu of the various arbitrary scales used in different Roentgen laboratories is a great advance in Roentgen technique, and its author has laid down laws by which to calculate the most efficient irra-

diation for deep-seated tissues and to determine the correct dose for subcutaneous organs with accuracy. Hitherto this has only been possible when surface tissues have been in question.

The apparatus is made by Messrs. Reiniger, Gebbert, and Schall of Erlangen.

#### **Injurious Effects of Roentgen Irradiation.**

A. RAVOGLI.

*Jour. A. M. A., August 24, 1912.*

The author is decidedly of the opinion that roentgenotherapy is accompanied with more or less danger. This statement is not made for the purpose of discouraging anybody from the use of so powerful a physical remedy, which can bring about a great deal of benefit in a great many diseases, but only to call the attention to the great care which has to be used in giving the X-ray. In some cases the patients have been trusted to inexperienced office attendants, and the physician has noticed the danger only when dermatitis had already set in. When with the X-ray no improvement or no progress is obtained in the treatment of a disease, it is better to stop and change to some other method of treatment; otherwise danger is lurking and will soon be looming up.

When a radiodermatitis has begun, if it is of first degree, a bathing with 2 per cent. solution of aluminum subacetate or of sodium bicarbonate will diminish the itching and the burning sensation, and the skin in a short time will return to the normal condition. If the burn is of second degree with formation of blisters, the continuous bathing with soothing solutions, the opening of the blisters and the treatment as for any other burn will be sufficient. When ulceration sets in recovery is difficult. The best way for a speedy recovery is the excision of the whole ulcerated surface, and consequent surgical treatment.

#### **Comparative Value of Physical Signs and the Roentgen-Ray in Determining Chest Conditions.**

E. A. MILLER AND A. J. QUIMBY.

*New York Med. Jour., August 10, 1912.*

The authors' use of the fluoroscope as an independent means of diagnosis leads them to consider it of great value in estimating the amount of infiltration or fibrosis and determining the excursion of the diaphragm, but as generally used little else is learned that could not be determined by the physical signs, if one has a trained ear and makes a careful examination. However, where good apparatus and proper facilities are provided,



one may acquire experience in its use which greatly facilitates the location of gross lesions for further detailed study. In this series Miller made a careful physical examination in fifty cases, and together both authors studied the skiagraphs and laboratory reports, prepared independently by Quimby, and observed that in the cases diagnosticable by physical signs their findings agreed quite accurately, whereas in a few cases that could not be determined by physical signs, the skiagraphs showed small lesions or enlarged or calcified tuberculous glands at the root of the lung, which explained the physical condition of the patient. As the reports from the clinician and the Roentgen laboratory were almost identical in thirty-two of these, they refer briefly to fourteen cases in which there was some variation.

One case in which a cavity had been diagnosticated, the roentgenogram showed it to be a double cavity, that is, two cavities closely adjoining. In three cases the roentgenogram showed calcified glands not diagnosticable by physical signs. In one case the roentgenogram determined the size and position of the heart caused by several lesions which was a puzzle on physical examination. In two cases the roentgenogram and physical examination wholly disagreed. In one the examination gave flat percussion note with small mucous rales at left apex and left base, but not bronchophony in either locality. The case is an old one, the patient has never shown tubercle bacilli in sputum and has been improving since the discontinuance of injections of tuberculin which had been persisted in for some time, the patient desiring it and the physician in attendance thinking it benefited her. The roentgenogram showed old, extensive, fibrinous bronchitis. In the other case the chart was not made by Miller, and from what he remembers of the case, he is inclined to believe the roentgenographic result, as this patient had a lung capacity of 150 cubic inches and readily increased it to 184. The normal for her height would be about 158, therefore she could not have very much lung involvement with such a lung capacity and no physical signs to account for it. This patient is now practically well, as she had an arrested case some months ago, the roentgenogram showed infiltration of left apex and the physical examiner reported much involvement.

Another case in which the roentgenogram gave findings of fibrous deposit at both apices with bronchitis, the clinical report gave consolidation of left apex and sonorous rales over the left chest; roentgenogram and physical test agreeing on bronchitis.

The examination of sputum was negative in the case. Two cases showed cloudiness of right apex not found on physical examination. One case in which physical test indicated cavitation, Dr. N. N. Stark and Dr. Miller agreed on the findings; whereas the roentgenogram indicated normal lung tissue, surrounded by sclerotic solid lung tissue. One case not tuberculous, in a girl of thirteen years, where the roentgenogram showed a cicatrix, drawing the vessels and heart toward the right side. In another case the roentgenogram showed involvement near the left apex, and physical signs showed involvement of both apices and bases.

The authors offer the following additional suggestions as to the interpretation of thoracic skiagraphs, based on these observations:

In studying any roentgenograph one should bear in mind the two factors of atomic weight and molecular density, as well as the thickness, and the distance of each part from the sensitive plate while the exposure was being made. For example, loose, areolar, and adipose tissue, which contain large proportions of water and hydrocarbons, cast only a moderate shadow, but interfere with fine detail by removing other structures a greater distance from the plate, while the heavy muscles of a workingman, which contain concentrated proteids, cast a shadow much denser than those of a flabby individual, though their apparent bulk may be the same.

In incipient cases of tuberculosis, we notice diffuse congestion around the pulmonary tree, small groups of occluded alveoli in the area of origin or small infiltrated glands, calcification of costal cartilages, and Williams's sign. Again, in old arrested cases, an area of congestion around the hilum, shading off rapidly, usually indicates an exacerbation of an arrested case, while physical examination will frequently reveal only the rales, generally attributed to bronchitis. In a case undergoing resolution this area of congestion presents a more clearly defined border, and if observed at intervals may be seen to gradually retreat toward the hilum.

The mineral salts as found in bone and calcareous deposits, give a very dense shadow with clearly defined outlines, in marked contrast with the soft tissue. Thus, when bronchial glands are in the inflammatory stage, they present a fairly dense shadow of oval or rounded form. When an irregularity is noticed in part of the outline with cloudiness in the adjacent lung shadow it is

believed to be due to a destructive process, while a calcified gland will cast a sharply defined shadow as dense as that of bone. Enlarged pulmonary glands, as observed in the skiagraph, should not be considered indicative solely of tuberculosis as they are noted in leuchemia, malignancy, syphilis, and inflammatory conditions. Boggs states that in his radiographs of a series of cases following operations for cancer of the breast, the bronchial glands were enlarged and showed quite plainly on the plate, but less distinctly than tuberculous glands. In our own cases of primary and secondary carcinoma the same was true and the mottled appearance of the lung tissue characteristic of tuberculosis was absent.

The radiographic picture of pneumonia changes rapidly with the development of the disease. The unresolved cases are occasionally met with and present a peculiar mottled appearance, which we can best compare to the shadow cast on the ground by the sun shining through the leaves of a small bush.

The fibrous tissue and exudates which are found in a thickened pleura might pass unnoticed were it not for their very irregular outline, great variations in density, and the fact that they generally limit the movement of the overlying ribs.

Such conditions as pneumohydrothorax or pyothorax and collapsed lung are usually so sharply outlined that they would be readily diagnosticated by a novice, as even a moderate amount of fluid casts a shadow of such great density that other outlines are obliterated, while air casts no perceptible shadow, thus making a marked contrast with the spongy lung tissue and also permitting greater detail in the image of the chest wall where lung tissue is absent.

In each of these conditions the displacement of the heart and great vessels and compensatory emphysema will be noted to correspond quite accurately with the extent of the process. The collapsed lung tissue itself presents a shadow of very different character from the normal, being hazy and much denser with a sharply defined border.

In emphysema the area of the lung is increased and the shadow is much lighter, while a downward displacement of the diaphragm on the affected side may be noted if the process is extensive.

The authors regularly make two exposures of the thorax, one in the supine and the other in the prone position with the patient lying flat on the plate holder in each case. By a comparison of



these, one readily determines whether a lesion is nearer the anterior or posterior chest wall.

When superimposed shadows of doubtful significance are present, it is often possible to show their extent and nature by a stereographic pair.

They prefer, however, to study doubtful areas separately, and by arranging conditions for the shortest possible exposure have had no difficulty in showing plainly the difference in appearance between the walls of cavities and various forms of dilated bronchi. They find this method advisable also where physical signs are negative, but the skiagraph of the entire chest shows a slight cloudiness in some part.

They have found the skiagraphs especially interesting in cases in which small areas of deep seated consolidation were plainly visible, but as they were overlaid by emphysematous lung, they gave normal resonance and no rales; also in cases in which pleural adhesions or consolidated lung tissue almost surrounded the distended areas, giving a strong suspicion of cavity on percussion. In studying the shadows of the mediastinum they notice that the heart is slightly displaced in a very large proportion of tuberculous patients, that the right auricle is hypertrophied or dilated in almost all advanced cases, also that the position of the arch of the aorta varies so greatly as frequently to arouse suspicion of an aneurysm.

The enlarged mediastinal glands occur with great frequency and occasionally cause displacement of the large vessels or esophagus, which cause confusing shadows.

#### **Roentgen-Ray Study of Gastrointestinal Findings in Multiple Arthritis.**

G. R. ELLIOTT, NEW YORK.

*Am. Jour. of Orth. Surg., August, 1912.*

The object of this study is to present as far as possible Roentgen ray findings of the gastrointestinal tract in patients afflicted with multiple arthritis, to see how far these patients deviate from the normal in a gastrointestinal sense, and if possible to correlate these findings with other findings to aid us in clearing up the difficult problem.

The present series comprises the examination of nine walking patients. No claim is made of expecting by such an examination to establish in any way the primary etiology of the disease in question.

On the contrary Elliott feels very certain that we shall not



find it in this way. But have we here complicating factors bearing on the disease, and how do these factors influence its course? This study was made at the Montefiore Home, and the roentgenograms have been prepared by Dr. Charles Gottlieb. Both bismuth and barium were used. One and one-half ounces of bismuth was given with 8 ounces of zoolak or koumiss. For the enemas a like quantity with acacia and thirty ounces of warm water.

An analysis of the series strikes us at once with the variance from what is now regarded as normal. Eight of the nine cases show some abnormality when compared with our previous conception of the time that the food remains in the intestine, and with the normal anatomic position of the abdominal organs. Four show ptosis of the stomach with delay. Four show ptosis of the transverse colon. Five show delay in cecum and transverse colon—the shortest thirty-six hours, the longest fifty-five hours. At forty-nine hours in one patient the colon was still packed. One shows constricted colon. One shows marked delay in the small intestines. One has a markedly enlarged atonic stomach. Three show enlarged spleen. Several of these patients show two or more of these abnormalities combined.

Here then are findings which Elliott believes should be considered in making a clinical study of patients, findings that we are not justified in ignoring. How far do findings referred to act as a causative factor in producing multiple arthritis or influence its clinical course? Elliott believes that many of these conditions have been acquired since the onset of the arthritic malady.

The stooping attitude of some of the patients under consideration doubtless explained the ptosis of the stomach and transverse colon.

One patient, however, presents this abnormality, yet stands quite erect, and one appears to have the congenitally placed stomach. The delay and sluggish intestinal action too may result from a low grade of intestinal musculature and diminish intra-abdominal pressure. Four of the five patients showing delay have a lax abdominal wall giving a low intra-abdominal pressure. The dilated stomach was gradually acquired. Elliott is convinced that the primary cause is some real infection which does its work rather quickly, intermittently when the focus of infection is not wiped out. After the damage is once started, then acquired conditions irritate the already weakened parts and

a vicious circle is established. The chief contributory feeder, he feels, lies somewhere in the gastrointestinal tract. The article is illustrated.

**Action of Radium and Roentgen-Rays on Malignant Growths.**

E. H. SHAW.

*Bri. Med. Jour. August 18, 1912.*

In a case of carcinoma of the breast of an aged woman a recurrence was treated first with Roentgen rays and afterwards with radium. The tumor and glands were reduced very much in size. The patient died suddenly from some other lesion, and material was obtained *post mortem* for histologic investigation. Microscopic sections of the remains of the tumor showed a small spheroidal-celled carcinoma with a well-formed fibrous matrix; the cells stained well, and were seen running in narrow columns from the main mass into the surrounding fatty tissue. Another section showed fibrous tissue free from growth, which looked as if all the cells had been destroyed and replaced by fibrous tissue. A lymphatic gland showed growth with a very scanty amount of fibrous tissue, while a nodule in the liver showed cellular growth with partial necrosis. The nodule of growth which was exposed to the action of the rays was very fibrous, while the other deposits which were further away were poorly supplied with this tissue. Also the nodule in the liver, which was at some distance from the rays, contained a necrotic patch. In another case of recurrent carcinoma numerous nodules appeared in the skin about the scar shortly after an amputation of the breast. The woman was only thirty-two years of age, and, owing to the rapidity of recurrence and extent of the disease, no further operation was attempted. Roentgen rays were applied and the nodules of growth decreased in size in a remarkable manner, but they afterwards grew larger again. At the same time other nodules appeared, and a large area ultimately became affected. Certain nodules were localized and at varying periods removed in order to ascertain what changes were taking place as a result of the application of the Roentgen rays. Microscopically the primary growth was a spheroidal-celled carcinoma with much fibrous tissue. The nodules showed exactly the same type of growth, the malignant cells were small and round, and lay in small groups in a dense network of fibrous tissue. They were well stained, and extended right into the papillae. No necrotic cells were to be seen. Numerous small round inflammatory cells lay among the cancer cells.

A man, aged fifty years, had a large mass of growth in the neck. Part of it was removed together with a piece of the internal jugular vein. It proved to be a small round-celled sarcoma. The treatment by Roentgen rays was followed by a temporary decrease in size of the main mass, but the patient ultimately died with large masses of growth in the neck and thorax. Microscopic sections of various parts of the growth showed round-celled sarcoma with very little fibrous change. A hard gland in the neck, which had been exposed to the action of the Roentgen rays, showed increase of fibrous tissue and necrosis of the central part of the growth. The peripheral cells stained quite well.

In a case of carcinoma of the breast of a woman aged sixty years, Roentgen rays were first applied with the object of softening and breaking down the tumor, and this was followed by the application of radium. The growth was hard and fixed to the skin and nipple. Under treatment it gradually became smaller, and ultimately disappeared. A small nodule was removed from the skin over the tumor toward the end of the treatment and microscopic sections prepared. They showed a large-celled carcinoma in small amount, the cells stained well in some groups and badly in others, while other groups were represented by a granular necrotic mass. Fibrous tissue was abundant, some of it being "hyaline" in character. Small round inflammatory cells were distributed throughout the tumor. The squamous epithelium on the surface stained well in all parts.

Shaw believes that malignant tumors undoubtedly diminish in size under the action of Roentgen rays and radium, but so they do without this treatment—in a small number of cases certainly, but they do. But the proportion of tumors which diminish under treatment is much greater than the proportion which do not. And then there is the fact that some growths actually disappear. This is a great encouragement to persevere in the use of Roentgen rays and radium.

#### **Causes of Failure of Roentgenization in Deep-Seated Cancer.**

F. HERNAMAN-JOHNSON.

*Bri. Med. Jour.*, August 18, 1912.

Hernaman-Johnson believes that Roentgen rays depress cancer cells because they have become embryonic in type, for the cells of any given tumor there exists a critical dosage of Roentgen rays from which they are unable to recover. This dosage will vary according to the mitotic index of the growth con-



cerned. The mitotic index, again, will differ in various tumors, even such as closely resemble each other from a clinical standpoint, and will not remain a constant even for the same tumor.

The amount need not necessarily be all delivered at one sitting. The determination of the number, strength, and frequency of irradiations is seen to be a matter of the utmost importance; for a dosage below that which is critical for the cells of a given tumor will never kill these cells, no matter if it be administered for months or even years.

To treat a rodent ulcer with unfiltered rays from a medium tube is to invite failure, for the surface receives a bombardment wholly disproportionate to that sustained by the deeper layers. Not only are numerous soft rays emitted from the anticathode, but a vast number of *adventitious primaries* are given off as a result of electrons striking on the glass of the bulb. All these are highly active physiologically within narrow limits, and as a consequence the ulcer heals rapidly on the surface. Cessation of treatment will almost certainly be followed by relapse, while persistence will result in surface irritation.

No case of rodent ulcer should relapse because the deeper layers have received a relatively feeble dose of rays. Bulbs can be obtained whose radiation, after being filtered through 2 mm. of aluminium, will penetrate at least 3 to 4 cm. of tissue before falling to half value, and they can be excited by any good modern coil worked from the main. The fall in value at a depth of 1 cm. is so trifling that it may be disregarded. It may be objected that these very hard rays are lacking in therapeutic value. But Finzi and others have proved that this is by no means the case, and Hernaman-Johnson has himself brought about the healing of a patch of psoriasis after having passed such filtered rays through 2 cm. of water, at the same time carefully excluding all possibility of secondary ray effects. One must remember that the blood contains an appreciable amount of iron, the secondary radiation of which is highly active at short ranges. The trouble with very penetrating rays is not so much that they are inactive therapeutically as that a large proportion of their energy passes right through the lesion and is lost. By applying the principles of secondary ray therapy, this waste energy may be trapped and made to do work where it is most needed. For the past year Hernaman-Johnson has employed in the treatment of rodent ulcer hard filtered rays intensified by the specific secondary radiation from silver or zinc.



and is well pleased with the results so far; but it is as yet much too early to form any conclusion as to whether this modified technique materially reduces the tendency to relapse.

In treating rodent ulcers we can look out for and deal with small relapses, and there is little likelihood of dissemination. But in cancers of the viscera we cannot see what is going on, and it is therefore necessary always to give the largest amount of Roentgen rays which the skin will stand. *The risk of metastasis can be forestalled only by a careful study of the sites peculiar to each form of cancer, and by their prophylactic irradiation.*

When very stout subjects are concerned, the hardest existing bulb is not always capable of delivering an effective dose to an internal tumor without grave injury to the skin. We must therefore demand from the makers an increase in the penetrative power of their tubes. Although it is theoretically possible to construct tubes of much higher penetration, yet the practical difficulties in the way of increase are very considerable.

Personally Hernaman-Johnson is of the opinion that if tubes were made longer, of thicker glass, and with a wide space between the cathode and the walls, it would be possible to drive them at very high voltage without causing sparks to travel outside and break the glass. We should aim at a penetration at least double the maximum now attainable, and for this an equivalent spark-gap of 18 in. to 20 in. will be necessary.

Having obtained rays of such extreme hardness, we must learn how to utilize their energy to the best advantage. By the introduction of heavy atoms into tumor cells it is possible actually to produce a greater physiologic disturbance at a depth of 2 cm. than at the surface itself. Wassermann claims that he has succeeded in introducing selenium atoms into malignant cells without seriously affecting normal cells; when this can be accomplished easily and safely the problem of Roentgen ray dosage in deepseated cancer may be considered as solved. Granting that the physiologic action of Roentgen rays on the tissues is increased by the presence of heavy elements, the converse should also hold good. The diminution of the iron content of the skin by adrenalin prior to deep irradiation is therefore a procedure resting on a sound theoretic basis.

### BOOK REVIEWS.

Die Röntgen-Literatur. Part II. Title index. By order of the Deutsche Röntgengesellschaft and in co-operation with the special committee. Prof. Dr. Hermann Gocht, Halle a. S.

Stuttgart, Ferdinand Enke. 1912. Pp. 508.

In time past the reviewer has, with some effort, attempted to maintain an index of roentgen literature. The result, attained with meagre facilities, has been crude and imperfect. The sole excuse for its continuance, the fact that (so far as the writer knew) no one was doing it better, and that it was being thankfully received by a considerable number of workers. Last year the first part of this work was issued, but, being indexed only by authors, was almost useless to American readers. The Deutsche Röntgengesellschaft then took the matter up and appointed a special committee of twelve to co-operate with Prof. Gocht to rewrite his work as a title-index.

The result is this magnificent book which renders all smaller effort not only needless but valueless.

Five divisions are made, each with several subdivisions. Books and Transactions, 17 pages; Physics and technic, 105 pages; Diagnosis, 234 pages; Therapy, 146 pages; Medicolegal, 6 pages.

Under each subdivision the former method of listing alphabetically by authors is retained. Americans will find this something of a handicap, but rather the less so, because of the comparatively small number of titles in each subdivision.

Among articles whose titles do not indicate their roentgenologic value, there are some important omissions as instanced by the one by Robert Jones on the knee-joint. Even in this class however the work has been comprehensive. As each title is given in the language in which it originally appeared, the book will be useful to the reader who has command of only one tongue.

For this sufficient reason the reviewer will hereafter direct his effort along other lines.

D. R. B.

The Skiagraphy of the Accessary Nasal Sinuses by A. Logan Turner and W. G. Porter, published by Wm. Green & Son, Edinburg, 1912.

This volume which has just come to hand takes up in a very complete way the value of Roentgenography in the examination of the accessory sinuses. The writers discuss first in a comparatively brief manner the question of technique, laying especial emphasis upon the necessity of a careful choice of tube and accurate exposure. They do not however, accentuate the question of immobilization of the patient upon which fine bone detail will largely depend.

The next portion of the book deals with the interpretation of the normal appearance of the accessory cavities and this part of the work is especially valuable, as the interpretation is taken up quite in detail. The development of the sinuses in children is entered into and a number of valuable observations are made although the writers conclude that a larger number of cases should be examined before more definite statements can be made. The next part of the text takes up the interpretation of pathologic plates which occur in the back of the work.

The general conclusions which the writers present are a valuable and conservative statement of the value of Roentgenography in this special field of work; they are very careful not to be over enthusiastic upon the possibilities of this aid in diagnosis. In fact the enthusiast in this field might regard their statements as perhaps ultra conservative.

With regard to the illustrations which are full sized and reproduced by the half tone process, we can state that they are of high character and illustrate well the conditions which they are designed to show. Some of the plates however, show the slight movement of inaccurate fixation and the fine grain of the screen which has been employed. However, in as much as they are not reductions, these defects just mentioned are of minor importance, and the plates as a collection offer much material for interesting study and present certainly distinct educational features.

The text and reproductions form a volume which should be in the library of every special worker in Roentgenography and we take great pleasure in recommending it to the members of the American Roentgen Ray Society.

## AMERICAN ROENTGEN RAY SOCIETY.

Minutes of the Proceedings of the Thirteenth Annual Meeting, held at Niagara Falls, New York, September 11 to 14, 1912, under the Presidency of Dr. Frederick H. Baetjer, Baltimore, Maryland.

## FIRST DAY—MORNING SESSION.

The Society assembled in the International Hotel, and was called to order by the President at ten o'clock, with fifty members present.

The minutes of the preceding meeting were called for and the Secretary offered the minutes as printed in the QUARTERLY.

On motion, the minutes were approved as printed.

The Secretary, Dr. Pancoast, then made his report, and inasmuch as it contained a number of suggestions the report was referred for consideration to the Executive Committee.

At the request of the Treasurer, Dr. Charles F. Bowen, the reading of his report was deferred until a subsequent session.

The Chairman of the Executive Committee, Dr. Hickey, presented a brief verbal report, to the effect that the Committee had a number of questions under consideration on which a report would be made at a later session.

Dr. Hickey then presented the following amendment, which was read by the Secretary and referred for action on the next day:

To amend Art. IV, Section I, as follows: "The officers shall be a president, first and second vice president," the remainder of the section to read as at present, the change providing for two vice presidents, instead of five.

The Secretary then read a cablegram from the German Roentgen Society, signed by Dr. Koehler and Dr. Immelmann, wishing the American Roentgen Ray Society a very successful meeting. (Applause.)

On motion, the Secretary was instructed to write to the German Roentgen Society expressing the appreciation of this Society at being remembered at this time.



The Librarian, Mr. H. W. Dachtler, presented a brief verbal report. He stated that he now has twelve complete sets of the Quarterly and a number of reprints; that he was making provision for the proper housing of this material. He asked for instructions as to what disposition should be made of the material at hand.

Dr. A. L. Gray moved that the journals and other printed matter in the Librarian's charge be kept as the property of the Society, to be disposed of only by vote of the Society. Seconded and carried.

Dr. Kennon Dunham moved that a complete set of the journals be sent to Dr. Eichmann, with the compliments of the Society. Seconded and carried.

At this juncture the President announced that the polls would be open at twelve o'clock noon for the election of one member of the Executive Committee, in accordance with the amendment to the Constitution made at the previous annual meeting. The polls would close, he said, on the following day at twelve noon.

The Society then adjourned until 2 P. M.

#### AFTERNOON SESSION.

The Society reassembled at 2 P. M., and was called to order by the President.

The scientific portion of the program was then taken up. The first paper was read by Dr. E. H. Skinner, of Kansas City, Mo., on "Circulatory Opacities." No discussion.

Dr. Arthur F. Holding, of New York City, followed with a paper entitled "The Education of the Roentgenologist."

This paper was discussed by Drs. Percy Brown, P. M. Hickey, W. H. Stewart, and in closing by the essayist.

Dr. David R. Bowen, of Philadelphia, contributed a paper entitled "The Library of the Roentgenologist." No discussion.

Dr. Paul Eisen, of Milwaukee, Wis., read a paper on "Description of a Safe and Practical Method of Combining Fluoroscopy with Radiography in Abdominal Diagnosis."

This paper was discussed by Dr. E. H. Skinner.

The next paper was read by Dr. J. T. Case, of Battle Creek, Mich., entitled "X-ray Studies of Colon Pathology with Special Reference to the Ileocecal Region."

Dr. E. H. Skinner, of Kansas City, Mo., then read a paper entitled "Fluoroscopy Versus Radiography in Gastro-Intestinal Diagnosis."

Dr. Max Kahn, of Baltimore, Md., by invitation, read a paper

entitled "The Roentgen Ray Study of Twenty-Two Cases of Ptois of the Stomach and Colon Before and After Operation."

Dr. Sidney Lange, of Cincinnati, read a paper entitled "Abdominal Diagnosis."

These four papers were discussed by Drs. A. F. Holding, H. Hulst, G. E. Pfahler, Percy Brown, A. J. Quimby, A. L. Cole, W. H. Stewart, D. R. Bowen, W. S. Newcomet, F. H. Baetjer, P. Eisen, Cotton, J. T. Case, E. H. Skinner, Kahn, and Lange.

The Society then adjourned.

### SECOND DAY—MORNING SESSION.

The Society reassembled at 9:30, and was called to order by the President.

The first paper was read by Dr. Russell H. Boggs, of Pittsburg, entitled "A Plea for More Conservative Treatment of Malignant Growths."

Dr. Chevalier Jackson, of Pittsburg, by invitation, discussed the question of "Conservative Surgery from a Laryngologic Viewpoint."

These two papers were discussed by Drs. G. E. Pfahler, A. M. Cole, Albert Soiland, W. T. Browne, H. W. Dachtler, K. Dunham, A. J. Quimby, P. M. Hickey, J. T. Case, Geo. C. Johnston, H. Humphries (London, England), Pirie, Boggs, and Jackson.

Here the Secretary read a cablegram of congratulation and best wishes from Drs. F. Haenisch and E. W. Caldwell.

Dr. A. W. Crane, of Kalamazoo, Mich., then read a paper entitled "Case Reports Illustrating the Roentgen Diagnostics of Internal Medicine," which was discussed by Drs. Lange, Gray, Eisen, Pfahler, Johnston, and in closing by the essayist.

A paper entitled "The Roentgen Ray in the Diagnosis of Sphenoidal Diseases" was read by Dr. Geo. E. Pfahler, and discussed by Drs. Pancoast, Baetjer, Johnston, Gray, W. H. Stewart, Quimby, Hickey and Pfahler, in closing.

The President announced that the polls were to be closed at twelve o'clock noon, and appointed Drs. T. S. Stewart and Dachtler to act as tellers.

The Society then adjourned.

### AFTERNOON SESSION.

The meeting was called to order by the President at two o'clock.

The first paper on the program was read by Dr. Andre Crotti, of Columbus, Ohio, entitled "The Roentgen Examination of Goiter."

Dr. Charles F. Bowen, of Columbus, collaborated with Dr. Crotti in the preparation of this paper.

The discussion was participated in by Drs. Lange, Hulst, Pfahler, Hickey, Baetjer, Johnston, Percy Brown, Boggs, Dunham, Dachtler, Pirie, Quimby, and in closing by Drs. Charles F. Bowen and Andre Crotti.

On motion, a rising vote of thanks was extended to Dr. Crotti for his very excellent contribution.

The next paper was contributed by Dr. Kennon Dunham, of Cincinnati, entitled "Characteristic Plate Markings of Tubercular Cases with Reference to Children."

This paper was discussed by Drs. Hulst, Lange and Dunham.

Dr. Wm. H. Stewart, of New York City, then read a paper entitled "The Roentgen Ray as an Aid in the Diagnosis of Fractures of the Skull." No discussion.

On motion of Dr. Johnston, the Society then went into Executive Session.

The tellers announced that the votes cast for member of the Executive Committee had been counted, and that Dr. George C. Johnston, of Pittsburg, had received the greatest number of votes.

The Chair duly announced the result and declared Dr. Johnston elected.

Dr. Charles F. Bowen then presented the Treasurer's report, which was referred to the Executive Committee for audit.

Dr. Hickey, Chairman of the Executive Committee, reported that his Committee had carefully considered the suggestions contained in the report of the Secretary, and respectfully recommended that Dr. Wm. H. Sweet, of Philadelphia, be given honorary membership in the Society.

On motion, this recommendation was accepted.

The Committee further recommended that the President appoint a committee of three, to be known as the Committee on Nomenclature, said Committee to consider the preparation and prepare a report on the proper nomenclature of all matters connected with the Roentgen ray, the Committee to report later during this session.

Seconded and carried.

The Chair appointed on this Committee Drs. Fred. C. Zapffe, D. R. Bowen, and Percy Brown.

The Committee further recommended that the President appoint a committee on International Standards for the Measurement of the Roentgen Ray. Seconded and carried.

The Chair announced that this committee would be appointed later.

The Executive Committee reported favorably on the applications for membership of Drs. A. Hartung, Chicago; J. Daland, Philadelphia; Pirie, Montreal; Kost, —; and Brosius, —.

On motion, the report of the Executive Committee was accepted and the Secretary was instructed to cast the ballot of the Society for the election to membership of those named in the report.

The Executive Committee then proposed to amend the Constitution as follows:

Art. VII, Section 1: A standing committee of three, to be known as the Committee on Publication, shall have full charge of the publication of the proceedings of the Society. One member shall be elected to serve one year, one two years, and one three years, and thereafter one member shall be elected annually to serve three years. The members of this committee shall be nominated at the annual meeting by the Nominating Committee and elected by the vote of the majority of the members present at such annual meeting. The president, secretary and chairman of the Executive Committee to be members *ex-officio* of this committee. This committee shall appoint the editor of the AMERICAN QUARTERLY OF ROENTGENOLOGY.

The amendment to the Constitution proposed by Dr. Hickey on the previous day was then read, and, on motion, duly seconded. It was adopted. The amendment reads as follows:

"The officers shall be a president, first and second vice president," the remainder of the section to read as at present, the change providing for two vice presidents, instead of five.

The Chair then appointed the following Nominating Committee: Drs. Percy Brown, Russell H. Boggs and Roland Hammond.

On motion, a vote of thanks was extended to Dr. Leonard Reu and the other members of the local committee for the excellent arrangements made, and their untiring energy in making this a successful meeting.

Dr. Geo. E. Pfahler moved that messages of greeting be sent



to Dr. Charles L. Leonard, E. W. Caldwell, J. H. Edmonson, and G. P. Girdwood, who were unable to be present at this meeting.

Seconded and carried.

The Society then adjourned until 9 A. M.

### THIRD DAY—MORNING SESSION.

The Society reassembled and was called to order by the President at ten o'clock.

Dr. Chevalier Jackson, of Pittsburg, addressed the Society on the subject of "Bronchoscopy and Esophagoscopy."

The subject was discussed by Drs. Johnston, Boggs, Hickey, C. F. Bowen, and Skinner.

The Society then adjourned until 2 P. M.

### AFTERNOON SESSION.

The Society reassembled at 2 o'clock, and was called to order by Vice-President Eagar.

Mr. Sewall Cabot, of Boston, Mass., then read a paper by invitation entitled "A Comparative Analysis of the Energy Furnished by the Various Types of X-Ray Apparatus."

This paper was discussed by Mr. Snook, Mr. Dachtler, Dr. Percy Brown, and in closing by Mr. Cabot.

Mr. H. Clyde Snook, of Philadelphia, then gave a historic sketch with lantern slide illustration of "The Development of the X-Ray Tube."

The discussion on this subject was participated in by Drs. Percy Brown and Pirie.

Dr. Leonard Reu, of Buffalo, demonstrated an automatic switch.

Dr. D. R. Bowen, of Philadelphia, contributed an article entitled "Laboratory Notes," which was discussed by Drs. Imboden, Percy Brown, Holding, W. H. Stewart, Hickey, Johnston, Quimby, Pirie, and in closing by Dr. Bowen.

Dr. E. H. Skinner, of Kansas, City, Mo., presented "Designs and Plans for a Private X-Ray Laboratory."

On motion, the paper by Dr. J. H. Edmonson, of Birmingham, Ala., entitled "Indications for Massive and Small Dosage in Epitheliomata," and also the paper by Dr. Gerardo Balboni, of Boston, entitled "Artificial Pneumothorax in the Treatment of Pulmonary Tuberculosis," were read by title and ordered published in the QUARTERLY.

On motion, the Society then went into executive session.

The amendment to Article VII, offered by the Executive Committee, was again read and, on motion, duly seconded; it was adopted.

The Chair announced that the President had appointed as the Committee on International Standard Drs. E. W. Caldwell, George C. Johnston, and Pirie.

Dr. Percy Brown, Chairman of the Nominating Committee, then presented the following recommendations for the choice of officers for the coming year: President, Dr. Henry K. Pancoast, Philadelphia; Vice-Presidents, Drs. A. W. Crane, Kalamazoo, Mich., and Charles F. Bowen, Columbus, Ohio; Secretary, Dr. Sidney Lange, Cincinnati, Ohio; Treasurer, Dr. Leonard Reu, Buffalo, N. Y.; Librarian, Mr. H. W. Dachtler, Toledo, Ohio. The Committee asked for further time to make recommendations for the membership of the Publication Committee. The request was granted.

On motion of Dr. Johnston, the President was instructed to cast the ballot of the Society for the unanimous election to the offices named of the nominees, which he did.

The Society then rose from executive session and proceeded with the scientific program.

Dr. Alfred L. Gray, of Richmond, Virginia, presented a paper entitled "Roentgenization for Laryngeal Vegetations."

This paper was discussed by Drs. Hickey, Pancoast, Johnston, and in closing by the essayist.

The next paper, entitled "Adjuvants to Surgical Treatment of Malignancy," by Drs. L. G. Cole and A. F. Holding, of New York City, was read by Dr. Holding. It was discussed by Drs. Johnston, Pfahler, Dachtler, Crane, Pirie and Holding, in closing.

Dr. E. H. Skinner, of Kansas City, Mo., followed with a paper entitled "A Simplified Method of Prognosis in Fractures of the Ankle and Wrist."

The discussion of this paper was participated in by Drs. Reu, Hammond, Cotton, Dachtler, Baetjer, Gruber, and Skinner, in closing.

The scientific program outlined for the day having been completed, the Society again went into executive session.

The Nominating Committee completed its report by presenting for membership on the Publication Committee the following names: Drs. P. M. Hickey, one year; Dr. D. R. Bowen, two years; Dr. J. T. Case, three years.

On motion of Dr. Pfahler, the report was accepted and the Chair declared the members named duly elected.

Dr. Hickey then presented briefly for discussion the question of publishing in some form, such, perhaps, as an atlas, or a supplement to the QUARTERLY, prints of the best plates exhibited each year in the plate exhibit at the annual meeting.

On motion of Dr. Hull, the Publication Committee was empowered to publish prints of such plates as were passed on favorably by the Executive Committee, and in such form as was most practicable.

Dr. D. R. Bowen then moved the appointment of a committee which is to provide, at the expense of the Society, suitable means for illuminating the plate exhibit at the annual meeting. Seconded and carried.

The Society then adjourned until 9:30 A. M.

#### FOURTH DAY—MORNING SESSION.

The Society reassembled and was called to order by the President at 9:30 o'clock.

Dr. R. O. Meisenbach, of Buffalo, N. Y., read a paper entitled "Sacro-Iliac Relaxation."

The paper was discussed by Drs. Hammond, Johnston, Hickey, Coon, Dunham, Lange, Baetjer, and in closing by Dr. Meisenbach.

Dr. Roland Hammond, of Providence, R. I., followed with a paper entitled "What is the Roentgen Picture of Bone Tuberculosis?"

The discussion on this paper was opened by Dr. Hickey, and continued by Drs. Lange, Coon, Cotton, Baetjer, and closed by Dr. Hammond.

Dr. P. M. Hickey, of Detroit, Michigan, read a paper on "The Antero-Posterior Position in the Examination of Mastoids."

This paper was discussed by Drs. Lange, Pfahler, and Hickey, in closing.

A paper by Dr. E. H. Skinner, of Kansas City, Mo., entitled "Studies in Comparative Dental Anatomy" was ordered read by title and referred to the Publication Committee for publication in the QUARTERLY.

This concluded the scientific program of the thirteenth annual meeting, and the Society then went into executive session.

The Executive Committee reported that it had considered carefully the question of the place for holding the next annual

meeting, but was unable to arrive at a conclusion. The Committee, therefore, presented for the choice of the Society the names of the cities of Cleveland and Boston.

Dr. Dunham moved that the next annual meeting be held in Cleveland. Seconded. Lost.

The Chair then announced that inasmuch as the names of only two cities had been presented, and the Society having indicated by a vote that Cleveland was not the choice of the place for holding the next annual meeting, Boston is selected.

The Executive Committee recommended that Dr. Ball Butler, of Boston, be elected to active membership in the Society.

On motion, the recommendation was accepted and Dr. Butler was duly declared elected to membership.

Dr. Fred. C. Zapffe, the Chairman of the Nomenclature Committee, reported briefly that the Committee had considered the question of nomenclature as thoroughly as was possible in the time at its disposal, and that the task had been found so great that the Committee respectfully requested that it be allowed further time in which to make a report, or that a new Committee be selected to present a detailed report at the next annual meeting.

On motion, this Committee was continued, with instructions to report at the next annual meeting.

The Executive Committee reported that the Treasurer's books had been audited and found correct.

On motion, the report was accepted.

Dr. Baetjer, the retiring President, then presented to the Society the President-elect, Dr. Henry K. Pancoast.

Dr. Pancoast favored the Society with a few well-chosen words, which elicited great applause.

The President asked permission to defer naming the Committee which is to take charge of furnishing apparatus for illuminating the plates exhibited at the annual meeting until a later time. Such permission was granted.

Dr. Pfahler moved that a vote of thanks be extended to the outgoing officers for their excellent services. Seconded and carried.

Dr. Baetjer moved that a special vote of thanks be extended to Dr. Charles F. Bowen, the retiring Treasurer, for his untiring efforts on behalf of the Society, and for the splendid manner in which he had conducted the work of his office. Seconded and carried.



At this juncture, Dr. Pirie was given permission to exhibit a stereoscopic fluoroscope of his invention.

There being no further business to come before the Society, it adjourned, subject to call by the Executive Committee.

F. H. BAETJER,  
*President.*

HENRY K. PANCOAST,  
*Secretary.*

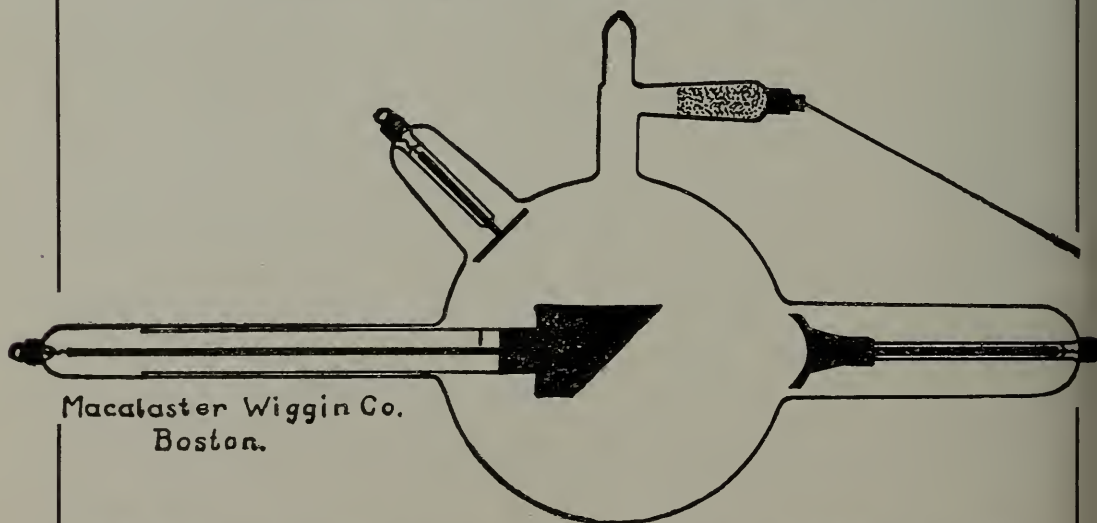
Compact — Authoritative — Practical

Our New Manual of  
**X-Ray Practice  
and Technique**

FREE ON REQUEST

**G. Cramer Dry Plate Company**  
St. Louis, Missouri

**Tungsten Target Tubes for Use on  
the Heaviest Generators**



Macalaster Wiggin Co.  
Boston.

**MACALASTER - WIGGIN COMPANY**

600 Sudbury Building  
BOSTON, MASS.

154 W. Lake Street  
CHICAGO, ILLS.





VERNON JUSTIN WILLEY, A. M., M. D.  
Born 1872, Died 1912

"In him, American Roentgenology lost its most promising aspirant for lasting honor"



# American Quarterly of Roentgenology

*Editor, P. M. Hickey, M. D., Detroit*  
*Associate Editor, F. C. Zapffe, M. D., Chicago*

---

---

VOL. IV.

FEBRUARY, 1913

No. 3

---

---

## CASES ILLUSTRATING THE ROENTGEN DIAGNOSTICS OF INTERNAL MEDICINE.

BY A. W. CRANE, M. D., KALAMAZOO, MICH.

The purpose of this paper is to emphasize the mutual dependence of the X-ray, the laboratory and the clinical examination. I shall maintain the following propositions:

- (1) The roentgenologist should interpret his own plates and screen observations.
- (2) X-ray findings should be interpreted in every case in conjunction with the clinical and laboratory findings.
- (3) It is proper and desirable for the medical graduate who devotes himself to X-ray work to take his stand as a consulting diagnostician and to maintain a clinical laboratory in connection with his X-ray equipment.
- (4) A clinical laboratory is needed for therapeutic as well as for diagnostic X-ray work.

With these four propositions in mind I will cite a few cases to illustrate Roentgen diagnostics in internal medicine.

**Case 1.** Miss L., age 24, thin anaemic, complains of cough, expectoration, progressive loss of flesh and strength, loss of appetite, and general malaise. Left shoulder slightly drooped. Expansion on left side lagging, slight dullness in front on left side on percussion below clavicle for a strip of an inch which widens towards median line. Rales heard a part of time over apex and regularly distinguished close to spine at back on forced expiration. A 14 by 17 plate shows heavy wide shadows at the

hilum of each lung with numerous denser foci in scattered groups especially on left side where a thin but definite shadow extends towards the apex. A sample of sputum examined in the laboratory shows numerous tubercle bacilli. The case is painfully clear from the beginning. Every sign and symptom stamps the young woman with the insignia of the army of the white plague. The X-ray has defined with unerring precision the exact extent of the pulmonary invasion. We feel that such cases are only too easy to diagnosticate.

In such cases as these the decisive factor in the diagnosis is not the X-ray plate or indeed wholly the clinical examination. It was the laboratory findings, the examination of the sputum and the Wassermann test.

**Case 2.** Mr. F., age 60, formerly a train dispatcher. Complains of a persistent pain in right shoulder extending over scapular area and also down arm to elbow. Patient subject to rheumatism. Clinical diagnosis, rheumatic neuritis of branches of the brachio-plexus. Treatment by the high frequency and aspirin gave great relief which was, however, temporary, the pain returning each time within a day or two following treatment. This went on for many months. The patient had been stripped and examined in detail several times. On general principles we took a skiagraph of the chest and found a dark shadow above the heart. Screen observations demonstrated an expansile impulse and the diagnosis of aneurism of the aorta was made.

**Case 3.** Mrs. McC., age 32, complained of pain in right shoulder over scapular region and down arm to elbow. Patient gives a long history of chronic rheumatism. The joints, hand and wrists are enlarged, painful and many are ankylosed. The right knee solidly ankylosed. Almost every joint of the body affected in some degree. Hence the pain in shoulder was diagnosticated as an extension of the old prevalent trouble. The high frequency and aspirin relieved the pain for a few hours. Notwithstanding the clear clinical history pointing to an extension of an infection arthritis, a chest plate was made. A dense shadow could be seen above the heart in the region of the aorta. On fluoroscopic inspection a movement of the shadow could be observed but no unequivocal expansion with each heart beat. Her symptoms were at once ascribed to this growth in the mediastinum. Patient went to a great medical school where the professor of medicine made the diagnosis of aneurism, after

seeing the X-ray plate. The diagnosis nevertheless being between aneurism and mediastinal tumor. A later screen observation gave us evidence of fluid in the pleural cavity. A needle was introduced and a syringe full of clear straw colored serum was withdrawn. The question of tuberculosis now arose. The serum was allowed to clot, the clot whipped to get rid of plasma. The solid residue digested in a thermostat to liquefaction, sedimented in a centrifuge and the sediment examined for tubercle bacilli, none were found. The Von Pirquit skin reaction was negative. Syphilis is usually the cause of aneurism. A Wassermann was made and was negative. Therefore to assemble the evidence we could exclude tuberculosis and syphilis. We could not define an expansile impulse. We have fluid in the pleural cavity and we have a progressive lesion because the patient grew steadily worse. The diagnosis therefore of mediastinal tumor, probably sarcoma, seemed the inevitable conclusion. Some months later autopsy showed a sarcoma filling in the entire upper part of chest.

**Case 4.** Mr. F., age 37, harness maker, complained of spells of pain in back in right renal region, frequent and often painful micturition, loss of appetite, sour eructations, pains after eating, general loss of flesh and strength. Urinalysis showed 1% of pus and 1/10% of albumin, acid, sp. gr. 1018. Stone suspected and diagnosis suspended pending X-ray examination. Plates were negative. Case reviewed. Urine obtained by catheter and examined bacteriologically. Tubercle bacilli in large numbers. Diagnosis, renal tuberculosis.

**Case 5.** Mr. V., age 60, retired, complained of spells of pain in back, frequent and often painful micturition. The symptomatology being substantially as in Case 7 excepting that the general health was not appreciably impaired. Stone suspected. Skiagraphed. No stone found. Bacteriological examination of urine yielded a pure culture of the colon bacillus. Diagnosis, colon infection of urinary tract.

**Case 6.** Mr. C., age 35, lawyer, illustrates the care necessary to keep from jumping at conclusions. This case was skiagraphed by me many years ago and three stones discovered. It was the first kidney stone case operated upon by Bevan of Chicago, where the diagnosis was made by the X-ray. The stones were successfully removed. A year before another sur-



geon had operated and removed a stone. Three years ago the patient began to complain of spells of pain in the site of the old operations and had cystitis with pus in urine. The clinical diagnosis of urinary calculi in kidney and bladder was strongly supported by the previous history of the case. Repeated plates, however, failed to show stone. We made a bacteriological examination of the urine and showed a pure colon infection.

In confirmation of the diagnosis being the true cause of the patient's suffering in the last two cases, I will add that autogenous vaccines brought permanent relief.

These three cases and they are typical of many, illustrate the importance to the patient of a conjunction of laboratory and X-ray methods.

**Cases 7 and 8.** Both women past 40 have general dyspeptic symptoms and are typical of many cases. Bismuth outlines upon the plates show that both stomachs are markedly relaxed with the greater curvature of each much below the crest of the ilium. Neither shows any deformity that could mean ulcer or cancer. The look of the duodenum enclosing the head of the pancreas gives no hint of an abnormality in that direction. A second plate 8 hours later shows the stomach empty of bismuth. How many of such cases leave the X-ray expert with purely negative findings and negative findings rarely appeal to the attending physician or to the patient, at their full value from either a diagnostic or pecuniary point of view.

But by having a routine procedure whereby the patient is prepared for the X-ray examination by a night's fast and an Ewald's test breakfast, we are enabled to withdraw the stomach contents partly to insure an empty stomach but chiefly to obtain a sample of the gastric juice for the laboratory analysis.

In case 7, for example, we find a marked HCl hyperacidity.

In case 8, for example, we find HCl subacidity with fermentation acids and excess of indican in urine. Thus we are provided with definition data upon which to base an opinion which is of real value to the patient and the attending physician.

**Case 9.** Mrs. W., age 30, Anaemic nervous. Complains of constipation and attacks of pain over McBurney's area. Surgical diagnosis:—Recurrent appendicitis. Plates show prolapse of caecum and ascending colon. Pain marker of lead lies over hepatic flexure which has been drawn into the appendix area.



An examination of the stool during an attack reveals typical mucous casts of the colon. Diagnosis, mucous colitis. To have witnessed an operation on this case would have been to have witnessed the removal of one more healthy appendix in the case of so called typical appendix.

Thus the Roentgen diagnostics of Internal Medicine are seen to be inextricably bound with microscope, the stethoscope, and the test tube.

THE PROGNOSIS OF ANKLE AND WRIST FRACTURES, A METHOD OF ESTIMATION FROM X-RAY NEGATIVES.

BY DR. E. H. SKINNER, OF KANSAS CITY.

The prolific use of the X-ray in recent years has forced more attention to the anatomical reduction of fractures. Anatomical reduction is a worthy ambition but our appreciation of functional reduction has been obtunded thereby. We have failed to interpret X-ray negatives with an appreciation of functional prognosis. Our interpretation has forced undue regard to the reduction of fragments rather than the correct estimation of the position of functional joint surfaces. I desire to show you that less attention need be displayed to fragments if the joint surfaces are in correct relation and the lines of weight bearing force are functionally satisfactory. In an attempt to reduce to mathematical exactness, the relation of certain weight bearing surfaces, I present for your consideration the writer's studies upon two of the commonest joint injuries, i. e., Pott's fractures at the ankle and Colle's fracture at the wrist. My work upon the shoulder and hip is not as yet crystallized into simple estimations.

My studies have been pursued with the idea of bringing this method of prognosis within the reach of the physicians outside of the larger cities and where the X-ray apparatus may not be of large capacity. X-ray negatives for these calculations may be made with small portable coils or static machines with or without intensifying screens. The mathematical diagrams herewith presented may be applied to any such negative if the directions regarding the position of the parts are followed.

**Fractures at the Ankle.**

**Axiom.**—The functional result of an ankle fracture depends upon the proper reduction of the astragalus so that the line of

weight bearing force, which passes through the center of the tibia, also passes through at its center.

### Directions for Exposures of Ankles.

The illustrations which serve to amplify this article are enlargements from small 5x7 plates. The X-ray exposures are always made with the leg resting upon the long surface of a right angle frame and the foot is supported by a Esmarch bandage or heavy rubber bands against the right angled foot piece. The 5x7 plate is placed posterior to the ankle with the lower edge reaching just to the sole of the foot at the heel. The X-ray tube is centered in the adult, one inch above the center of a line connecting the external and internal malleolus. An exposure with even the crudest apparatus will give a negative upon which the line of weight bearing force may be charted whether the fracture line shows or not.

The charting of this described line of weight bearing force may be made upon the finished negative by means of any straight edge. We use a celluloid rule or the taut curtain cord at the window against which the negative is being viewed.

The interpretation of the plate depends not so much upon the shadow of the lines of fracture as upon the shadows of the relative position of the tibia and astragalus. Even in a fair X-ray negative and most certainly in a poor one it is often impossible to determine the fracture itself. I refer here more especially to the fracture sprain of the lower end of the fibula. One must therefore judge of the injury by the position of the astragalus. The difficulty in the X-ray situation is due to the characteristics of the fibula and to the superposition of the tibial shadow upon that of the fibula. The fracture is usually upward and backward from the center of the anterior border of the external malleolus of the fibula with very little and frequently no apparent displacement. It is therefore necessary to possess an interpretative knowledge of the normal ankle joint spacing. The anteroposterior position negative gives us the information regarding the mortise between the astragalus and tibia.

To judge the normal or abnormal relationship of the tibia-astragaloid articulation, we must realize that the head of the astragalus is firmly mortised between the lower end of the fibula and the internal malleolus and is directly beneath the broad articulating and weight-bearing surface of the tibia. This gives only sufficient room between the internal lateral border of the head of the astragalus and the tibia for some ligaments and the action of the joint. The shadow of a normal ankle upon the X-ray plate indicates that there is approximately one-eighth of an inch space in the adult between the astragalus and the internal malleolus. This space increases with the slightest torsion fracture of the fibular malleolus, for it is entirely due to the integrity of the lower end of the fibula that the astragalus remains mortised correctly.

Provided we have established by the X-ray the diagnosis of a torsion fracture of the lower end of the fibula, we are at once interested in methods of reduction and fixation that will promote a functioning ankle as a result. Examination of a large number of results of ankle fractures, both in hospital and private practice has taught me that the proper treatment of these cases is extremely difficult. True the fracture is a slight and simple affair, but the broad, painful ankle that so frequently results, merits our attention to details.

**"The secret of the correction of this fracture lies in the proper adaptation of the astragalus to the tibia."** The weight bearing line of the tibia is transmitted to the foot by way of the broad articulating surfaces of the tibia and astragalus. It is essential that this relationship be maintained to insure a useful ankle joint. For years we have enjoyed an epigram something like this: "Take care of the tibia and the fibula will take care of itself; the fibula has no function and the tibia bears the weight of the body." In contrast I would advocate, "Reduce the astragalus and avoid painful ankles." And to properly reduce the astragalus requires attention to the fibula, for by the lower end of the fibula alone is the astragalus properly adapted to the weight-bearing tibia.



The astragalus supports the weight of the body upon its broad surface, articulating with the broad inferior surface of tibia. The external malleolus only serves to keep the astragalus in place. It bears no weight. It only forms the external border of the ankle mortise.

A line drawn through the center of the tibia extends through the center of the astragalus. This line may be charted upon the anteroposterior X-ray negative by applying a line to the center of the tibial shaft and extending it downward through the shadow of the astragalus. This vertical line should always extend through the center of the astragalus if the ankle joint is in normal position.

Now we know that the integrity of the ankle depends upon how well the lower end of the fibula performs its mortising function. The large majority of ankle fractures and chronic ankle sprains are fractures of the external malleolus in the manner described in a previous paragraph. It frequently happens that the position of the fragment in a fracture of the external malleolus is in apparently good position but the mortise of the ankle joint is sprung open by the slight outward displacement of the fibular fragment. Conversely, we may have a poor alignment of the fracture but a splendid reduction of the astragalus. It is therefore unnecessary to pursue futile manipulations of the fibular fragment if the astragalus is in correct alignment.

While it is not within my province to proffer surgical advice, it has been my experience that the best results have followed the application of the Duyugtren splint. This method has received ample description in Scudder (1) and Stimson (2). A Duyugtren splint necessitates the internal rotation of the toes, which promotes the correct reduction of the astragalus.

One will readily see that the slightest displacement of the astragalus externally, presents a widened ankle space and if this is not corrected, the patient will ever after have an abnormal line of weight-bearing force. In some cases the ankle may adapt itself to the new position but a little attention to the position of

the toes will avoid many painful and weak ankles of tardy convalescence. A good motto for the surgical attendant should be: "Watch the toes or turn the toes in."

It does not matter what the form of fracture at the ankle whether only of the fibula or of the classical Pott's type or a crushing injury, for, if the anteroposterior X-ray negative shows the astragalus centered under the tibia the prognosis of a functional result will be more favorable than any anatomical alignment of fragments. Nature is wonderfully tolerant of fragments if she can maintain her functional joint surfaces.

### Fractures at the Wrist.

**Axiom**—The styloid process, not just the tip of the radius, is constantly distal to the line which touches the tip of the ulnar styloid, which line is at a right angle to the longitudinal axis of the radius: The functional result of fractures of the radial head depends upon the reduction of the head of the radius to this position:

### Method for X-ray Exposure of the Wrist.

The difficulty in obtaining and interpreting lateral views of the wrist has lead us to this charting of the wrist joint upon a single posteroanterior X-ray exposure. The affected wrist and the naturally extended hand are placed with the palmar surface upon a 5x7 X-ray plate with the one short end of the plate at the web of the thumb. The tube is centered over a point midway between the styloid processes of the radius and ulna. This latter is the simplest X-ray exposure of the whole body and can be easily obtained by any X-ray installation which may be totally inadequate for other parts of the body. The resulting plate provides shadows of the proximal portions of the metacarpals, the carpus and about three inches of the radial and ulnar shafts.

**Anatomical Considerations.** In the normal extended hand the long axis through the center of the radial shaft passes between the proximal epiphyses of the second and third metacarpal bones. In backward displacements of the fractured radial head the radial rotation of the carpal area and metacarpals usually

bring this line between third and fourth metacarpals. But this single line is not sufficient to judge the radial position from the single posteroanterior X-ray negative. So we must add the line at right angles to this longitudinal axis of the radius at a point corresponding to the tip of the ulnar styloid. If the styloid of the fractured radial head is behind this line it is not properly reduced and if left in this position there will remain a functionally imperfect wrist.

It does not matter what the nature of the fracture at the radial head, whether it be an epiphysial separation in youth or a comminuted fracture of the aged, if the reduced radial head provides the above normal charting two lines, one may rest assured of the functional result.

The functional result depends upon the proper adaptation of the carpal articulating surface of the radius. The articulating surface of the normal radius with the carpus is tilted so that the plantar edge of the radial head is always distal to the palmar edge. The correct position of the radial styloid according to the above charting necessitates the normal anatomical position of this articulating surface.


Many writers have described the dropping of the ulna, or the separation of the ulna as the cause of bad results in Colle's fracture. But these objective findings depend upon the tilting backward of the radial articulating surface at the wrist. Furthermore it does not matter if the apposition of the fragments is faulty in contour if the extension is sufficient to replace the articulating surface in its normal position for weight-bearing function.

It is the tilting back of the radial head that interferes with the function at the wrist and this can only be overcome by the full extension of the fragment and the consequent normal position to the articulating surface of the radius.

This charting has been applied to X-ray negatives of all varieties of fractures at the radial head with satisfactory results.









No. 4

No. 4. Pott's Fracture of the ankle. Taken after attempted reduction. More than three-fourths of the astragalus is external to the plotted line, indicating that further reduction is necessary.



No. 5

No. 5. Fracture of the lower end of the fibula after reduction. It will be noted that the anatomical reduction of the fibula appears to be very good but the position of the astragalus is not satisfactory and if the ankle were left in this position there would be an abnormal line of weight-bearing force. This illustrates the necessity of interpreting X-ray negatives with regard to the functional prognosis rather than to the anatomical position of the fragments of a fracture.

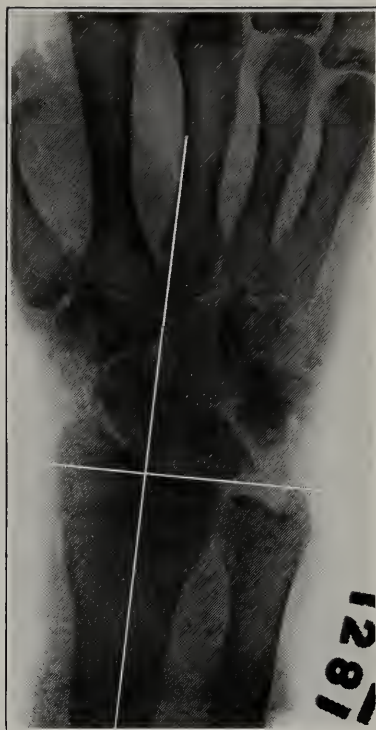

No. 6

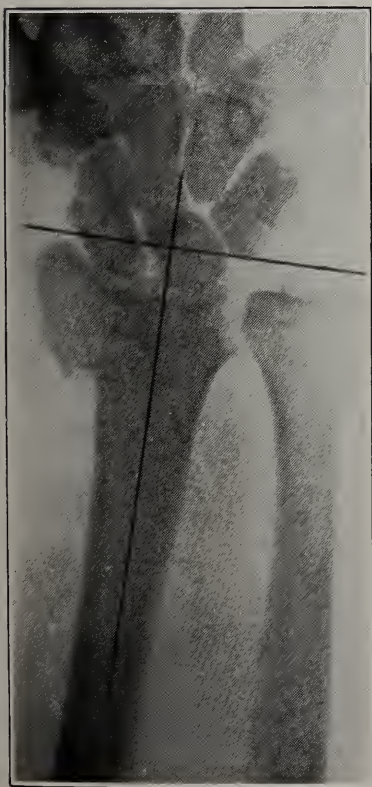
No. 6. Fracture of the lower end of the fibula without a perfect anatomical reduction of the fragments but with a very good reduction of the astragalus. This case made a good recovery. This also illustrates the value of functional prognosis over anatomical reduction of fragments.



No. 7. Illustrating the plotting of lines upon the postero-anterior negative of the wrist. In the naturally extended hand the long axis of the radius usually passes through the interval between the second and third metacarpal bones, but this may be trifle altered if the hand is cramped or influenced by bandages. Note that the styloid of the radius is entirely distal to the horizontal line, which is at right angles to the long axis of the radius and just touches the tip of the ulnar styloid.



No. 7



No. 8

No. 8. Fractured radius. Note that the styloid of the radius is proximal to the cross line, indicating a backward and upward displacement of the radial head. The long axis of the radius now passes down between the third and fourth metacarpal bones owing to the rotation of the hand and carpal area with the displaced radial head.








No. 9

No. 9. Lateral view of same case as No. 8. This is shown to prove the interpretation made under No. 8, and to show the direction of the joint surface of the radial head when there is a backward and upward displacement of the radial head. Normally, the joint surface of the radial head exhibits the dorsal edge distal to the palmar edge but when there is any displacement backward and upward it exhibits just the opposite, which is here illustrated. See No. 11 for normal position.

No. 10. Fractured radial head reduced. This is the same case as No. 8 after reduction and while in a plaster cast. Note that we now have the normal plotting of the two lines and the styloid of the radius is distal to the cross line.



No. 10

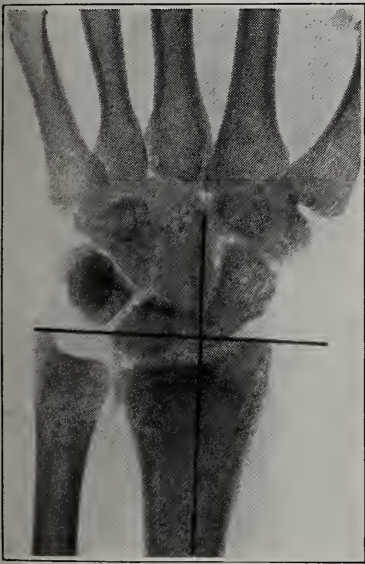

No. 11. Lateral View of No. 10, showing the head of the radius reduced and the joint surface of the radius in normal position. Compare this with No. 9. This is the normal position of the joint surface of the radial head with the dorsal edge distal to the palmar edge.



No. 11

No. 12. Separation of the radial head at the epiphysis with backward and upward displacement of the radial head. Note that the radial styloid is proximal to the cross line which may be interpreted as indicating the displacement of the radial head.



No. 12

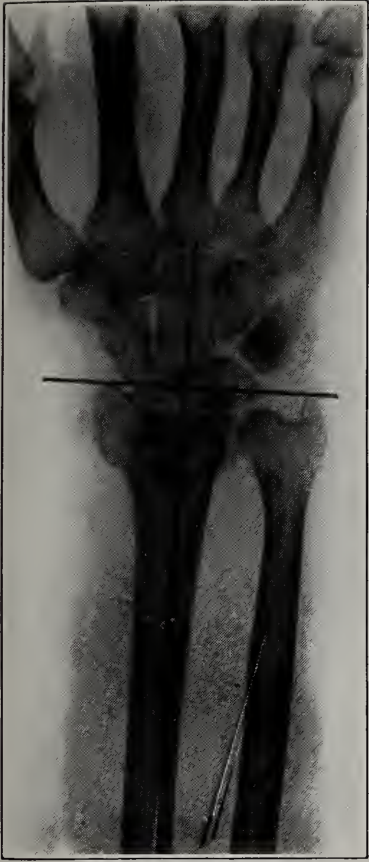No. 13. Lateral view of No. 12, which proves the interpretation of No. 12. Note the abnormal position of the joint surface of the radial head.



No. 13







No. 14

No. 14. Fracture of the radial head with displacement of the radial head backward and upward as indicated by the position of the radial styloid in relation to the cross line.

No. 15. Lateral view of No. 14, proving the interpretation and indicating the abnormal position of the joint surface of the radial head.



No. 15



## WHAT IS THE ROENTGEN PICTURE OF BONE TUBERCULOSIS?

BY ROLAND HAMMOND, M. D., PROVIDENCE, R. I.

This question would seem to be readily answered by reference to the numerous articles on Roentgenology and bone disease in books and current literature. On referring to these articles however, we find a striking lack of unanimity as to the Roentgen appearance of bone tuberculosis. It is generally agreed that the bones composing a tuberculous joint show marked increase in radiability, due to bony atrophy; that the outline of the cortex is often wanting in places, and that the bones at the point of most marked involvement give a "fuzzy", "fluffy" or "shaggy" appearance due to punched out areas of increased radiability. The author of a well-known textbook mentions the bone atrophy, and the numerous, irregular white spots having a natural tendency to coalesce, and then shows as typical of bone tuberculosis, a focus in a finger which might equally well have been a bone cyst or a localized osteomyelitis (Brodie's abscess). The lesion was undoubtedly tuberculous in this case, but the Roentgen appearance is not diagnostic of that disease alone.

It will be generally agreed, I think, that the typical picture of bone tuberculosis is due to the bony atrophy caused by the disappearance of lime salts. This leads to the familiar comment of the patient, or possibly the physician as well, when the plate is exhibited: "Too bad the picture didn't come out better." Part of the haziness of the picture is due to the presence of fluid in the joint and surrounding tissues. And yet this bony atrophy is the foundation on which we base our diagnosis and our prognosis. Freiberg<sup>1</sup> quotes Köhler as describing three types of bone atrophy in Roentgen pictures: 1. Diffuse atrophy of high degree. 2. Diffuse atrophy of varying degree with irregular mottling in certain places. 3. No atrophy unless in a circumscribed area where the shadow is less dense.

In the earliest stage of a tuberculous joint, the Roentgen plate may be to all appearances normal, but another plate taken one or two months later will show beginning bony atrophy, extending for quite a distance on either side of the joint. This atrophy

first appears as a diminution in the size of the bone, and later as an increase in radiability of the texture of the bone. In addition to this, will usually be found loss of contour of the bones forming the articulation, with the fuzzy, shaggy appearance denoting necrosis, and the denser shadow of the soft parts, due to the presence of fluid and of infiltration. Later we may get a localized area of necrosis, often filled with pus and debris, which casts a shadow of varying distinctness according to the density of the contained matter, and after this, the formation of sequestra. As the process goes on to healing, we have a return to the smooth, regular bony outline, and as the healing osteitis becomes marked the shadow is denser than in normal bone.

*Differential Diagnosis.* In syphilis the bone is not translucent but rather porous, and we have the dense shadows of the periosteum and cortex with at times partial obliteration of the medullary cavity. It is said that these thickenings are never found in tuberculosis, and this is true in the early stages when diagnosis is most essential and most difficult. They may be found in the later stages, especially when the shaft is involved.

In rhachitis the pathological process is most active near the epiphyseal line, but the bone outlines are clear except for a "flaming out" and cup-shaped defect of the diaphysis.

Scurvy shows a hammered out epiphysis giving the horizontal, irregular shadow characteristic of this disease. The subperiosteal hemorrhages are also typical when present.

Osteomyelitis is more likely to give confusion in the Roentgen plate when we are dealing with that rare condition—tuberculosis of the shaft. Oftentimes it may be impossible to distinguish between the two by the Roentgen plate alone. There are the punched out areas of increased radiability and the bone atrophy, but we do not find the periosteal involvement in tuberculosis, except in disease of the shaft.

Osteosarcoma rarely involves the neighborhood of the epiphyses and the atrophy is localized. It pushes up or involves the periosteum and is usually sharply differentiated from the rest of the bone structure.

Bone cysts are always sharply differentiated spaces within the bone which is healthy everywhere else.

Does the Roentgen plate give us an accurate means of diagnosing bone and joint tuberculosis? It does, if used in connection



with a clinical study of the case. The Roentgen plate shows us bony atrophy and differences of density according to well known physical laws. Bony atrophy may be due to many causes, especially following trauma, fixation,—the so-called “plaster of Paris disease,”—and disuse. It is now recognized as a frequent accompaniment of atrophy of soft parts following disease or injury, and as such may give a picture on the Roentgen plate closely simulating tuberculosis in the early stages.

Very often the plate does not give us an accurate idea of the extent of the disease. On opening such a joint, it is the experience of surgeons to find areas of necrosis and extensive involvement which are unsuspected from the examination of the plate alone.

The work of Feiss<sup>2</sup> along this line is noteworthy. He made Roentgen examinations of specimens of tuberculous bone which had been obtained at operation or autopsy. The bone was first X-rayed as a whole and the picture obtained corresponded to the condition found in the living. The specimen was then sawn in two and one half of it was X-rayed. The Roentgen plate of this half showed the disease to be more extensive than the plate of the entire bone. The Roentgen picture was deceptive because the bony trabeculæ along one edge of the cavity were thickened and thereby gave the appearance of a limiting wall which did not exist. In another case a vertebra appeared perfectly healthy when X-rayed as a part of the spine, but when sawn in two and one half of it X-rayed, marked tubercular involvement was found. This was not suspected in the original Roentgen plate, because the trabeculæ were superimposed and gave a normal shadow.

*Tuberculous Diaphysitis.* Stiles<sup>3</sup> of Edinburgh, in a recent article, devotes considerable attention to the subject of tuberculous diaphysitis. Although of uncommon occurrence in this country, tuberculosis of the shaft is found by Stiles very commonly in Scotland, and Murphy<sup>4</sup> of Chicago coincides in this view. That this condition does not prevail in Germany is shown by Küttner<sup>5</sup> who, in an examination of 2127 cases of tuberculosis of the bones and joints, found but six cases involving the shafts of the long bones. The Roentgen plates exhibited by Mr.

Stiles are not typical of tuberculosis as we are familiar with the disease, but this is doubtless to be attributed to the differences in the characteristics of the affection in the two countries.

With an idea of getting some information of possible value on the Roentgen appearance of bone and joint tuberculosis, I have examined plates of all cases of this disease at the Rhode Island Hospital, in which a pathological examination of tissue removed later, has shown definitely that the process was tubercular. The plates cover a period of nine years, and include the principal joints in the body.

We may conveniently group these cases according to their Roentgen characteristics:

Group 1. Typical Roentgen Appearance of Bone Tuberculosis.

Case 1. Female, ae. 21. Diagnosis: Tuberculosis of right elbow. Duration 3 months. Operation: curetting of ulna.

*Roentgen examination:* Necrosis of olecranon with fuzziness and loss of contour.

Case 2. Male, ae. 38. Diagnosis: Tuberculosis of ankle. Duration 5 months. Operation: curetting of astragalus, and later amputation of foot.

*Roentgen examination:* Typical fuzzy appearance of astragalus and lower part of tibia.

Case 3. Male, ae. 2. Diagnosis: Tuberculosis of elbow. Duration 7 months. Operation: curetting of ulna.

*Roentgen examination:* General haziness of elbow joint with destruction of tip of olecranon and coronoid process.

Case 4. Female, ae. 39. Diagnosis: Tuberculosis of foot with pulmonary tuberculosis. Duration 1 year. Involvement of all the tarsal and metatarsal bones. Operation: Curetting and later amputation of foot.

*Roentgen examination:* Marked atrophy of all bones of foot and leg. Some destruction of astragalus in forward part and partial fusion with scaphoid; also atrophy and destruction of cortex of external cuneiform and fifth metatarsal.

Case 5. Male, ae. 23. Diagnosis: Tuberculosis of first metatarsal and knee. Duration 3 months. Operation: osteotomy and curetting of first metatarsal.

*Roentgen examination:* Disease of lower two-thirds of first metatarsal, most marked in lower third where areas of necrosis are seen. Cortex is wanting, especially at metatarso-phalangeal joint. All bones are thinned, especially the internal cuneiform.

Case 6. Male, ae. 5. Diagnosis: Tuberculosis of ankle. Duration 3 months. Necrosis of lower epiphysis of tibia. Operation: curetting of bones.

*Roentgen examination:* Haziness and general atrophy with destruction of lower portion of lower epiphyses of tibia and fibula and upper portion of astragalus.

Group II. Showing merely Atrophy. Not typical of Tuberculosis, but disease present.

Case 7. Male, ae. 17. Diagnosis: Tuberculosis of knee. Duration 3 months and longer. Involvement of tibia and femur. Operation: resection of knee.

*Roentgen examination:* Beyond slight atrophy of bones and thickening of soft parts and evidence of fluid in the joint, the Roentgen picture is not remarkable. The bones appear normal, and yet at operation considerable areas of necrosis were found in the femur and tibia.

Group III. Tuberculosis of Several Joints.

Case 8. Male, ae. 6. Diagnosis: Tuberculous osteomyelitis. Duration 6 months. Involvement of lower end of tibia, hand, sterno-clavicular joint and left ilium. Operation: osteotomy and curetting.

*Roentgen examination:* *Ankle*—Increased radiability of lower part of shaft of tibia, with thickening of the periosteum. Fairly sharply defined spot of necrosis in lower part of shaft of fibula, a smaller spot in epiphysis of fibula, and one in lower epiphysis of tibia. Above diseased area bone is normal. *Hand*—Small, well defined area of increased radiability in terminal half of the

terminal phalanx of the thumb, and one in the outer side of the second phalanx of the middle finger.

Case 9. Male, ae. 2. Diagnosis: Tuberculosis of elbow and foot. Duration 6 months. Involvement of ulna, humerus and fifth metatarsal. Operation: excision of metatarsal bone and resection of elbow.

*Roentgen examination:* Considerable destruction of terminal part of fifth metatarsal with loss of cortex; one area of increased radiability in center of bone. Anterior fourth of bone totally necrotic. Other bones show loss of sharp outline and considerable atrophy.

Case 10. Female, ae. 52. Diagnosis: Tuberculosis of Metacarpal Bones. History of rheumatism in hand for 18 to 20 years with a relapse 6 months previously. Under observation for 6 months, when a swelling appeared on dorsum of left hand over the metacarpal bones. Operation: Bone removed from fifth metacarpal for diagnosis found to be tubercular.

*Roentgen examination:* Necrosis of heads of third, fourth and fifth metacarpal bones of right hand, with fracture of shaft of fifth just below head. Fusion of bases of fourth and fifth metacarpals and somewhat of the third. Disease of os magnum, unciform and pisiform with fusion of os magnum and unciform.

#### Group IV. Tuberculosis of the Diaphysis.

Case 11. Female, ae. 11. Diagnosis: Tuberculous Osteomyelitis of Tibia. Duration 2 years. Operation: osteotomy and curetting. Pus sterile.

*Roentgen examination:* Considerable thickening of periosteum and cortex of lower third of tibia with encroachment on medullary cavity by wavy thickenings of cortex. Areas of increased radiability just above the epiphysis.

Case 12. Female, ae. 7, Diagnosis: Tuberculosis Osteomyelitis of entire shaft of Tibia. Duration 7 weeks. Operation: osteotomy and curetting. Sinus found at time of operation from which pus was oozing.



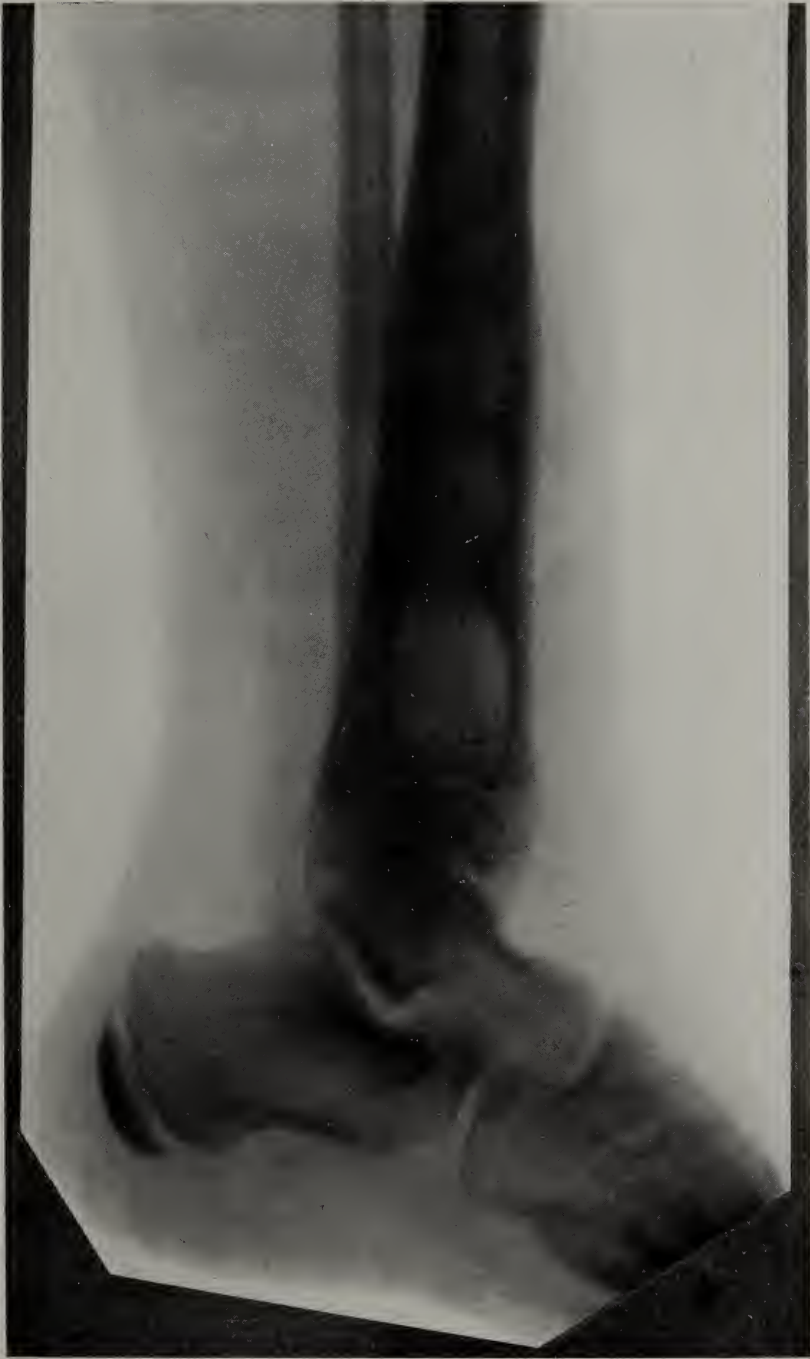

Fig. 1.

Case 11. Tuberculous Osteomyelitis of Shaft of Tibia. Note thickened periosteum and cortex with wavy outline of latter. Almost no involvement of epiphyses.



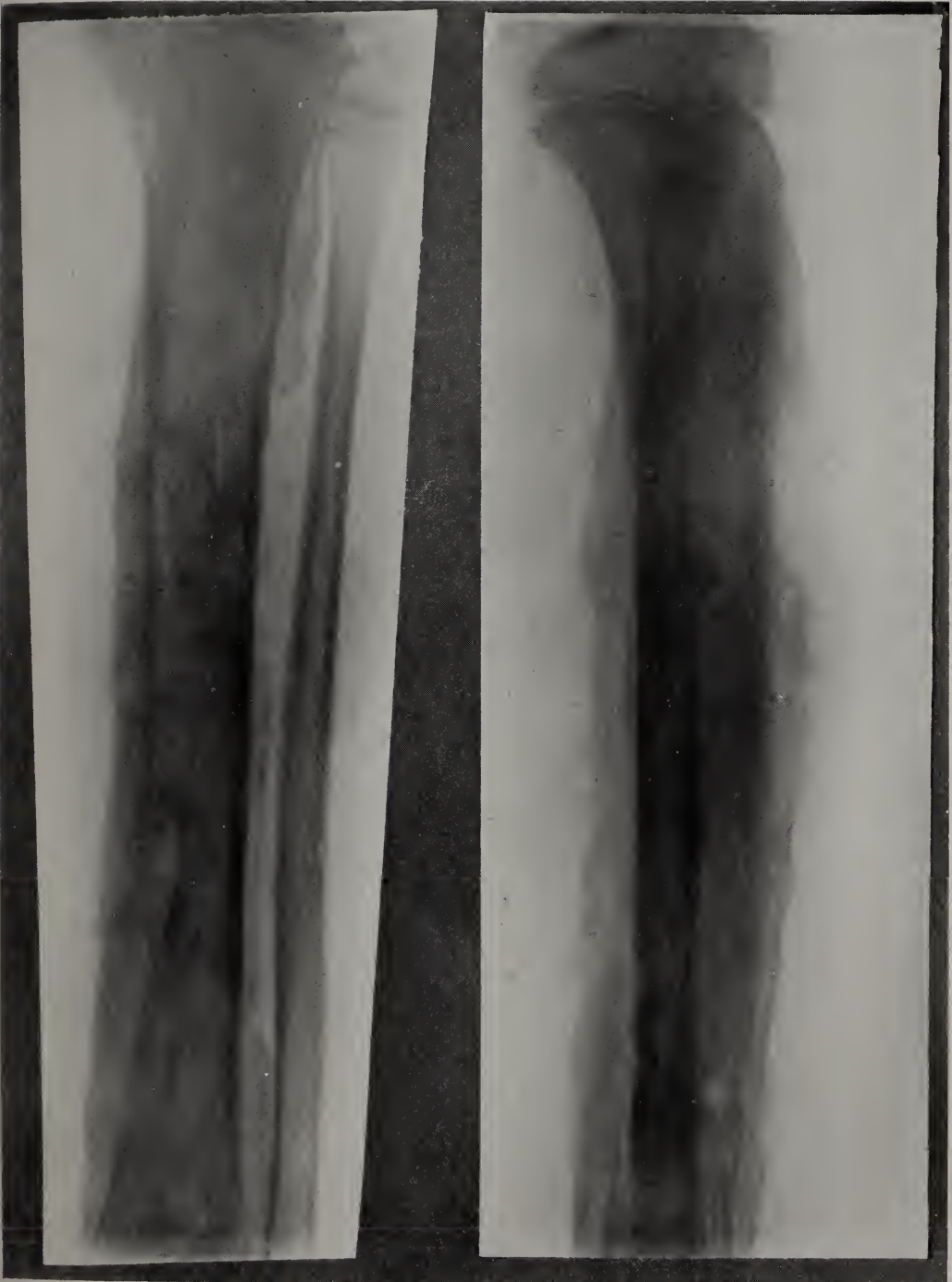

Fig. 2.

Case 12. Tuberculous Osteomyelitis of Shaft of Tibia. Marked atrophy of both bones. Periosteum thickened and infiltrated throughout. Numerous small areas of necrosis. Epiphyses normal.





*Roentgen examination:* Marked atrophy of both bones. Periosteum thickened and irregularly infiltrated in places, but mostly well-marked throughout. Periosteum generally thickened, mostly on the internal and posterior borders. Bone "spotty" throughout. Epiphyses normal.

It may be argued in the above cases that the condition present in the diaphyseal type is not due entirely to the tubercle bacillus, but is the result of secondary infection. As against this, it may be said that the cultures from the pus showed no organisms, which is consistent with tuberculosis, and also careful pathological examination of the tissue showed only a tuberculous process.

*Conclusions:*

1. Bone tuberculosis, when typical, is not difficult to diagnose in the Roentgen plate, especially when the clinical examination goes hand in hand with it.

2. Bone tuberculosis in its atypical forms may resemble Roentgenologically infectious osteomyelitis, syphilis, bone cyst as well as other forms of bone disease.

3. The Roentgen plate gives no idea of the extent of the disease, except in a general way, and a serious bone lesion may be present with a negative Roentgen finding, except for bone atrophy.

4. Tuberculosis of the shaft is occasionally found, and when present closely resembles infectious osteomyelitis and syphilis.

REFERENCES.

<sup>1</sup>Freiberg, A. H.: International Clinics, Vol., IV., Fifteenth Series.

<sup>2</sup>Feiss, H. O.: Jour. of Medical Research, 1904, XI., 431.

<sup>3</sup>Stiles, H. J.: Jour. Amer. Med. Assn., 1912, LVIII., 527-534.

<sup>4</sup>Murphy, J. B.: Jour. Amer. Med. Assn., 1912, LVIII., 1096.

<sup>5</sup>Küttner: Beit. z. klin. Chir., Bd. XXIV., Heft 2.

THE ROENTGEN RAYS IN THE DIAGNOSIS OF  
GASTRIC AND DUODENAL ULCER.\*

BY GEORGE E. PFAHLER, M. D., PHILADELPHIA, PA.

In the development of the diagnosis of Gastric and Duodenal Ulcer by means of the Roentgen Rays, we owe most to Haudek, whose extensive experience, careful observation and conservative conclusions, have established this as a valuable method of diagnosis. Most valuable, similar and confirmatory observations have also been made by Faulhaber, Rieder, Tornay, Holzknrecht, Jonas, Groedel, Stierlin, Reiche, DeQuervaine and others.

The Roentgenological evidence of gastric ulcer may be grouped under three headings as follows:

1. The *evidence of perforation*.
  - a. A projecting shadow outside of the gastric shadow.
  - b. A gas bubble lying above this collection of bismuth.
  - c. Perigastric adhesions or involvement of other organs.
  - d. A palpable tumor connected with the stomach, but not affecting the lumen.
  - e. The above may be associated with either an organic or spasmodic hour-glass contraction of the stomach.
  - f. Retention of bismuth in the ulcer after the remainder of the stomach has been emptied.
  - g. Resistance corresponding to the projecting shadow.
2. The evidences of irritation due either to a *florid* ulcer, or to an irritable scar of an ulcer.
  - a. Spasmodic contraction.
  - b. Retention of food in the stomach beyond six hours.
  - c. Painful pressure point corresponding to the location of the ulcer.
  - d. Normal outline of the stomach.
3. Secondary effects usually associated with a callous ulcer.
  - a. Pyloric stenosis and gastrectasis.
  - b. Fixation.
  - c. Organic contraction—hour glass.

\*Read by invitation before the Philadelphia Clinical Association, Nov. 4th, 1912, in a symposium on Gastric and Duodenal Ulcer, with the demonstration of lantern slides from 20 cases that were confirmed by operation, and 20 other cases with typical evidence but not operated upon.

- d. Interference with peristalsis.
- e. Reversed peristalsis.
- f. A contracted lesser curvature with retraction of the pylorus toward the left.

*The Penetrating Gastric Ulcer* is the only one that can be demonstrated directly, and the evidence will depend upon, and vary with, the degree, or extent of penetration.

1. The projecting bismuth shadow outside the normal stomach shadow, may be no larger than the tip of the little finger, or may be several inches in length and an inch or more in width. It has been most often found on the lesser curvature in the body of the stomach. It may occupy the posterior wall, or anterior wall, in which instance it can only be observed by careful oblique illumination; and its location can be determined by the degree of projection during rotation. This projecting shadow cannot be easily moved, though that will depend upon its location and depth.

2. A collection of gas lying above the projecting shadow of bismuth has been noted by Haudek and others. This will depend upon the extent and direction of the penetrating ulcer. If upward and extensive, it is likely to be found. If downward posteriorly or slight, it is not likely to be found. In one case of mine it was found above the liver and under the diaphragm.

3. Perigastric adhesions form in nature's attempt to wall off the ulcer. This will distort the stomach; will interfere with the peristaltic waves over part of the stomach, and is likely to change the position of the stomach. They are likely to render the stomach partially, or completely, immobile. They are most likely to involve the pancreas, the splenic flexure of the colon, or the under surface of the liver and hepatic flexure of the colon.

4. A palpable tumor may at times result, due to the perforation and formation of fibrous tissue resulting from the secondary inflammation. If this is connected with the stomach, but does not encroach upon the lumen, it is evidence pointing more to an old perforating gastric ulcer, than to carcinoma.

5. Hour-glass contraction of the stomach is commonly associated with a perforating gastric ulcer. It most often affects the greater curvature, and may be spasmodic or may be due to adhesions; or may be partially organic and partially spasmodic. This hour-glass contraction may affect any part of the stomach, but is most often found in the lesser curvature. If this constriction is associated with fixation it is most likely to be organic.

6. Retention of bismuth in the bed of the ulcer after the stomach is empty, may occur even when no projecting shadow is present. This is true when the ulcer is on the anterior or posterior wall. A plate of this character has been demonstrated to me by Bassler of New York. This cannot be expected often and must be interpreted very carefully. I believe that ulcer cannot be directly shown excepting perforation to a considerable degree has taken place. In one case studied by myself, such a deposit was recognized, but no evidence of ulcer was found at operation. The operation was undertaken on account of adhesions of the bowels, but the stomach was explored. In no case should such retention be interpreted as ulcer unless it is accompanied by other confirmatory symptoms and Roentgenological evidence.

7. Resistance corresponding to the location of the projecting shadow will furnish confirmatory evidence.

*Florid Ulcer*, or an irritable scar following an ulcer, gives rise to certain sensory and reflex or spasmodic symptoms that can be demonstrated roentgenologically.

1. Spasmodic hour-glass contractions commonly occur in connection with acute or irritable ulcers, even though there be no perforation, projecting shadow, nor retention of bismuth in the bed of the ulcer. These spasmodic hour-glass contractions have been most thoroughly reviewed by Stierlin, and according to him were recognized even by the old anatomists—Home 1818, Tiedemann and Gmelin 1836; Büdinger in 1901 at operation saw a spasm of the circular fibres of the stomach at the location of an old scar. Jonas in 1906 saw a spasmodic hour-glass contraction of the stomach which was not present at a second examination. In 1908 I observed a case in which an hour-glass contraction persisted and with no change and no peristaltic waves during at least an hour and a half while under observation. In this instance the contraction occupied the middle of the body of the stomach, involved both the lesser and greater curvatures, and was unusually wide. In fact, the whole stomach was contracted, and as I interpret it, was in a tetanic contraction. This was associated with numerous indentations such as are seen in carcinoma, and a diagnosis of carcinoma was made. At operation, by Dr. Laplace, only a small ulcer was found on the lesser curvature, and otherwise the stomach was normal. Observations upon these hour-glass contractions have been made by Jolasse, Haudek, Faulhaber, Schmitt, Rieder, Holzknicht, Stierlin, and others.



In general the contraction occurs opposite to the location of the ulcer, and usually only affects the greater curvature. The indentation may only be a half inch in width and may completely bisect the stomach; or may be only a half inch in depth. Often the walls of the stomach at the point of indentation, are quite smooth, and give the appearance of a string drawing the greater curve upward. At other times the indentation is wide and the walls irregular. It may be present only occasionally, or may be found of the same character at repeated examinations. It is much more likely to vary in character and extent than an organic constriction. It is excited by the presence of food.

I have seen a similar hour-glass constriction in a case of tabes, in which instance the contraction occurred during the gastric crises. I also saw a complete hour-glass constriction at the junction of the middle and lower third of the stomach in a physician who suffered from attacks of renal colic (movable kidney), and who had *no* stomach symptoms at any time, and who had *no* symptoms nor abnormal sensations at the time of these contractions. They occurred only at intervals, lasted about twenty minutes and then disappeared completely. Stierlin also reports a spasmodic hour-glass contraction observed in a case of tabes. He also publishes a picture of a case observed by Staehelin in which a similar hour-glass contraction occurred in a case of cirrhosis of the liver, (controlled by operation). As a rule, however, these spasmodic hour-glass stomachs occur with gastric ulcer. Those not due to gastric ulcer are apt to be less constant in their picture and of course, are not associated with the other evidence of gastric ulcer. Multiple deep spasmodic constrictions, affecting both curvatures, may occur in neurotic subjects, as observed by Stierlin, as well as myself.

2. *Retention of food in the stomach beyond six hours* if not accompanied by tumor formation or in an otherwise normal stomach, is one of our most valuable signs of acute or florid ulcer. Ashbury, at the meeting of the American Roentgen Ray Society, in 1910, in his report had recognized this retention of large quantities of bismuth in the stomach in gastric ulcer, and demonstrated them in lantern slides, but unfortunately he interpreted it as being retained in the bed of the ulcers. It was after one of these demonstrations before the American Gastro-Enterological Society that I called attention to the fact that this must be the result of spasm of the pylorus.

The real credit of the recognition and elaboration of this valuable evidence belongs to Haudek and Holzknecht. It is an accepted fact that the passage of the acid chyme into the duodenum causes the normal closure of the pylorus, and that it re-opens when the acidity has been neutralized in the duodenum. With hyperacidity it is, therefore, reasonable that each period of closure of the pylorus will be longer, and as a result the passage of the food from the stomach will be delayed. Vice versa, if achylia or hypoacidity be present, the period of each closure of the pylorus will be decreased, and as a result, other things being equal, the stomach will empty itself more quickly than normal.

It is a generally accepted fact that no normal stomach, under normal conditions, will retain food beyond six hours, and the bismuth meal, which is usually given (Rieder Meal—Bismuth subcarbonate 40 grains; Milkbroth, 300 C. C., or Pfahler Meal—Bismuth subcarbonate, 1½ ounces, and fermalac or kefir, fermented milks, 12 oz.) under normal conditions leaves the stomach within four hours.

This spasmodic retention of the bismuth meal beyond six hours, has been found when the ulcer is located high as well as low. Holzknecht believes this may be due to a dragging of the ulcer on the pylorus, or due to hyperacidity. This evidence is best elicited by giving the patient the bismuth meal on an empty stomach, and examining the outline of the stomach, its position, peristaltic movements, lumen, mobility, localized tenderness, etc., and then examining the patient again at the end of six hours for any retention. If the patient has not been seen after the first meal, he should now be given a second; or if the observations at the first examination have not been entirely satisfactory, it can now be repeated. Retention of food beyond six hours rarely occurs in marked gastroptosis without ulcer.

3. Painful Pressure Point may at times be located. If this is found to lie over the stomach, and to move with the stomach shadow, it points toward gastric ulcer. This was pointed out by Crane, as well as Haudek and others. By this I mean that one may find a painful point corresponding, for example, to the lesser curvature. This changes its position from the recumbent to the standing posture, and even with deep respiration.

4. A *Normal Stomach Outline*, and even normal peristaltic waves, may be present in acute gastric ulcers, and yet the retention of food associated with such normal stomach shadow

would point strongly toward acute ulcers, especially if associated with hyperacidity and occult blood in the stool.

A *Callous Ulcer* is usually recognized by its secondary effects, which are as follows:

1. Pyloric stenosis is commonly due to a contraction resulting from a callous ulcer. In fact, in most instances it is due to an old ulcer rather than to carcinoma, though the ulcer may at any time undergo malignant changes. Because of the obstruction at the pylorus, there is associated a progressive dilatation of the stomach. This is recognized by its size, and by the retention of food. This may be six hours, or may be ten days, as occurred in two patients of mine. This retention of bismuth food gives a characteristic basin-like shadow at the lower pole of the stomach, with often no other evidence of the stomach.

2. Reversed peristalsis occurs in connection with pyloric stenosis—more often with the organic stenosis, but may be seen in spasmodic stenosis of the pylorus. The waves of reversed peristalsis are of the same character as the direct.

3. Increased peristaltic waves in connection with pyloric stenosis, show not only greater depth, but are actually increased in the number that pass at any one time. It is common to see five or six, instead of the usual number, three. There are usually long intervals during which no waves pass.

4. Adhesions and fixation may occur in connection with a callous ulcer, though they are much more likely in perforating ulcer. When present, the stomach cannot be moved about as it can be under normal conditions. These same adhesions may distort or displace the stomach.

5. Organic contraction of the stomach may affect only a small area, usually on the lesser curvature, or may cause an hour-glass contraction. So too, the hour-glass contraction may be due in part to the organic contraction, and in part to spasmodic contraction.

6. Retraction of the pylorus toward the left is at times formed, and is likely due to the contraction of the lesser curvature caused by the disease.

7. Interference with the peristaltic waves will practically always be found when the ulcer is indurated. A wave may be seen on both curvatures, then be interrupted at the location of the ulcer usually on the lesser, while at the same time it may be seen to continue on the greater curvature.



### Duodenal Ulcer.

The evidence of duodenal ulcer as shown by the Roentgen Rays, is in a developmental stage and while important, it is of less definite value than that obtained in gastric ulcer.

1. A Normal Stomach Shadow is found unless some other complication be present.

2. *Increased Peristalsis* has been observed. Barclay considers it evidence of duodenal ulcer whenever he finds a normal stomach shadow associated with excessive peristalsis, carrying the food out of the stomach more rapidly than normal. He has even observed that the stomach may empty itself within a half hour in these cases. Haudek on the other hand says that the time of emptying of the stomach is only slightly increased, so that at the end of six hours only slight remnants can be found.

Haudek also says that not infrequently a bismuth in water mixture passes through the pylorus immediately after taking, either spontaneously or by effleurage, which is in contrast to pyloric ulcer.

3. A *Normal Pylorus* is likely to be found in duodenal ulcer. By this I mean of normal width and thickness, as indicated by the clear space between the bismuth shadow in the stomach and that in the duodenum.

4. A *Painful Pressure* point may be found over the duodenum, and it should move upward with the drawing in of the abdomen. (Haudek.)

5. Resistance at the same location as the painful point, is evidence of a callous ulcer.

6. A *Remnant* of bismuth outside of the duodenal outline, associated with resistance, and not easily movable, points toward a penetrating duodenal ulcer.

7. *Constrictions* and secondary dilatations may result from the contraction of a callous duodenal ulcer, but similar effects may be produced by other forms of adhesions, and therefore this evidence must only be considered confirmatory.

8. *Occult* blood in the stool in association with the above evidence, would point toward an acute ulcer.

A very clever method of artificially distending the duodenum has been developed by Cole. It consists in allowing the patient to swallow an Einhorn duodenal tube. Near the metallic head of this tube is attached to a very thin rubber bag, which is distended at will with air forced through the tube. This blocks the duo-



denum and allows the part above it to be filled with bismuth food. Theoretically this would seem to meet a desired end, but practically there are a number of objections.

1st. It produces a sudden obstruction of the intestine, which at once will change the usual or normal action of the duodenum, and I would expect reversed peristalsis, spasmodic contraction, or blocking of collections of gas as well as food, all of which would be apt to lead to erroneous conclusions.

2nd. There is danger of traumatism more during the extraction of the tube than during its passage, especially when ulcer or carcinoma, or even dilated veins are present. However, it is a clever idea, and may be found useful in certain cases.

By a private communication, Cole says: "In regard to the Artificial Duodenal Dilatation I believe that this is of use in selected cases, particularly those in which one is anxious to determine the lumen of the second and third portions of the duodenum, rather than the cap. In such cases it is of real practical value. But I do not believe that it would be wise to attempt to use it as a routine procedure, because I believe that the irritation of the tube in the duodenum somewhat distorts, or causes a spasm of the pyloric sphincter.

### Conclusions.

1. Gastric ulcer gives very positive evidence as shown by the Roentgen Rays.
2. In many instances the character and location of the ulcer can be determined.
3. The location and character of the ulcer will give a very definite idea as to the treatment; and when surgical, the character of the operation can be more definitely decided upon—whether a gastro-enterostomy, pylorictomy or local excision. If a gastro-enterostomy is decided upon the lowest point of the stomach can be determined by the rays and thus obtain the best drainage.
4. Some evidence of duodenal ulcer can be found.
5. The history, and other clinical evidence should not be neglected to arrive at an accurate diagnosis.

### REFERENCES AND LITERATURE.

- ASBURY: "X-Ray findings in Gastric and Duodenal Ulcer." *The American Quarterly of Roentgenology*. December, 1911.
- BARCLAY: "Archive of the Roentgen Rays, 1910-XV-P-174."

BECKEY: Kontraktionsphänomene des Magens und ihre Beziehungen zur Pathologie."

Frankf. Zeitschr. f. Pathologie, Bd 7, H. 3. 1911.

BUDINGER: "Zur Pathologie und Therapie des Sanduhrmagens." Wiener klin. Wochenschrift 1901, No. 36.

COLE: Artificial Dilatation of the Duodenum for Radiographic Examination. Am. Quarterly of Roentgenology, Dec. 1911.

DEQUERVAIN: "Zur Roentgendiagnostik des runden Magengeschwürs." Münch. med. Wochenschr, No. 17th, 1911.

FAULHABER: "Zur Roentgendiagnostik des tiefgreifenden Ulcus ventriculi." Münch. med. Wochenschr, No. 40, 1910.

FAULHABER: "Die radiologische Untersuchung des Magens." Archiv. f. phys. Med. in med. Technik, III, u IV.

FAULHABER: "Zur Röntgendiagnostik des tiefgreifenden (kälösen) Ulcus ventriculi." Münch. med. Wochenschr, 4, Oct. 1910.

GROEDEL: "Die Röntgenologisch nachweisbare Merkmale der gastrektase und der Pyloroptose." Berliner klin. Wochenschr, No. 15, 1908.

HAUDEK: "Die Röntgendiagnose des kallösen (penetrierender) Magen Geschwürs und ihre Bedeutung." Münch. med. Wochenschr. No. 47, 1910.

HAUDEK: "Zur Röntgenologischen Diagnose der Ulceration in der Pars media des Magens." Münch. med. Wochenschr, No. 30, 1910.

HAUDEK: "Radiologische Beiträge zur Diagnostik des Ulcus und Carcinoma ventriculi." Münch. med. Wochenschr, No. 8, 1911.

HAUDEK UND CLAIRMONT: "Die Bedeutung der Magenradiologie für die Chirurgie Verlag von Gustav Fischer." Jena., 1911.

HAUDEK: "Die Diagnose des Ulcus duodeni in Roentgenbilde und seine Unterscheidung von Ulcus Pyloricus."

HOLZKNECHT UND JONAS: "Die Röntgenuntersuchung des Magens und ihre diagnostische Ergebnisse." Ergebnisse der inneren Med. und Kinderheilkunde. Bd. IV, 1910.

HOLZKNECHT: "Archives of the Roentgen Ray, November 1911."

JOLASSE: "Beitrag zur Röntgendiagnose des Sandenlermagens." Festscher, a. d. Geb. d. Röntgenstrahlen, XI.

JONAS: "Zur Differentialdiagnose des ulcus ventriculi." Die radiologische Teststellung der Zugehörigkeit druck und schmerzhafter Punkte des abdomens zu den inneren Organen 25 Kongress, für innere Medizin, 1908.

JONAS: "Zur Pathologie und Diagnostik des spastischen Sandenlermagens." Wiener klin. Rundschau, 47-48, 1909.

REICHE: "Die Röntgendiagnose des penetrierenden Magengeschwürs." Münch. med. Wochenschr, Jan. 3, 1911.

RIEDER: "Die chronische Magengeschwür und sein Roentgenologischer Nachweis." Münch. med. Wochenschr No. 48, 1910.

SCHMITT: "Zur Diagnose des Sandenlermagens." Archiv f. klin. Chir, 81, 1906.

SCHWARTZ: "Ein Fall von narbiger Pylorostenose mit Roentgenbefunde." Wiener klin. Wochenschr, 1910, No. 10.

STIERLIN: "Roentgenologische Erfahrungen über Magenopasmen."

TORNAY: "Beiträge zur Roentgen-diagnostik der Stenosen des Verdauungstraktes." Berliner klin. Wochenschr No. 29, 1910.

Verhandlungen d. Deutsche Ges. f. Chirurgie,  
1912, 40, P, 192

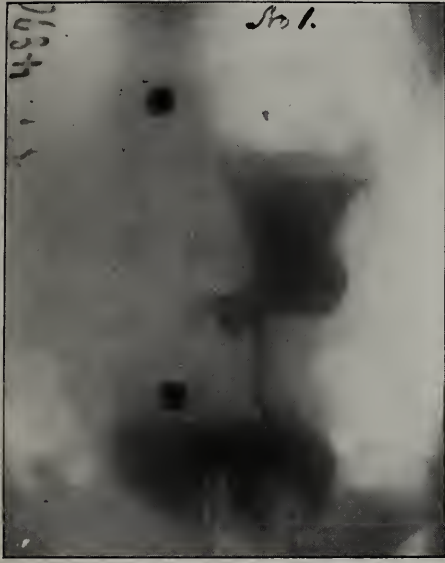

Fig. 1. Perforating gastric ulcer, with hour-glass contractions, and pyloric stenosis (due to adhesions). The arrow points to the abrupt termination of the perforation. Confirmed by operation by Prof. Rodman.



Fig. 2. Tetanic hour-glass contraction of the stomach due to small ulcer on the lesser curvature, studied and confirmed at operation by Prof. Laplace 4 years ago.

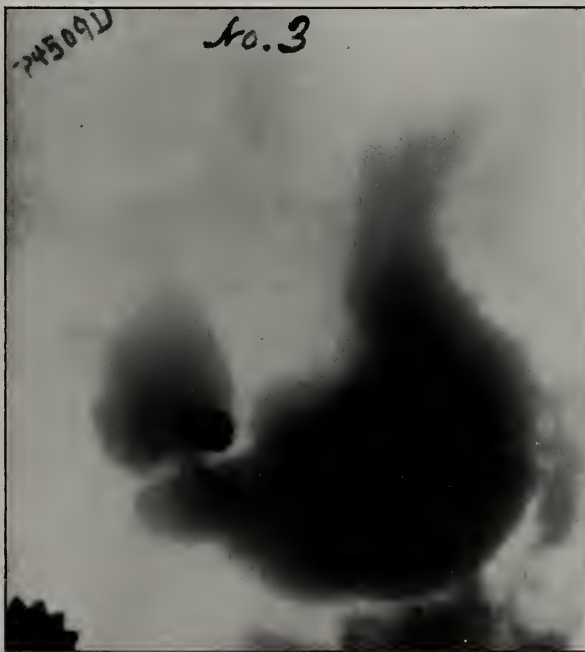


Fig. 3. Indurated gastric ulcer on the lesser curvature, which persisted during two hours of careful study. Spasmotic contraction on the opposite curvature. Double lines show peristaltic movement of the greater curvature, and partial obliteration of the indentation on the greater curvature. See sharp lines on border of indentation on the lesser curvature.







Fig. 4. Spasmodic hour-glass contraction in the body of the stomach due to ulcer on the lesser curvature. Confirmed at operation by Dr. W. Hershey Thomas.

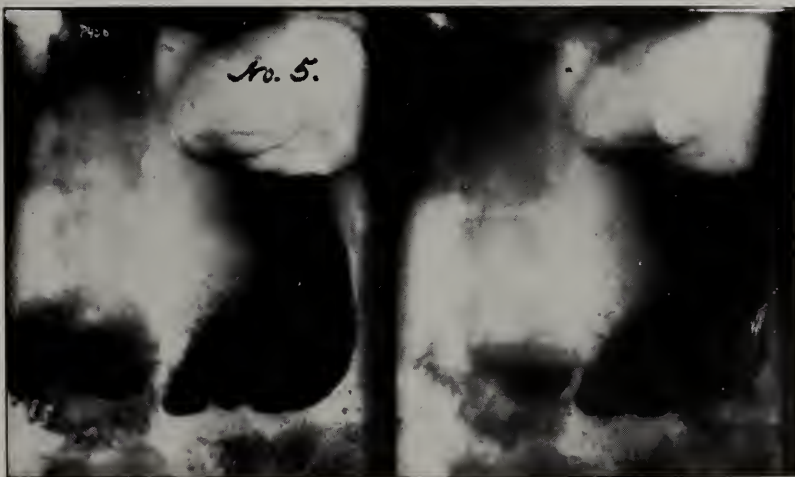

Fig. 5. Spasmodic hour-glass contraction in the lower third of the stomach, which persisted twenty minutes at a time, associated with a movable right kidney, in a physician who was subject to attacks of renal colic. Patient had no stomach symptoms.





Fig. 6. Sharp indentation on the greater curvature, probably spasmodic. Evidence of duodenal adhesions. Patient had the symptoms and history of gastric ulcer.

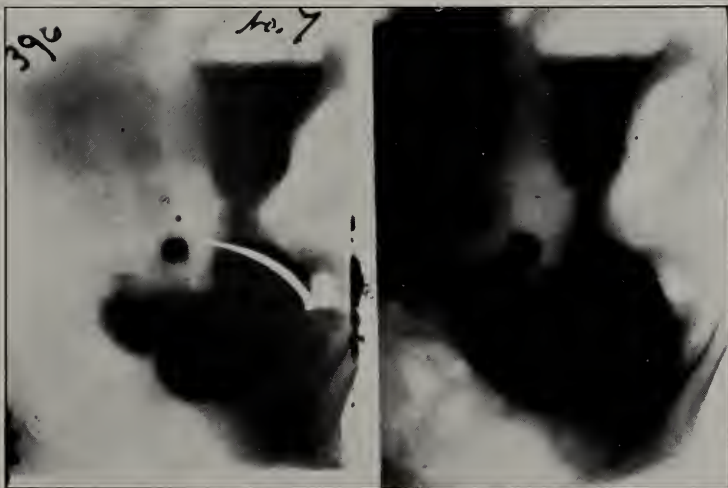


Fig. 7. Spasmodic hour-glass contraction due to ulcer on the lesser curvature. Confirmed at operation by Prof. Laplace. (White mark is an accident to the lantern slide.)





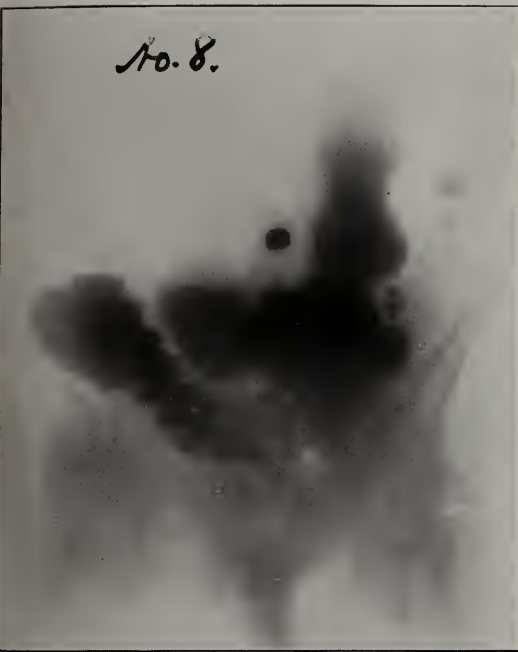

Fig. 8. Shows the same stomach as in Fig. 7, but with no hour-glass contraction. Instead there are strong peristaltic waves attempting to overcome the pyloro-spasm.

Fig. 9. Hour-glass contraction of the stomach near the pylorus, due in part to adhesions, and in part to spasm, but caused by a gastric ulcer. Confirmed at operation by Dr. Gibbon.




Fig. 10. Spasmodic contraction of the pyloric end of the stomach, due to ulcer. Typical symptoms of gastric ulcer, studied by Dr. Eberhard.

Note—These illustrations were copied from lantern slides because the original negatives had been sent out.



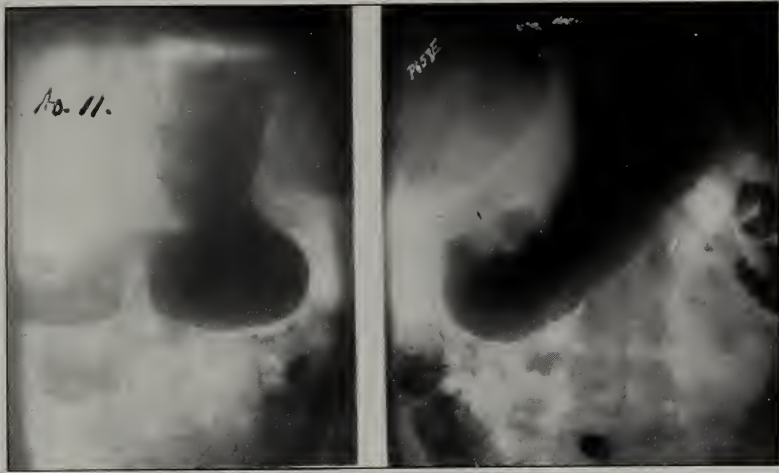


Fig. 11. Hour-glass contraction of the pyloric end, due to ulcer. The second picture shows the absence of this contraction. Studied clinically by Drs. Mallon and Allyn.



Fig. 12. Pyloric stenosis, due to old callous ulcer. Gastrectasis, confirmed at operation by Dr. Kennedy.

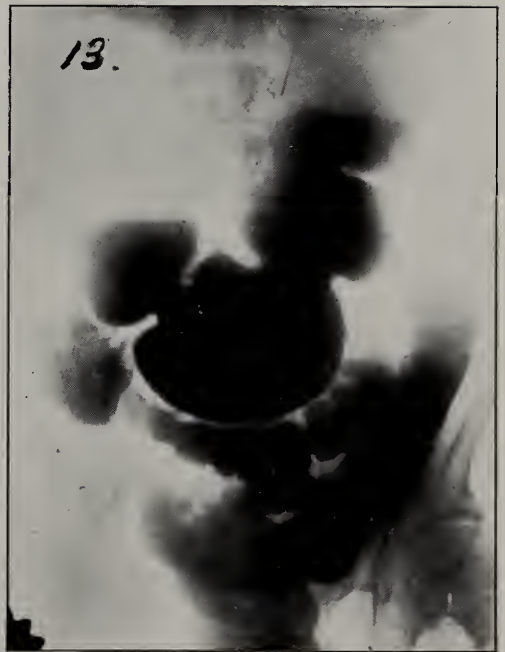

Fig. 13. Same case as in Fig. 12, showing the deep peristaltic waves found in pyloric stenosis.





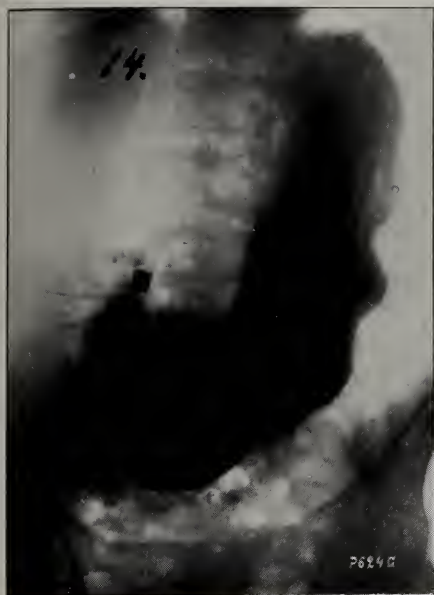

Fig. 14. Pyloric stenosis, due to old callous ulcer, showing gastrectasis and large number of peristaltic waves. Confirmed by Dr. Kennedy.



Fig. 15. Duodenal dilatation, due to adhesions, secondary to duodenal ulcer. Dr. Chew.




Fig. 16. Duodenal dilatation, due to adhesions, secondary to a pericholecystitis. See gallstones. Confirmed by Prof. Rodman.



THE X-RAY STUDY OF 22 CASES OF PTOSIS OF THE  
STOMACH AND COLON BEFORE AND  
AFTER OPERATION.

BY MAX KAHN, M. D.

These cases have previously been reported by Dr. Bloodgood before the Gastro-Enterological Association in Atlantic City, June 3, 1912 (*The American Jour. of Gastro-Enterology*, July, 1912, ii, p. 11). At that time twenty cases operated upon were discussed. Since then two more operative cases have been observed. These cases were divided by Bloodgood into five groups:

**Group 1.** Four cases.—The anatomical findings at operation in these four cases were: A stomach in ptosis, greatly dilated with a distinct kink at the pylorus, and a ptosis of the right half of the colon; the cecum was usually in the pelvis, the hepatic flexure down, a redundant transverse colon, the right half resting parallel with the ascending colon. Clinically, in these cases there were the same gastric symptoms as in any cases of pyloric stenosis, and gastric residuum as shown by the stomach tube. In addition there was marked constipation with all the symptoms of colonic intoxication.

The X-rays before operation as shown in No. 4221 (Cullen) shows a stomach with the lesser curvature lower than the umbilicus, the greater curvature usually below the pubes, and, in addition to ptosis, great dilatation of the stomach. The bismuth was as a rule not expelled before four to six hours, sometimes longer. The position of the right half of the colon as found at operation was well shown in the X-ray. As a rule the bismuth was not expelled from the right half of the colon until after 48 hours. It, however, passed rapidly through the remaining portion of the left colon. There was no marked ptosis nor dilatation of the sigmoid. In one case only (Cullen) the splenic flexure pulled down. In three of these four cases the operation consisted of a resection of the stomach with anastomosis between the duodenum and the remaining portion of the stomach at the position of the greater curvature, and resection of the right half of the colon with anastomosis between the ileum and the

transverse colon. The inverted closed end of the transverse colon was fixed to the upper angle of the right rectus wound. This acted as an apron to hold the stomach up and straightened out the colon to the splenic flexure.

The X-rays after operation in these cases (see Cullen) show a stomach in correct position, usually emptying itself within three hours. In none of these cases did the bismuth remain in the duodenum. We find no shadow of the duodenum before, nor after operation. The X-rays also show the absence of the right half of the colon, the bismuth passes so quickly into the transverse colon that the anastomosis can be made out in only two cases. The plates show the transverse colon fixed in its new position and the remainder of the colon as before operation. Clinically, these patients have been relieved. In the fourth case, in which only the stomach was resected, the X-ray after operation (Cullen) shows the stomach in good position, but the right half of the colon still in ptosis. As this patient still suffered from his colonic stasis the right half of the colon was resected. The X-ray now shows (Cullen, to be made) the colon as in the other three cases. This patient is now relieved of all his gastric and colonic symptoms.

**Group 2.** Chronic Gastromesenteric Ileus with Ptosis of the Right Half of the Colon.—In the first report by Bloodgood there were but five cases, one other case has been observed since then. This one, from the X-ray standpoint is the most interesting, because in the X-ray three and four hours after bismuth by mouth the complete "U" of the dilated duodenum is shown.

In these six cases the anatomical findings at operation were: Extreme ptosis of the right half of the colon, an unusually dilated cecum in the pelvis, an ileum with a short mesentery. This allowed the huge cecum to pull on the mesentery of the small intestine and constrict the duodenum as it passed through the root of the mesentery between the mesenteric vessels.

In only one of these six cases was the stomach dilated to the extent observed in Group 1. In this case the stomach was resected as in Group 1. (Johnson 4084). We have no X-rays of this patient before operation.

In the remaining five cases the degree of ptosis and dilatation of the stomach was distinctly less than in Group 1. From an X-ray standpoint the most important finding is the dilatation of the duodenum which we fortunately got in our last case



(Rabinowitz). I am confident that if the X-ray pictures are taken every hour after the first two hours, the probabilities are that this dilatation of the duodenum will be shown. The colon in these cases differs very little from that in Group 1.

The X-ray after operation in the five cases in which the stomach was not resected shows that much of the ptosis of the stomach has been corrected, that the stomach empties itself more quickly (Harter, 3982) and so far we have been unable to see that any bismuth has been retained in the duodenum. The X-ray in the case in which the stomach was resected with a Kocher anastomosis, shows a result similar to those in Group 1. (Johnson 4084). The X-ray of the colon after operation in this group does not differ from that in Group 1. In some of the cases the anastomosis between the ileum and transverse colon is shown (Johnson, Harter).

**Group 3.** Ptosis of the Right Half of the Colon. Five cases, reported by Bloodgood and one observed since. (Bouffer). In these cases the stomach before operation is practically normal as pictured in the X-ray. A few show some ptosis and slight dilatation. In none of these cases was the bismuth retained in the duodenum. The X-rays show a marked ptosis of the right half of the colon with dilatation, kinks, and a cecum, usually in the pelvis. In these cases the bismuth remained in the cecum very long, in one case 190 hours (Wall 4107). (The X-rays were taken at St. Joseph's Hospital by Dr. Ashbury).

In these cases the right half of the colon only was resected, and the X-rays show the anastomosis and the corrected position of the transverse colon. (Sister Theresa 3859). In one of these cases there is a marked dilatation, elongation and ptosis of the sigmoid colon shown in the X-ray before operation, seen at operation, and again pictured in the X-ray after operation (Sister Theresa). This patient is the only one in this group who has not been relieved.

**Group 4.** Pericolitis—three cases. The X-ray before operation shows a practically normal stomach (Sodeski 4184). There is no ptosis of the right colon, but the ascending colon is parallel with the first portion of the transverse. The cecum in two cases was hugely dilated. In the X-ray shadow the stomach convolutions due to the contraction of the circular muscle is absent and there is a blurring of the entire X-ray shadow. The right half of the colon empties itself of the bis-

muth very slowly. The X-ray in two cases after operation (Sodeski 4184 and McDonald 4113) show the absence of the right colon, the anastomosis, the corrected position of the transverse colon, but in one case (McDonald) it shows a very elongated and dilated sigmoid colon, which was later resected with lateral anastomosis.

In this group only the right half of the colon was resected. In one case this was followed later by resection of the sigmoid as just noted.

**Group 5.** The anatomical findings in three cases here shows the redundant sigmoid with mesenteritis producing an obstruction between the descending colon and the first portion of the sigmoid. The X-ray before operation (Elliott 4068 taken by Dr. Ashbury at St. Joseph's Hospital) (Gurley and Forrest, taken by Dr. Baetjer at Johns Hopkins) shows that the bismuth stopped in the lower end of the descending colon, when given by mouth. When the bismuth is injected per rectum it fills the sigmoid, lifts it out of the pelvis, corrects the kink and the bismuth passes and fills the entire colon. In these three cases the descending colon and sigmoid were mobilized and a lateral anastomosis made between the descending colon and the lower sigmoid: the redundant colon was excised.

The X-ray after operation (Gurley) shows that the obstruction is completely relieved.

The X-ray, therefore, will portray pretty clearly the position of the stomach and colon. In group 2 it may show the dilatation of the duodenum. It shows not only the relative size and position, but if X-rays were taken at intervals after bismuth is given by mouth, they will give a good indication of the motoric function of the stomach and colon. As a rule in pericolicitis the shadow is changed and the point of greatest dilatation of the colon will be brought out and sometimes kinks. To obtain an accurate picture of the sigmoid colon one must have X-rays after bismuth by mouth and after bismuth injected per rectum. For the right half of the colon the method of bismuth by mouth seems better.

After operation the X-ray studies demonstrate whether the anatomical conditions have been corrected. The more rapid evacuation of the stomach and colon is well shown.

One cannot make an accurate diagnosis from X-ray studies only, for frequently we see ptosis of both stomach and colon

without symptoms and without stasis. The surgeon, however, should, before operation, know exactly the symptoms complained of. Then, with the X-ray plates and his inspection on opening the abdomen he will be better prepared to relieve the symptoms. There, is however, much to be done in the X-ray investigation of cases before operation. In the stomach there should be more frequent pictures to ascertain the exact time of complete evacuation which is more important than the position of the stomach. If the duodenum retains the bismuth, it may be looked upon as good evidence of gastro-mesenteric ileus. The same is true to the colon. We want to know the time of complete emptying of the different parts of the colon. For this reason it seems advisable that in addition to making plates frequent fluoroscopic examinations be made if this can be done without danger to the patient and operator.

The technic employed was as follows: Each patient was prepared by purging the night before, or an enema given on the morning of examination, and a glass of milk given for breakfast. Immediately before examination the patient was given to drink an ounce of bismuth subcarbonate suspended in about 10 oz. of milk; then while in the erect position she was bent forward and backward and from side to side two or three times so that the bismuth would be equally distributed in the stomach. The patient was then placed in the prone position, the anode of the tube focused over the spine of the second lumbar vertebra at a distance of nineteen inches, and the patient instructed to hold her breath at the end of a deep inspiration at the count of three, when the radiograph was taken. In the cases where the rectal injection was given the patient was prepared in a similar manner. She was placed in the left lateral position and the hips elevated by means of two or three pillows at an angle of about 35 degrees. An ounce of bismuth subcarbonate was then suspended in 16 oz. milk and by means of a high rectal tube well lubricated inserted through the rectum for a distance of 18 to 20 inches, the bismuth suspension was gradually poured through a funnel. The patient was kept in this position for 30 minutes at the end of which time she was placed in the prone position, and a radiograph taken. The advantages of the rectal injection are that the outline of the colon and sigmoid can usually be obtained with one radiograph, thus economizing in the number of plates used, and the saving of time. In cases where bismuth

is given by mouth a picture of the colon can frequently be obtained at the end of twenty-four hours. In a considerable number of cases, however, it has either not reached the colon at this time, or has already passed out, so that it may be missed altogether. By means of the rectal injection this is advised. In those cases where it is desired to estimate the position of the stomach in relation to the colon the bismuth can be given by mouth first and a radiograph taken immediately, and then the rectal injection given for the colon, and another radiograph taken. Atony or hypermotility of the stomach can further be diagnosed by successive radiographs taken every 2 hours, and atony of the colon by radiographs taken every 24 hours.



## EDITORIAL

---

The attention of the members of the society is especially called to the notice elsewhere of a proposed trip to attend the International Congress of Surgeons in London. The section on Radiology will undoubtedly be productive of good results and will be of great interest to those who can attend. The trip of the American members will serve to bring them closer together and to afford the opportunity not only of enjoying the work of the section but also of meeting many of their European confreres. This international exchange of ideas is certainly destined to raise the standard of American Roentgenology and to show our confreres across the water that we are striving to attain the highest type of excellence.

---

### PROPOSALS FOR MEMBERSHIP.

The following physicians have made formal application to become members of the American Roentgen Ray Society and they have filled the requirements of the Constitution of said Society relative to applications for membership:

Dr. Myron Botsford Palmer, 55 S. Fitzhugh St., Rochester, N. Y. Recommended by Dr. C. Wentworth Hoyt, 365 East Ave., Rochester, N. Y.; Dr. H. M. Imboden, 480 Park Ave., New York City.

Dr. Samuel Stern, 41 West 51st St., New York City, Recommended by Dr. W. H. Stewart, 14 West 126th St., New York City; Dr. Leopold Jaches, 27 East 95th St., New York City.

---

### EXTRACT FROM CONSTITUTION.

"Applications must be sent to the Chairman of the Executive Committee at least six months before the next meeting at which they are to be acted upon. He shall publish or cause to be published, the names and addresses of such applicants together with the names of the members proposing them, either in the 'QUARTERLY' or by a personal letter to each member of the Society, at least twice before the next meeting at which the names of applicants are to be acted upon. Any objections held by members against said applicants should be sent to the Chairman of the Executive Committee as soon as possible for filing."

A. F. HOLDING, M. D.,  
*Chairman of the Executive Committee.*

## ANNOUNCEMENT

The meeting of the Western members of the American Roentgen Ray Society will be held in Chicago on Feb. 22nd, 1913. The arrangements are in the hands of the local members, Dr. Hollis E. Potter and Dr. Case. An interesting program for the afternoon and evening meeting is certainly assured and those members of the society who will be able to attend will undoubtedly be amply repaid for the time.

These short informal meetings certainly tend to keep up the enthusiasm of the members and while not designed to at all replace the great event of the annual meeting will serve to stimulate the enthusiasm of the members and will be a distinct educational feature through the exchange of ideas and by the promotion of a free discussion.

### THE INTERNATIONAL CONGRESS OF SURGERY, 1913, LONDON.

Many of our members will this year go to the International Congress of Surgery, to be held in London, England, beginning August 7th. A Radiology Section under the Presidency of Sir James McKenzie Davidson promises to be of special interest. By way of making the crossing of the ocean more enjoyable it was proposed at the last annual meeting that members should travel by the same boat. The Teutonic, sailing July 26th, has been selected as one likely to suit the majority. She is 10,000 tons, and sails from Montreal. She is a one class boat, and the fare is \$55.00. Dr. Pirie of Montreal has arranged for a block of state-rooms to be reserved for the party, and those who wish to travel by this boat should secure their places as soon as possible. Berths should be secured from the White Star Line direct. Members who intend to go are requested to communicate with Dr. Pirie, Royal Victoria Hospital, Montreal, who will make further arrangements for visits to the X-ray departments of London hospitals. A short trip in Germany could be arranged on board the Teutonic.

Some preliminary arrangements have been made for a meeting of the members of the A. R. R. Society with the Roentgen Society of London. Members are referred to the notices which will appear in the *Lancet* and *British Medical Journal*, of papers to be read at the meeting, and of the social functions which will take place. Fuller details will be given in the next quarterly journal. Meanwhile please secure your places on the Teutonic.

A. W. P.

## CURRENT LITERATURE

Experiments on the Influence of Opium, Morphinum, Pantopon  
and Morphine-Free Pantopon Upon the  
Digestive Tract.

---

DR. J. K. SCHWENTER, BERN.

---

*Fortschritte auf dem Gebiete der Roentgenstrahlen, Vol. 19,  
page 1.*

The author first cites the experiments of Magnus and Padtberg with regard to the influence of cathartics on the gastrointestinal tract. Those of Magnus with infusum sennae show that this drug begins to have an effect only when it reaches the colon together with the meal, which must consist of meat, while castor oil excites the small intestine and retards the evacuation of the stomach; but rancid castor oil increases the emptying of the stomach:

Padtberg's observations on decoctum colocynthidis show that it influences mostly the small intestine, but its action on the stomach is very irregular.

It was found that all antiperistalsis of the proximal part of the large intestine was stopped by these drugs. Padtberg's experiments with magnesium sulphate dissolved in water showed that it acts as a laxative because it is not absorbed by the intestines. Also that the antiperistaltic motions of the proximal colon are not affected. The author further cites the experiments of Magnus with tincture of opium, in which that observer found that this drug causes a marked delay in the evacuation of the stomach, at times even an arrest of the meal in the oesophagus. He also found that a constriction was always present in the stomach between the fundus and the pylorus; but that the food passed normally through the pylorus from the antrum.

The small intestines were affected only slightly, and the antiperistaltic action of the proximal colon, as well as the peristaltic action of the distal colon, apparently remained unaffected.

Magnus (according to the author) also found that the effect of the tincture of opium was practically the same as that of morphine; except that with the former there was a larger residue in the oesophagus, longer delay in the stomach, more marked constriction at the antrum pylori, and greater delay at the pylorus, than with morphine.

Because the results of these experiments of Magnus were not in accord with the hitherto assumed effects of these drugs upon the intestines, which were supposed to be put at rest by them, the author undertook a series of experiments to ascertain the correctness of the observations made by Magnus.

The observations of Magnus and Padtberg were all made with the fluoroscope. The author, however, for the sake of obtaining permanent records, took instantaneous radiographs at certain intervals. He did not take any cinematographs, because that method is not yet sufficiently perfected. All plates were made in 1/100 second so that the restlessness of the cats experimented upon did not affect the clearness of the plates.

The experiments were made as follows: The cats were starved 24 hours before, and the drug was administered to them subcutaneously immediately before feeding, or per os with the food. The latter consisted of 20 grmms. of porridge thoroughly mixed with 4 grmms. of bismuth carbonate. As a control, 4 cats were fed with the bismuth porridge only. Each cat was kept in the same box throughout the time of the experiment (24 hours).

One side of this box was open and a net stretched on a frame was placed in the opening. For the exposure, the cassette was lowered through a slot at the other end of the box, and the cat then pressed against it with the aid of the net. Thereupon an instantaneous radiograph was immediately made.

The experiments on the normal cats showed that even immediately after the ingestion of the meal, no bismuth was left in the oesophagus, that the stomach emptied itself in three to five hours, that there was a very small quantity of fluid present, and that the "Magenblase" was at no time very large, and the peristalsis was very distinct. In the small intestine food could already be observed  $\frac{1}{4}$  hour after ingestion, while in seven hours nothing was left. The colon was reached in  $\frac{1}{2}$  to  $\frac{3}{4}$  hour. In 24 hours little was left in the proximal part, most of it was in the distal portion and the rectum. In the colon very distinct peristaltic incisures were noticed.



For the experiments with opium, the author used pure opium, morphine, pantopon, and morphine-free pantopon.\* The results were as follows: larger or smaller quantities of the meal remained in the oesophagus for considerable periods of time; in the stomach 5, 7, 9, 13 and 14 hours. The "Magenblase" was large at the beginning, and increased as time went on. Peristalsis was not distinct, but a constriction was seen for a considerable period of time between the fundus and pylorus. In those animals in whom the drug was administered with the food, the small intestine was reached immediately. In those who received it subcutaneously, food entered the small intestines in from  $\frac{3}{4}$  to 8 hours, while in both instances it was delayed for a long time in the small intestines, which were also widened and relaxed, especially in those animals who received morphine subcutaneously and opium by mouth. The colon was reached in 4-9 hours. It appeared relaxed, and peristaltic incisures were very shallow.

The author's conclusions are that the difference in effect of the individual forms of opiates was very slight; that greater variations were obtained according to the method of administration, those administered subcutaneously worked more rapidly than those by mouth. With the latter method the effect obtained on oesophagus and stomach came much slower, but on the small and large intestines the results were practically the same. The retardation of the food in the small intestines was not due to delay in the stomach, but to relaxation of the small intestines themselves. In the large intestine there also occurred relaxation and partial distension of the colon. Here the author disagrees with Magnus, who claims to have observed no effect of the opiates upon the antiperistaltic action of the proximal colon, or the peristalsis of the distal colon.

Schwenter believes that from the pharmacological point of view his observations are important, inasmuch as they confirm the opinion held that colon and small intestine are relaxed; in that it also shows that the action of morphine is distinct from that of the other alkaloids of opium; that drug administered by mouth are not as effective upon the stomach, because they probably leave it too soon.

The author also concludes that the instantaneous radiograph is superior to the fluoroscope in making such studies.

---

\*Pantopon consists of the chlorhydrates of the total alkaloids; 1 gramme of pantopon corresponds to 5 grammes of opium. It contains 0.5 grammes morphine and 0.4 grammes of the other alkaloids.

**Gastro-Intestinal Diagnosis from Roentgenological Standpoint.**

HENRY K. PANCOAST, M. D., PHILADELPHIA, PA.

*Virginia Medical Semi-Monthly, Jan. 15, 1913.*

After discussing the indications and technic for this work Pancoast cites the following cases as illustrating the more important gastro-intestinal conditions that belong within the realms of Roentgen ray diagnosis. 1. Large carcinoma, body of stomach. This was a Roentgen ray diagnosis entirely, as there were no direct clinical signs of carcinoma, which was hardly suspected as a possible condition. Confirmed by operation two days later, and partial gastrectomy performed. Note the small projection of the bismuth shadow into the clear area of the growth. This was found to be due to a crater in the latter.

2. The same case nearly four months after operation. Patient had pain and periodic retention. Roentgen ray diagnosis was made of possible recurrence in scar, and was confirmed at second operation. As metastasis had occurred, the case was inoperable further.

3. Extensive carcinoma stomach. Palpable mass. Operation was refused. Extension had evidently caused obstruction beyond in the duodenum.

4. Extensive carcinoma pyloric portion of stomach, not causing obstruction. Palpable mass. Considered inoperable.

5. Carcinoma pyloric portion of stomach without obstruction. Confirmed at operation, but inoperable further than exploration on account of extension.

6. Carcinoma pyloric portion stomach without obstruction. Palpable mass freely movable. Diagnosis based largely on Roentgen ray findings before gastric analysis was made.

7. Same case, five minutes later, patient lying on right side to demonstrate movability of growth.

8. Same case, two and one-half hours later, showing stomach nearly empty and collapsed, with no retention. Area of growth has dropped downward and to the left.

9. Same case, seven and one-half hours after first radiograph, to determine relations with transverse colon. Area of palpable mass outlined by wire corresponding with location at last examination, but lower and more to left than at first. Colon is below growth, and there is no obstruction in the bowel. Note that the bismuth has passed further than usual through the

large bowel, which conforms with the claim that hypermotility of the large bowel is commonly found in such cases. The Roentgen ray findings were all confirmed at operation, but metastasis prevented removal of the growth.

#### GASTRIC RETENTION.

10. Case of extreme gastropsis, with dilatation and retention, illustrating examination by double bismuth meal method. This slide shows considerable retention six hours after the first meal, and due to mechanical obstruction and atony. Note head of bismuth column in cecum and tail in ileum.

11. Same case after second bismuth meal.

#### "HOOR-GLASS" CONSTRICTIONS.

12. Case of "hour-glass" constriction of stomach due to old ulcer scar and adhesions. Exact appearance duplicated at a subsequent examination, and diagnosis confirmed at operation.

13. Case in which this first radiograph suggested an "hour-glass" constriction. This was not confirmed by screen examination, which showed very slow peristalsis with deep contractions along the greater curvature, but with little, if any, along the lesser until near the pylorus.

14. Same case, proving radiographically that the appearance first suggesting "hour-glass" constriction was due to a peristaltic wave.

#### EFFECTS OF ADHESIONS—STOMACH AND DUODENUM.

15. Case of perigastric adhesions following operation for removal of gall stones. Condition suggested by position of stomach to right, drawing of greater curvature to right, and absence of free movability. Confirmed at operation.

16. Case of enormous distention of duodenum, cause not determined. Note vigorous gastric peristalsis.

17. Case of partial duodenal obstruction regarded as result of adhesions or possibly old ulcer. Note retention in stomach six hours after first meal, and head of column at hepatic flexure. Note also the appendix filled with bismuth.

18. Same case, after second bismuth meal, showing distention of duodenum. Diagnosis was suggested at this examination. Stomach of normal size, without ptosis.

19. Same case, eighteen hours after second meal, showing some dilatation of cecum, ptosis of right side of transverse colon,

and appearance suggesting adhesions between transverse and ascending colon and transverse colon and cecum. Appendix still contains bismuth, but tip has emptied somewhat.

20. Same case, patient lying on left side, just after last radiograph. Note that the supposedly adherent portion of the transverse colon remains in close apposition with ascending colon and cecum. This further suggests but does not prove adhesions, because the ascending colon has fallen down to the left with the transverse portion instead of holding it up.

21. Same case, at a later examination of the stomach to confirm the findings in connection with the duodenum. Roentgen ray findings confirmed at operation, gall bladder adhesions found constricting the duodenum. Note bismuth still in the appendix, remaining seventy-two hours, which is regarded as abnormal. Appendix was removed.

#### DUODENAL ULCER STENOSIS.

22. Case in which Roentgen ray findings suggested duodenal obstruction. This radiograph, made six and one-quarter hours after the first bismuth meal, shows gastric retention, with blockage in the duodenum. Findings confirmed at operation, showing old ulcer stenosis.

23. Same case, after second bismuth meal. Note appearance of duodenal cap.

#### THE LARGE BOWEL.

24. Case in which Roentgen ray examination suggested cecal adhesions, although symptoms pointed entirely to the left side as the seat of trouble, and where the bismuth column seemed to stop. Examination could not be completed on account of operation. This radiograph was made only four and one-half hours after the bismuth meal, showing no blockage on the right side. These findings confirmed at operation. Adhesions found on right side as suggested, and also around splenic flexure, and were released at each place.

25. Case in which cecal adhesions were suspected clinically, and suspicions confirmed by Roentgen ray examination. (Eighteen hours after meal.) No operation yet.

26. Case of suspected cecal adhesions, five years after appendectomy. Roentgen ray examination corroborates clinical diagnosis. Confirmed at operation. (Nineteen hours after meal.)



27. Case of obstruction just beyond ptosed hepatic flexure, probably due to adhesions, the clinical diagnosis aided by the Roentgen ray findings. This radiograph was made eighteen and one-half hours after the meal.

28. The same case, twenty-four hours later, or forty-two hours after the meal. Note the slow passage of bismuth through the point of probable constriction. Operation advised.

29. Case of suspected ptosis of the cecum. Examination shows ptosis of cecum and entire colon. The appearance suggested the possibility of cecal adhesions.

30. The same case, examined while lying on the left side. Note that the transverse colon falls away from the cecum, showing the absence of any adhesions binding them together. The cecum does not seem to be movable.

31. Case in which examination showed ptosis of the colon, and strongly suggested movable cecum. Erect posture, eighteen and one-half hours after meal. (Very little in cecum when examined six hours after the meal.)

32. Same case, examined while lying on the left side, and directly after the preceding exposure. Note the change in the position of the cecum.

33. Case of suspected post-operative adhesions on left side. This radiograph in erect posture suggests adhesions between transverse colon and sigmoid.

34. Same case, recumbent posture.

35. Case of ptosis of colon and redundant sigmoid. This radiograph shows the ptosed colon.

36. Same case, showing the redundant sigmoid.

37. Another case of redundant sigmoid. (Constipation relieved by proper use of purgatives.)

38. Case of boy, aged thirteen, with supposed obstruction in descending colon. At a previous operation a greatly thickened descending colon had been found, according to report. This examination, eighteen and one-half hours after the bismuth meal, shows stoppage of bismuth at the splenic flexure.

39. Same case, after administering bismuth enema, showing no evidence of obstruction in suspected portion of gut, but a marked dilatation of the cecum and transverse colon. The cecum could be observed clinically at times. The enema was readily taken. Radiograph twenty minutes later, in erect posture.

40. Same case, directly after last exposure, recumbent posture, plate posterior, to show sigmoid, which appears normal. Note the apparent twist at the splenic flexure, which was regarded as a very remote cause of obstruction, but was not found at the time of operation. The absence of haustra in the descending colon was regarded as somewhat significant especially in view of the history of previous operative findings. At operation no obstruction was found, the only abnormality being a thickened descending colon. This probably acted as an obstruction by its rigidity and interference with peristalsis, but the liquid bismuth enema could readily pass through by the slight force of gravity.

#### Rotch Method of Roentgenographic Age Determination.

H. W. SMITH, U. S. NAVY.

*U. S. Naval Medical Bull., Jan. 1913.*

Rotch appreciating the desirability of an improved means of grading children in relation to the requirements of schools and child-labor laws, studied the question and tentatively adopted the development of the bones of the wrist as an index of the general anatomic development. When it was first proposed to apply this method at the Naval Academy there were no relevant data obtainable. Smith suggested that a study of the process of amalgamation between the epiphyses and shafts of certain long bones might yield results comparable to those obtained by the Rotch method among children. The investigation was undertaken with two objects: To determine what value, if any, the method possessed; and, if it should be found deserving of adoption, to get sufficient data as to normals for its subsequent application to the examination of candidates presenting themselves for admission to the Naval Academy. It was hoped, also, that some anatomic information of value might be derived incidentally from the study concerning the union of the epiphyses.

1. An individual folder was to be prepared, which should contain the following information concerning each midshipman. The "Group" refers to a classification based on the strength test conducted by the medical officer in charge of physical training.
2. Roentgenograms were to be taken of the elbows and hands of all the men in the academy.
3. These were to be studied to learn what stages in the process of amalgamation could be clearly distinguished.
4. After the stages were determined, each epiphysis of each individual was to be inspected and labeled with a

number indicating the stage to which it belonged. 5. A chart was to be made of each stage of each epiphysis on co-ordinate paper—the ordinates to represent the number of men and the abscissae their respective ages, so that the height of the column over any age would indicate the number of men of that age in whom the given bone had reached the given stage. The serial numbers by means of which the columns were to be built up serve to mark the position of any individual. Thus we learn from "Radius stage 5" that there were in the Naval Academy three men of 20 years whose radii present that stage of development. We also learn from this chart how many men there are altogether who have reached that stage, the percentage they constitute of the total, the age distribution of the men entering into the curve and their identity. By this means it was hoped to obtain a curve which, by its highest point, should indicate the age at which the stage should occur, and by its relatively higher points the limits of normal variation. 6. It was almost certain that the form of these absolute curves would be largely determined by the chance general distribution of individuals of the various ages, and would in this way be less indicative of the age distribution of the men in any stage than if there were an equal number of men of each age among the total number examined. Since there are in all few men of 17 and many of 19, disproportionate weight would be given 19 in all the curves. In order to level the general age distribution it was first necessary to find the number of men of each age in the total number examined. This was to form a general age curve and later, a similar curve based on anatomic age was to be constructed. 7. Then a percentile curve was to be placed on each stage chart, this curve to represent in any column the percentage of all the men of that age who are found on that chart. For example, there were eight men in the Naval Academy who were 17 years of age. Of these, 1, or 12.5 per cent, occur in "stage 5" of the radius. Hence in the "17" column, "Radius stage 5" chart, we find an absolute number of 1 man, and a percentile number—13 per cent. 8. Averages were to be obtained which should corroborate the normals as indicated by the curves. 9. Having obtained from percentile curves the normal points, and the limits of normal variation, Smith hoped to be in a position to standardize each individual, noting his departure from normal, its direction and its extent. 10. Up to this point the immediate aim of the work was to get sufficient anatomic data on which to proceed; that is, to evolve the normal



standards without which anatomic age determination would be impossible.

Having accomplished this and having standardized each individual and noted any discrepancy between chronologic and anatomic age, it was then proposed to undertake a statistical study having as its object the demonstration of the influence of relative immaturity on the production of defectives. Smith has taken 1,654 plates of 914 men. After 1,447 plates had been examined, it became evident that no information would be derived from the study of the elbows of men of the age of these midshipmen, and, therefore, all his conclusions are drawn from the study of wrist plates. Otherwise the work progressed much as planned. Fourteen epiphyses selected for study were examined, and a careful description made of the appearances found. When descriptions had been written of each of the fourteen epiphyses in 723 individuals, it was found possible to divide the process of amalgamation into several stages. It was not attempted to make the stages conform to a certain predetermined number. On the contrary, it was found on the completion of the primary examinations that the stages that could be clearly distinguished were eight in number. The first sign of union seems to be the appearance of a minute, disk-shaped center of ossification in the clear space representing the cartilage, but close to the epiphysis. Others appear close by, and they become heaped up, forming what Smith terms imbrications. As they multiply they increase in size and some coalesce.

Other terms used in the description of the stages are self-explanatory. Stage 1. Complete separation, with no sign of beginning union. Stage 2. Complete separation, but a few imbrications appear in the clear cartilage. Stage 3. The imbrications have reached the proximal side, so that the clear line of cartilage is interrupted by them. In the radius this occurs to the outer side of center. Stage 4. The imbrications have accumulated, so that they occupy the cartilage space except at the periphery. They have enlarged and, to a large extent, become fused, the cartilage space being represented by interlacing multiple lines, formed by the spaces between the disks. There is still wide peripheral separation. Stage 5. The multiple lines have contracted to a thick line, which may show traces of irregularity. There are deep peripheral notches. Stage 6. The thick line has become narrow, but is distinct and extends the full width of the bone.



There usually remains a slight notch or depression at the periphery. Stage 7. Only portions of line or traces of notch remain. Stage 8. Amalgamation is complete. Union in the ulna and radius is first completed at or near the center. This is not quite true of the phalanges. With them the center is delayed and union is first completed in an intermediate zone, then in the center, and lastly at the periphery. The peripheral union may occur almost coincidentally with the central, or even before. Usually there is thus left a space in the center which contracts to a double line and then to a thick line, which becomes shorter and may finally disappear, but which often persists in many individuals far into the twenties, long after similar lines have disappeared from the other bones. In spite of this slight variation in the process of union the general division of stages is applicable to the phalanges. Union does not occur coincidentally in the various metacarpals and phalanges, the order in which they unite being—for the metacarpals—first and third, then the second and fourth, and lastly the fifth. For the phalanges, first and second, then the third and fourth, and finally the fifth. The thumb metacarpal is morphologically a phalanx. Each metacarpal and phalanx has but two centers of ossification, one for the shaft and for an end. The epiphysis is at the distal end of each of the four inner metacarpals and at the proximal end of the thumb metacarpal and of each of the primary phalanges. This fact enables Smith to include them all on one plate, together with the lower ends of the radius and ulna. The secondary and tertiary phalanges also have their respective periods of union, but they have not been recorded in this study. In fact, the metacarpals and phalanges have been recorded collectively and more attention has been given the ulna and radius.

The radius has been chosen for particular study, since its amalgamation requires a longer period of time for completion. The stages having been selected by the preliminary study, all the plates were again examined and the proper stage number given to each epiphysis according to its appearance. When this had been done, the construction of the curves was begun. An example of the method pursued may be given. John Smith, series number 657, age 18 years 6 months. The lower radius was seen to be in stage 6, and the lower ulna in stage 5. Then, on "Radius stage 6" chart, in column "18-6," the number "657" was placed. Similarly, on "Ulna stage 5" chart, in column "18-6," "657" was inserted. Thus each chart includes all the men of

whatever age in whom the development of the given bone could be said to grade, the individual in that stage. Thirty-two such charts were found, one for each of the eight stages of each of the four bones—radius, ulna, metacarpals (collective), and phalanges (collective). Then percentile curves were made.

The study was stopped by Smith's inability to determine normals, without which standardization or comparison was impossible. It being practicable only very rarely, and then in extreme cases, to say that an individual is normal, precocious, or delayed, the statistical study that was to demonstrate the value of the method was not feasible. The method, therefore, does not furnish among subadults suitable normals by means of which standardization can be carried out. In this respect it fails, as do other similar methods, to supplant the chronologic system of grading, however defective that system may be.

#### **What is the Roentgen Ray?**

*British Medical Journal, Jan. 11, 1913.*

The nature of the Roentgen rays has long been a matter for speculation. The original theory of Stokes that they consisted of sets of ether ripples was generally accepted, in spite of the fact that no evidence could be produced of refraction, reflection, or diffraction. The failure of the strongest magnetic fields to produce deviation pointed to either disturbance and seemed to negate certain attempts to prove that the rays were corpuscular in character. More recently it was suggested by Professor Bragg of Liverpool that the rays may consist of neutral pairs of corpuscles. He was led to this conclusion as the result of some very ingenious experiments on the secondary radiations arising from surfaces irradiated by the Roentgen rays. This view was strongly combated by Professor Barkla of King's College, who produced further experiments as well as explanations of Bragg's results based on the more generally accepted ether-pulse view. The fact was, no crucial experiment had been devised. A few weeks ago Herr Laue announced a startling result. He found that when a narrow pencil of Roentgen ray passes through a crystal of zinc blende curious regular markings appear on a photographic plate placed behind the crystal. It looked at first as if this had to do with some diffraction effect; but Mr. W. L. Bragg (son of Professor Bragg), as the result of an experimental and theoretical investigation of the phenomenon, showed that the new results may be regarded as reflections from certain cleavage planes existing

in the crystal or, very probably, boundaries of molecular groups. This latter view is strengthened by the fact that the distribution of the rays of the beam are what might be expected from the recent theories of Barlow and Pope on crystal structure. In *Nature* of December 12th, 1912, Mr. Bragg described an experiment carried out on the suggestion of Mr. C. T. R. Wilson, F. R. S., in which the cleavage plane effect is clearly demonstrated. A narrow beam of Roentgen rays, obtained by a series of diaphragms, was allowed to fall at an angle of incidence of 80 degrees on a strip of mica 1 mm. thick mounted in thin aluminum. A photographic plate enclosed in two light-opaque envelopes was placed behind the mica in such a position that the direct rays would give a darkening, while, in addition, if any rays were reflected they also could affect the plate. Such an action was observed. It is almost certainly not merely a surface action, although an increase in the thickness of the mica did not produce an increase of the effect on the plate. Mr. Bragg demonstrated that there was true specular reflection obeying the usual optical laws. At a glancing angle the reflection was very marked. It would seem, therefore, that the Roentgen rays are composed of at least two sorts of rays, one capable of reflection and the other not. And, not for the first time, it would follow that both apparently antagonistic theories are right after all. It now remains to examine the respective ionizing and other properties of these rays, and to test their relative therapeutic values; and already, we believe, the workers in the radiotherapeutic department of the Cancer Hospital have taken up the question. The fact that the reflected rays can be concentrated ought to prove of great service.

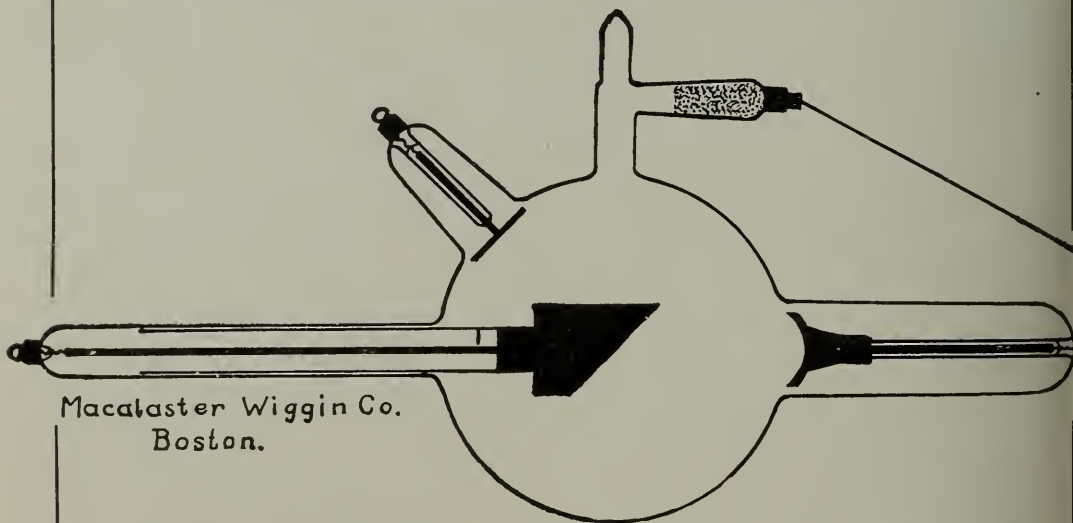
Compact — Authoritative — Practical

Our New Manual of  
**X-Ray Practice  
and Technique**

FREE ON REQUEST

**G. Cramer Dry Plate Company**  
St. Louis, Missouri

**Tungsten Target Tubes for Use on  
the Heaviest Generators**



Macalaster Wiggin Co.  
Boston.

**MACALASTER-WIGGIN COMPANY**

600 Sudbury Building  
BOSTON, MASS.

154 W. Lake Street  
CHICAGO, ILLS.



1 Gal 3785

# American Quarterly of Roentgenology

*Editor, P. M. Hickey, M. D., Detroit*  
*Associate Editor, F. C. Zapffe, M. D., Chicago*

---

---

VOL. IV.

JUNE, 1913

No. 4

---

---

## THE POSITIVE DIAGNÓSIS OF DUODENAL ULCER BY MEANS OF THE ROENTGEN-RAY.\*

BY ARIAL W. GEORGE, M. D.,  
Roentgenologist to the Children's Hospital, Boston, and  
ISAAC GERBER, M. D.,  
Assistant Visiting Physician, General Medical Dept.,  
Boston Dispensary.

Of late years, thanks to the work especially of American and English surgeons, the frequency of duodenal ulcer has been demonstrated to be much greater than that of gastric ulcer. This fact has only within the last year been generally recognized by the clinicians of continental Europe. The change has been due partly to improvement in their methods of physical diagnosis, and partly to the recognition of the typical histories upon which emphasis was laid by Moynihan. In one department of diagnosis, however, the advance of results has not been as rapid as was to be expected.

The diagnosis of gastric ulcer by means of the Roentgen-ray has in the past five years achieved wonderful strides. Much of the advance in this line was made by the so-called "Vienna school," including Holzkecht, Haudek, Schwarz, and Kreuzfuchs; by the Germans—Rieder, Groedel, and others; and by the Americans—Cole Pfahler, Pancoast, Case, etc. Through their researches and investigations, we have come to the point where the diagnosis of gastric ulcer can often be made very

---

\*Read in part, at the annual meeting of the New Hampshire State Medical Society, May 13, 1913.

positive. The diagnosis of duodenal ulcer, however, by means of the Roentgen-ray has not kept equal pace.

The very last word upon this subject was stated by Haudek at the annual meeting of the German Surgical Association, held at Berlin in March, 1913.<sup>1</sup> He came to the conclusion, in presenting what he considers the general Roentgen evidence for duodenal ulcer, that the diagnosis of this condition by the Roentgen-ray is always suggestive, but not always positive. He believes that the positive Roentgen findings might support the diagnosis and occasionally make it certain, but that the reliability of the Roentgen-ray findings in ulcer of the duodenum is by no means so great as that of the positive findings in gastric ulcer. He further stated that Roentgen plates showing apparently normal conditions in the stomach and duodenum must only be taken as suggestive that the ulcer of the duodenum is absent. If the clinical picture suggests that an ulcer is probable, normal Roentgen findings indicate that the ulcer is in the duodenum rather than in the stomach.

On this side of the ocean, the American Roentgenologist, Pfahler, has very recently made the statement that the evidence of duodenal ulcer as shown by the Roentgen-ray, while important, is of less definite value than that obtained in gastric ulcer.<sup>2</sup>

In order that we may understand why no further advance in this subject has been made, we will first review the Roentgen evidence now generally accepted as pointing to ulcer of the duodenum. The two signs usually emphasized are exaggerated gastric peristalsis, and gastric hypermotility.

1.—*Abnormally marked peristalsis* is an important sign if it is found. It is due undoubtedly to the muscular hypertrophy that follows the frequent pyloric spasm. However, on the presence of marked peristalsis alone no diagnosis of duodenal ulcer should of course be made. Abnormal nervous influences may sometimes produce this, as well as pyloric stenosis due to some other cause than cicatricial ulcer. Besides, exaggerated peristalsis may be absent in many cases definitely proved at operation to be duodenal ulcer. This sign can therefore be regarded merely as suggestive.

(1) Jour. Amer. Med. Assoc., 1913, LX, p. 1374.

(2) Amer. Quart. of Roentgenology, 1913, IV, p. 162.

2.—*Gastric hypermotility* is a sign which has been emphasized perhaps more than any other by the Roentgenologists, and, to a certain extent, justly so. The entire question of the relation of duodenal lesions to the motility of the stomach is a problem which has been causing considerable dispute of late. Some internists are claiming that stasis is always present, while others, more especially the Roentgenologists, have the feeling that gastric hypermotility is the rule.

The emptying of the stomach here is really dependent upon two more or less opposing factors:—first, mechanical obstruction of the duodenum or of the pylorus; and second, interference with the normal reflex control of the pylorus. The opening and closing of the pylorus are governed by a reflex nervous mechanism subject to the same laws as peristaltic movement anywhere else along the gastro-intestinal tract.

There is a so-called Myenteric Reflex, which has been studied especially by Cannon. It is briefly as follows: Stimulation of the mucous membrane of the alimentary tract, at any point, causes a contraction of the musculature above, and a relaxation below, the point of stimulation. In this particular instance, the stimulus is free hydrochloric acid. When, during the process of digestion, free hydrochloric acid is liberated and remains uncombined with albumen, then the myenteric reflex acts so as to cause a muscular contraction above the stimulated antral mucous membrane, and relaxation below; that is, the pyloric sphincter will relax and allow a jet of chyme to go into the duodenum. As soon as the free acid strikes the mucous membrane of the duodenum, another similar reflex is set in motion which causes similarly a contraction of the pyloric sphincter above, and a dilatation of the rest of the duodenum below. This contraction of the pylorus will persist as long as there is free hydrochloric acid in the duodenum, that is, until the secretion of alkaline intestinal juices is enough to neutralize it. Then the presence of hydrochloric acid on the stomach side of the pylorus will cause it to open; and a similar series of events follows.

This is the normal reflex mechanism, which can only take place if the wall of the duodenum, where the myenteric plexus is situated, is intact. Any injury to the wall will interrupt the reflex arc, and cause a disturbance with the transmission of this reflex. Then, when material containing free hydrochloric acid has been

squirted into the duodenum, the absence of this reflex will cause the pylorus to remain open or relaxed, thus admitting of a very rapid emptying of the stomach. This is the condition that takes place when there are lesions of the duodenum itself, not extending to the pylorus, and not far enough advanced to mechanically obstruct by cicatrization.

In cases of achylia gastrica, as a result of chronic gastritis or secondary to carcinoma of the gastric fundus, there is a similar rapid emptying of the stomach; depending here not upon interference with the path of the reflex, but upon the absence of the hydrochloric acid stimulus when the first chyme reaches the bulb of the duodenum. Gastric hypermotility may therefore be found, and demonstrated Roentgenologically, in achylia gastrica, carcinoma of the gastric fundus (not of the pylorus), and duodenal ulcer.

In lesions of the duodenum which have gone on to marked cicatrix formation the element of real mechanical obstruction enters, to oppose the tendency to rapid emptying of the stomach from the above mentioned causes. Here, then, we have a balance of two opposing forces. The problem of whether there will be stasis after six hours, a normal emptying, or hypermotility of the stomach, depends upon whether the mechanical obstruction offered by the duodenal stenosis is sufficient to overcome the tendency to rapid emptying of the stomach through interference with the pyloric reflex. This balance apparently has no relation to the gross size and appearance of the cicatrization.

Stenoses which are apparently of considerable extent nevertheless may not cause stasis, because the physiological hypermotility is predominant. On the other hand small cicatrices can offer sufficient mechanical obstruction to overcome a slight emptying tendency, and cause stasis. When the duodenal lesion extends onto the pylorus itself, then we have much more complicated conditions. If the pylorus is involved in a callous formation so as to be held more or less rigidly, preventing proper closure, then the normal hypermotility of the duodenal lesion can easily cause a rapid emptying of the stomach. If, on the other hand, the scar formation is such as to prevent the pylorus from relaxing properly, then there will be an obstructive tendency in the pylorus. In this case there will perhaps be a rapid attempt at emptying of the stomach at the start, and a stasis after six hours; or there may be delayed motility throughout.



From the above analysis we can see that the question of whether or not there is stasis of the stomach after six hours, when the duodenal ulcer is active or cicatrized, is no simple one. There is always a balance between nervous and mechanical forces, which varies from case to case, and this is of such a nature that it is useless to attempt to predict from one case to another. Therefore, while the presence of gastric hypermotility may help us diagnostically in a case of suspected duodenal ulcer, yet its absence, or even the presence of gastric stasis, does not rule it out by any means.

3.—Most investigators have referred also to the shadow, or *fleck of bismuth* which persists in the upper duodenum, at various intervals after the ingestion of the bismuth meal. This sign is sometimes of great value, but it is far inferior to the more exact method of studying the duodenum that we describe later.

4.—The so-called "*Haudek's Niche*." This niche represents bismuth which has entered the cavity of a penetrating or perforating ulcer. Although this is of great importance in gastric ulcer, we believe that it is probably the least important sign in the diagnosis of duodenal ulcer. In our series of cases we have seen it but once. Penetration occurs very rarely in duodenal ulcer, in comparison with the more common cicatricial contraction.

5.—A *tender point* corresponding to the position of the duodenum may be elicited during fluoroscopic examination. This sign is probably of considerable diagnostic value, but is one which we have not employed very extensively, and on which we cannot give any personal opinion.

6.—*Stenosis* of the duodenum may manifest itself by retention of bismuth. This is induced by cicatricial changes or spasm, usually at some point in the transverse portion. The great majority of duodenal ulcers occur in the first portion of the duodenum; therefore this particular sign is of no value in most of the cases.

7.—*Fixation of the pylorus and first portion of the duodenum* is very important, but is only found in a small proportion of the cases of duodenal ulcer. When found, however, it is very definite, and may be demonstrated more easily by the fluoroscopic method. By use of the ordinary technique employed up to date, adhesions from peri-duodenitis cannot be positively differentiated

from adhesions secondary to gall-bladder disease. In both types, the pylorus and first portion of the duodenum are abnormally fixed in the sub-hepatic region. By our methods, to be discussed later, these can be as a rule very easily distinguished.

All the above-mentioned signs, if present, merely support the clinical diagnosis, but very rarely make it positive. We believe that the chief trouble in all this method up to now has been that too much reliance is placed upon purely fluoroscopic findings. Most of the recent advances in gastro-intestinal Roentgen diagnosis have, of course, been made in laboratories where the fluoroscopic method was largely, if not exclusively, used. The wonderful results achieved in the field of gastric diagnosis seemed sufficient reason for using the same methods in the study of the duodenum. The results, however, judging from the opinions expressed by Haudek, Pfahler and others, have not afforded any startling support for this idea.

In our series of cases we have attacked the entire problem from a new point of view. We have employed the method of serial Roentgen plates, as first emphasized by Cole of New York. This is a method which Cole adhered to in spite of considerable adverse criticism, and which has since proved to be one of the most valuable American contributions to Roentgenological technique. By its use we can obtain fine details of the anatomy of the duodenum that are impossible in any other way.

Ninety-five per cent of duodenal ulcers occur in the first portion, or "Bulbus Duodeni."<sup>1</sup> This is the point where the jet of acid chyme impinges on the duodenal wall, and is therefore the one place in the duodenal tract that is subject to continual and repeated traumata. An adequate Roentgenological study of this portion of the duodenum is therefore of prime importance.

It has been definitely shown by anatomical investigation that the first portion of the duodenum is a constant entity. Prof. Germain of the Department of Anatomy of Tuft's College Medical School, has examined the duodenums of 400 cadavers, and from a study of these, he has concluded that the first portion of the duodenum has a very constant shape and structure, unless it is diseased.<sup>2</sup> In our private series of 410

(1) Moynihan, "Duodenal Ulcer," 2nd Ed., 1912, p. 264.

(2) Private communication.

bismuth Roentgen examinations during the past year, in every case where we did not make a diagnosis of a pathological duodenum, we were able to demonstrate a picture of the first portion of the duodenum which we have learned to associate with the normal organ. (Fig. 1.)

Of course, this demonstration of the anatomical completeness of the first portion of the duodenum cannot be obtained by a single technique. We have found that in some cases plates taken with the patient lying on the abdomen bring out the duodenum and pyloric region properly, but in a larger proportion of the cases, however, this is not so; and the plates perhaps have to be taken with the patient standing. In many cases this manoeuver will still fail to bring out the region of the first portion of the duodenum. This is especially true in persons who have considerable adipose tissue in the abdominal wall, and generally in those cases where there is a so-called "Steer-horn" type of stomach. (Fig. 2.) In most of these cases the pylorus and duodenum are directly behind the lower pole of the stomach, and are not brought clearly into view. To overcome this condition, we have employed the method of taking plates with the patient lying on the right side, so that the Roentgen rays go laterally through the body. In this way, partly by the mechanical force of gravity, and partly by the peristaltic action of the stomach, we are able to compel the bismuth mass to fill out the antrum and first portion of the duodenum very completely. By this single method, more than by any other, we have been able to demonstrate adequately the anatomical condition of the first portion of the duodenum. (Figs. 3 and 4.)

In the study of the duodenum by the above method, we use an emulsion composed of 90g. of Bismuth Subcarbonate, 200 cc. of artificially prepared buttermilk, and enough water to make the entire mixture equal to about 500 cc. It is very rarely that any patient refuses to drink the whole amount, even though no attempt is made to disguise the taste or flavor. This emulsion of clotted buttermilk has all of the advantages of the cooked cereal mixtures, inasmuch as it tends to hold the bismuth in suspension for a considerable length of time, with the exception of some precipitation in the standing position. However, this position is very little used, as the lateral position combines the advantages of both the prone and standing

positions, as far as the duodenum is concerned, without the disadvantages of either. This emulsion also has practically all the advantages offered by "bismuth water," because it is liquid enough to fill out all folds, enter niches, crevices, etc., and easily fills out the duodenum. Plates are made at once, and at short intervals throughout the first hour.

Normally the first portion of the duodenum shows as a well-rounded, smooth, solid shadow of bismuth constituting what has been called the "Bishop's cap," or *Bulbus Duodeni*. (Fig. 1.) This region does not contain any *valvulae conniventes*, so that normally the shadow is smooth and uninterrupted. The second and third portions of the duodenum, on the contrary, do contain these valves, and they give a very characteristic appearance, especially in the lateral view;—the bismuth shadow is serrated and more or less "accordion-pleated." (Fig. 9.) In order to determine whether or not the anatomical condition of the duodenum is normal, a single Roentgen plate is as a rule not at all sufficient. If, by good luck, the "bishop's cap," and the second and third portions of the duodenum, show normally then the examination is at an end, so far as the duodenum is concerned. As a rule, however, we are apt to find some variation or apparent defect. This necessitates taking several repeated plates, using the same technique, but taking them at different times. If now, the defect persists in all these plates, taken at different times, and sometimes on different days, then we feel confident and positive in stating that there is a real pathological condition of the duodenum. We feel that this persistent break in the continuity of a normal duodenum is as positive a diagnostic point as the break in continuity of cortical bone, in the Roentgen plate of a fracture.

What we are able to recognize in the duodenum is not the duodenal ulcer *per se*,—that is the actual mucous membrane erosion,—but we demonstrate the effect on the bismuth mass of cicatricial contraction, stenosis, perforation, adhesions, and penetrating effect of a chronic ulcer.

Stenosis when present shows as a rule very definitely, giving dilatation above the point of stenosis, and retention of bismuth longer than is normal. Sacculations, due to the pull of adhesions



upon the duodenum, may show as rounded out-croppings from the duodenal cap. (Fig. 7.) The effect of adhesions produced during the healing of an old duodenal ulcer, cannot always be differentiated from the actual defect due to the ulcer itself, or from the crater of the cicatrix. In all of these conditions, however, although we may have the same smoothly-rounded or irregular defect, we can tell that the duodenum is not normal, but that it is definitely pathological. In duodenal ulcer involving the second and third portions of the duodenum, there will be definite irregularities in the serrated line of the valvulae conniventes, and these are easily shown. Rarely there may be a pocket where bismuth has entered the crater of a penetrating ulcer. (Fig. 9.) Stenoses at the duodenojejunal flexure are not extremely rare;—when they have persisted for some time, they give marked dilatation of the entire duodenum, and retention of the bismuth mass long after it should be out of the rest of the intestine. In all the conditions we have mentioned, except the last, the fluoroscope alone is of very little help.

In questions of fixation of the duodenum by peri-duodenitis, the fluoroscope does play an important part. By its use we can tell whether or not an apparent right-sided position of the stomach is due to accident, or to actual fixation of the duodenum to the region of the gall-bladder or the colon. It is only, however, by following out the above-mentioned technique, with serial Roentgen plates, that we can determine whether these adhesions are due to an old healed ulcer of the duodenum, or to gall-bladder disease. In the former we shall be able to demonstrate, in addition to the fixation of the duodenum, a definitely pathological condition somewhere in the duodenal tract. In the case of adhesions due to disease of the gall-bladder, (Fig. 24), the duodenum will be merely fixed in this region, but the anatomical condition of the duodenum may be normal. Of course many of these adhesions may exist without at all affecting the function of the duodenum.

Where an ulcer is at the pyloric sphincter, with the cicatrix extending into the duodenum or stomach, we usually get a definite antral dilatation, the so-called "prognathian dilatation," which shows very distinctly on the plates. (Fig. 23.)

With the above described method carefully and faithfully fol-

lowed out, negative results are as trustworthy as positive ones. If, at any time during the course of the examination, we can demonstrate an anatomically complete and normal "bishop's cap" and remainder of the duodenum, then, no matter what apparent defects are shown in the other plates, we are convinced that the duodenum is normal.

A "normal" bismuth mass in the duodenum means, of course, that there are no cicatricial contractions, no adhesions, perforations, sacculations, etc. The only thing that could possibly be present is a simple peptic erosion of the mucous membrane, not involving the muscularis. This condition, while quite common in simple gastric ulcer, is practically unknown with duodenal ulcer. The latter very soon becomes callous, and will then show its effects upon the bismuth mass. At any rate, a case that is manifesting itself by any clinical symptoms is sure to be more than a simple erosion. Moynihan, in his monograph on duodenal ulcer, says:—"A duodenal ulcer, which has been the cause of protracted and recurrent symptoms, is always visible from the outside of the intestine, is always palpable, and therefore is always demonstrable. To this statement there are no exceptions."<sup>1</sup> If this be true, an ulcer which can be seen from the outside and can be palpated at operation, is sure to disturb the outlines of the contained bismuth mass. We can therefore safely neglect the possibility of simple mucous membrane erosion, and flatly state that a duodenum which can be demonstrated as anatomically normal by our method does not contain an ulcer, at least an ulcer which calls for surgical interference.

This conclusion has been borne out in the cases of our series which have been operated upon. Out of 125 operated cases, 59 were found to have duodenal ulcer, either alone or complicated with gastric ulcer, or with other conditions. In every one of these cases, except three, a pre-operative Roentgen diagnosis was correctly made of duodenal ulcer or adhesions from ulcer. These three errors were only partial, and were as follows:—

1.—The ulcer was at the pylorus, with a cicatrix extending both into the duodenum and antrum pylori. We diagnosed duodenal ulcer.

(1) Moynihan, l. c. p. 264.

2.—At operation, a thickening was felt in the duodenum, but no scar was seen.

3.—A sacculaton due to adhesions from duodenal ulcer was diagnosed as penetrating ulcer. (Fig. 7.)

In every one of the cases with an operatively proved normal duodenum, we succeeded in demonstrating an anatomically normal bismuth mass in the duodenum.

After studying the duodenum by the above method, we feel quite positive of our results. In a study of the stomach, on the other hand, by the Roentgen method, even if we use the fluoroscope, the interpretation of any results is always open to question. Defects of filling, and other apparent abnormalities, may be due to spasm, pressure from the spine, from extra-gastric tumors, from the liver, spleen, dilated colon and intestine, and to numerous other causes. All of these must be considered in making the diagnosis; and frequently an absolute diagnosis may have to be withheld until we can effectively rule out these various extraneous causes. In studying the duodenum, the possibilities of error are limited, and if, after carefully following out the above-mentioned technique, we find that the duodenum does not fill out normally, and if the defect persists, we can positively state that there is a pathological duodenum.

This method, of course, involves much more expenditure in the way of plates, etc., than the fluoroscopic method with occasional plates. The fact, however, that we can make real positive diagnoses of duodenal ulcer, in our opinion fully warrants the additional expense.

#### Summary.

1.—The Roentgen diagnosis of duodenal ulcer has not kept pace with the improvements in the diagnosis of gastric conditions by this method, especially since the frequency of duodenal ulcer is much greater than that of gastric ulcer.

2.—This is largely due to the fact that the fluoroscopic method has been too exclusively employed in the study of the duodenum heretofore.

3.—By the method of serial Roentgen plates devised by Cole, where the proper technique is employed to bring out the duodenum,—especially the lateral view,—we are able positively to state

whether the duodenum is anatomically normal or pathological. By this method we cannot always distinguish between the effects of adhesions or cicatrix, when both are due to old duodenal ulcer. We can, however, distinguish between adhesions due to duodenal ulcer and those due to gall-bladder disease.

4.—By this method we can be more positive of the diagnosis of duodenal ulcer than we can be of most gastric conditions, as the possibilities of error are not so numerous.

5.—A negative result with the above-mentioned technique and method is as satisfactory as a positive one, as it effectively rules out the presence of surgical duodenal ulcer.



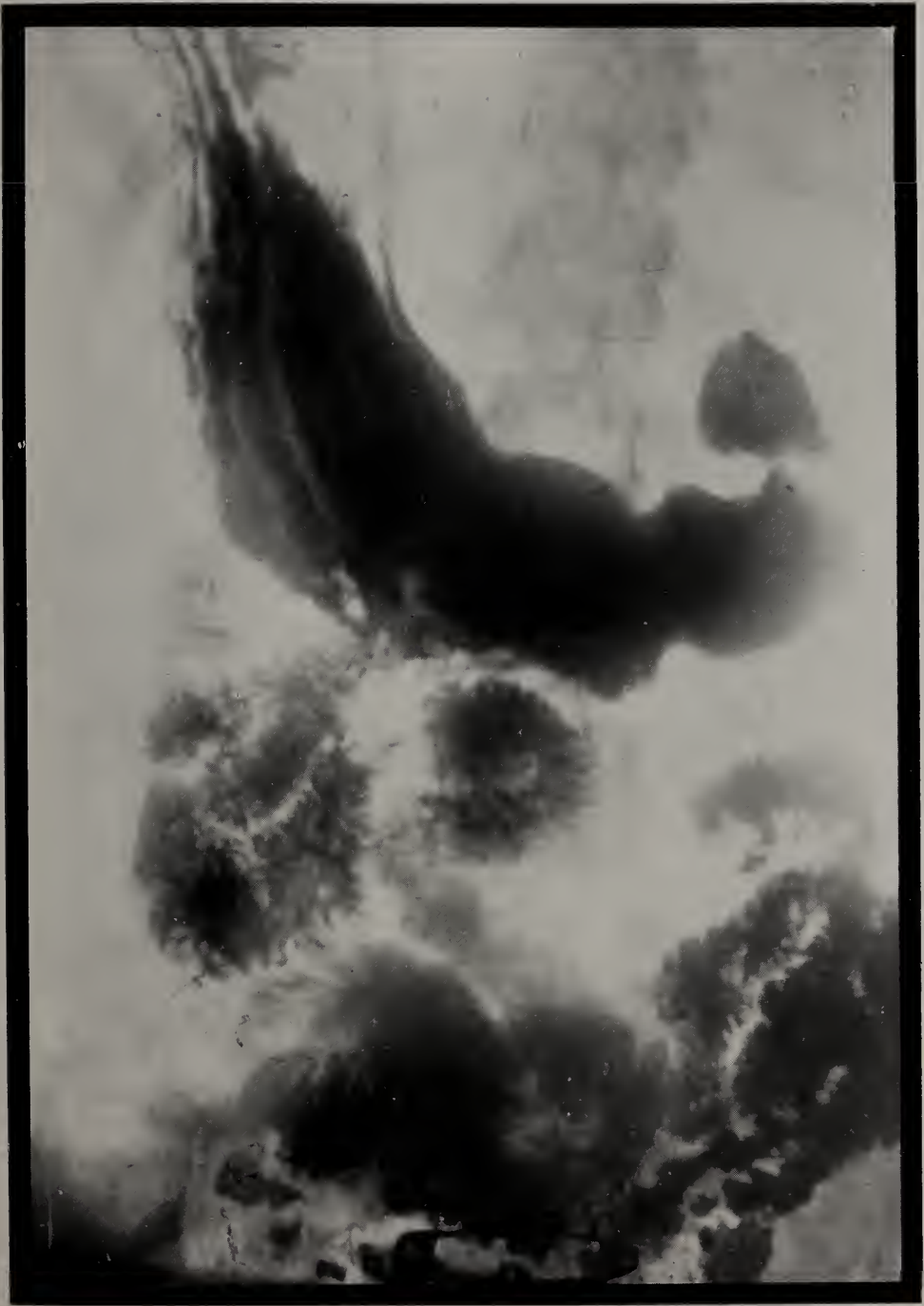


Fig. 1. Normal first portion of the duodenum, or "Bulbus Duodeni."

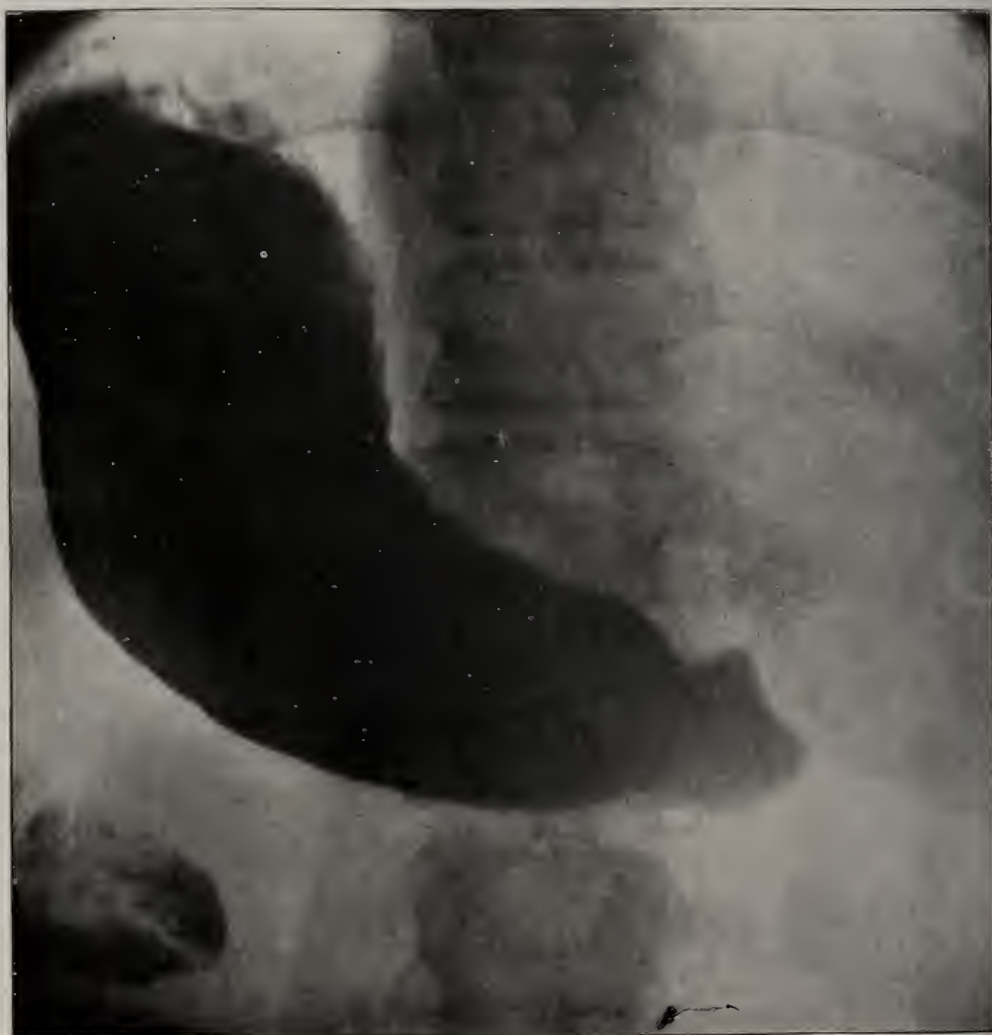

Fig. 2. Plate taken with patient in the prone position. Stomach of the "Steer-horn" type.



Fig. 3. Lateral view of the stomach showing small ulcer near the pylorus, and constant in two sets of plates. There were twelve plates in each set. Same patient as Fig. 2.



Fig. 4. Normal lateral view. Patient was a two hundred and twenty-five pound woman. This plate also shows the possibility of differentiating between ulcer on the anterior and posterior walls of the stomach.



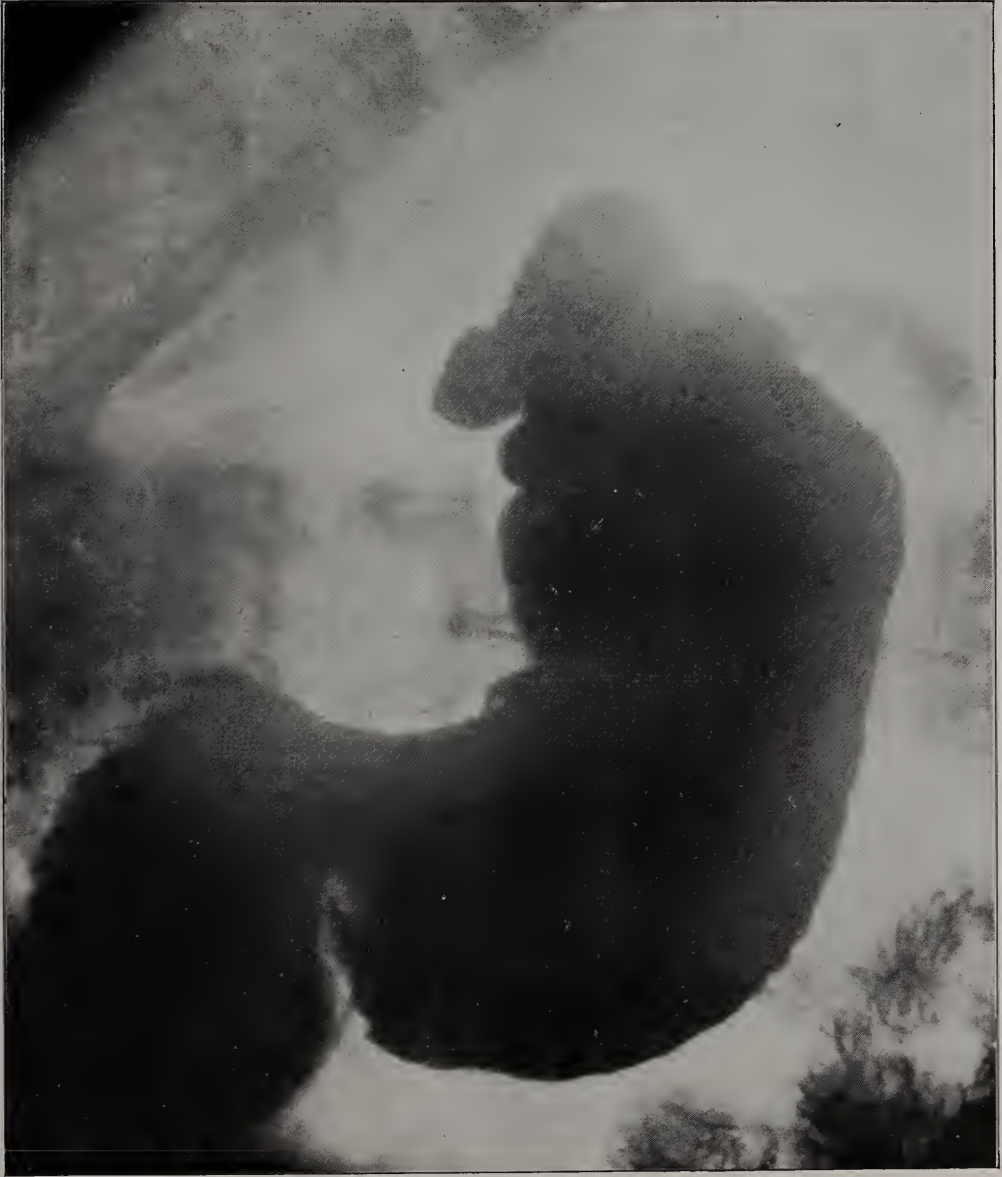

Fig. 5. Plate taken in the prone position shows spasm of the fundus due to a florid ulcer on the lesser curvature. Rounded outcropping in the region of the pylorus. Duodenum not showing.



Fig. 6. Same case standing. Outcropping shown in this case to be on the superior surface of the duodenum. Defect due to duodenal ulcer shown on the inferior surface of the first portion of the duodenum.

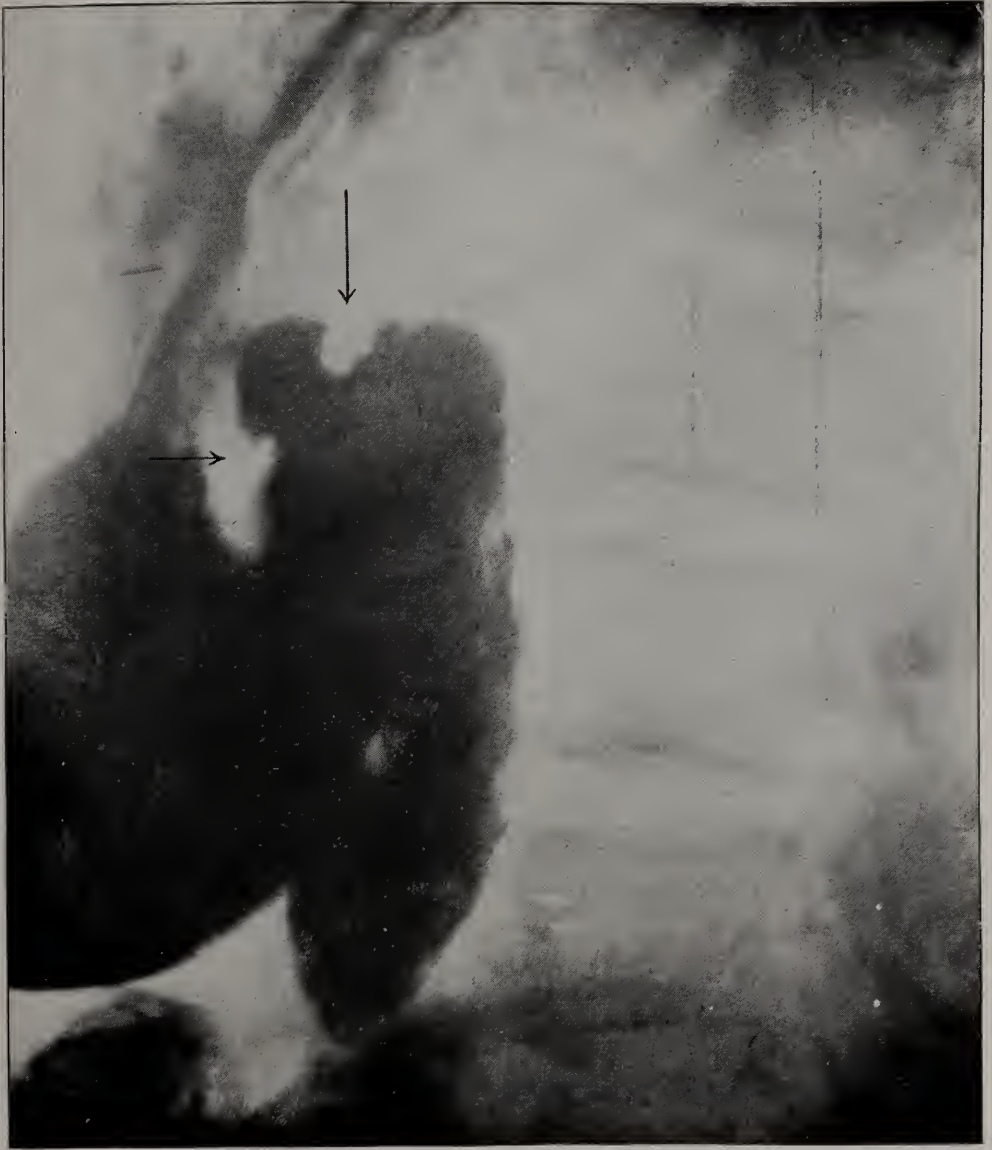


Fig. 7. Same case, lateral view. Sacculations show distinctly here. Was wrongly diagnosed as due to bismuth in a penetrating ulcer. Operation showed sacculations due to an adhesion formed in the healing of the ulcer.

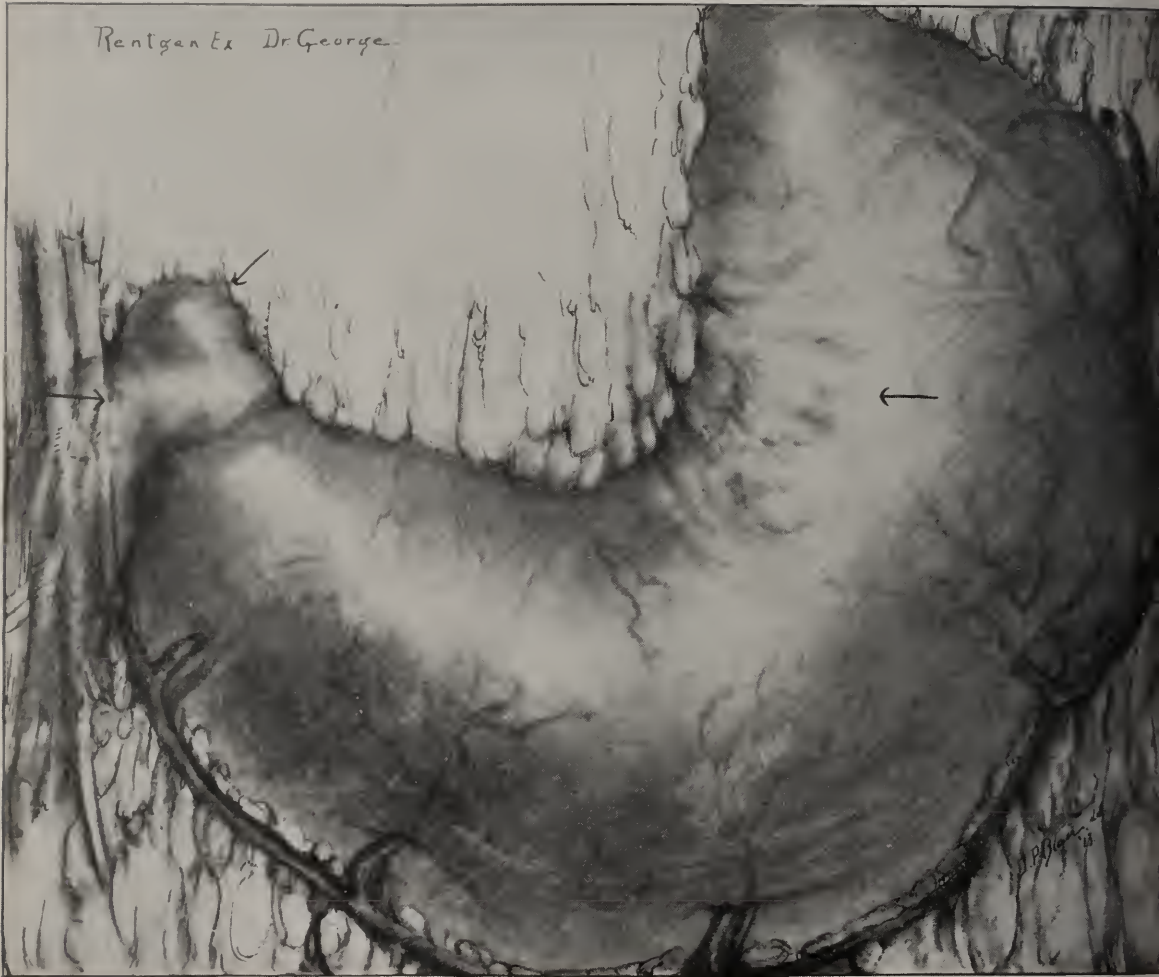

Fig. 8. Diagrammatic representation of the conditions found at operation. Upper arrow shows saculation. Lower arrow shows cicatrix of ulcer.



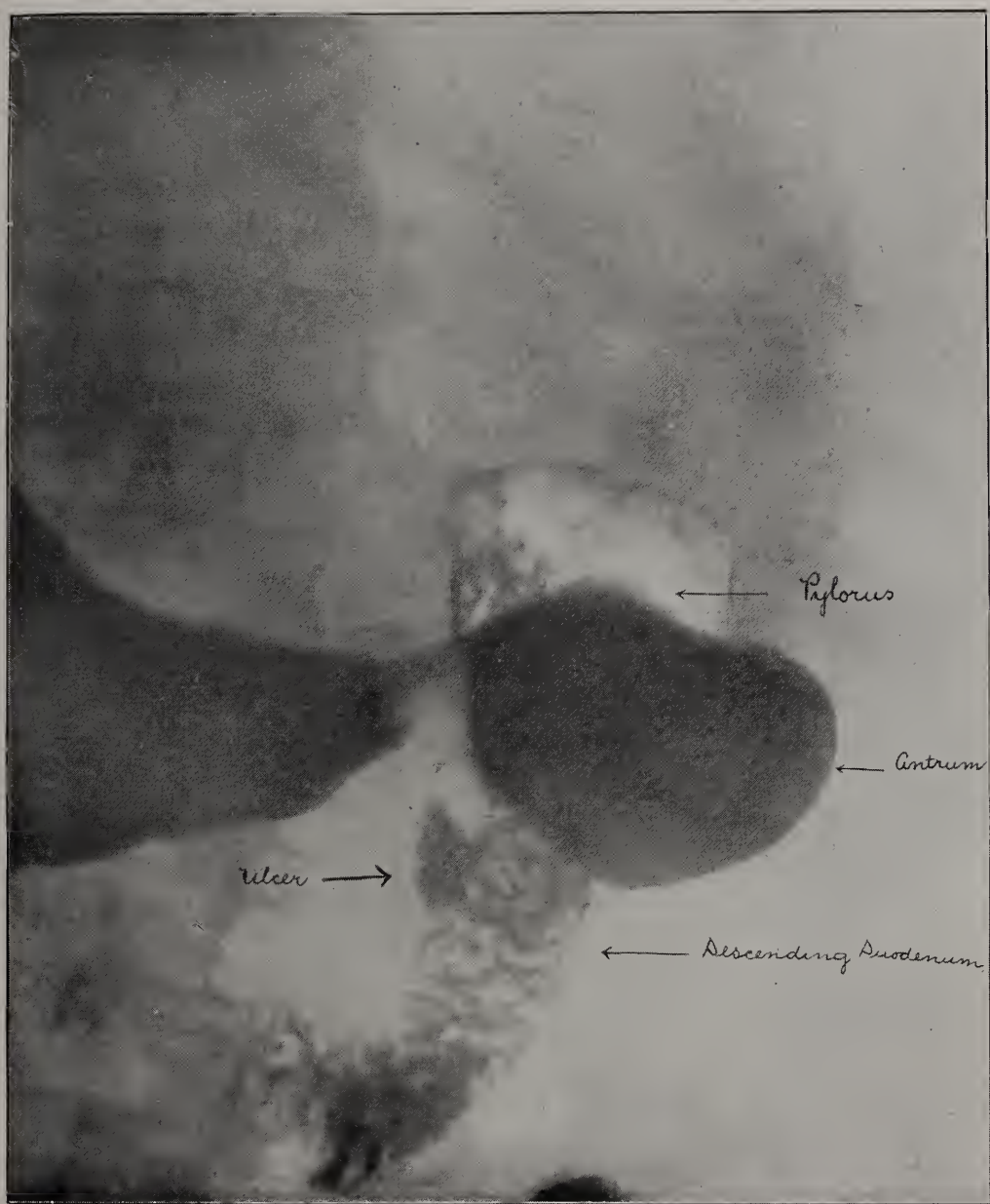

Fig. 9. Hour-glass stomach. Obliterated first portion of the duodenum due to ulcer. Penetrating ulcer of descending portion. Confirmed by operation.



Fig. 10. Showing large ulcer on superior surface of duodenum.

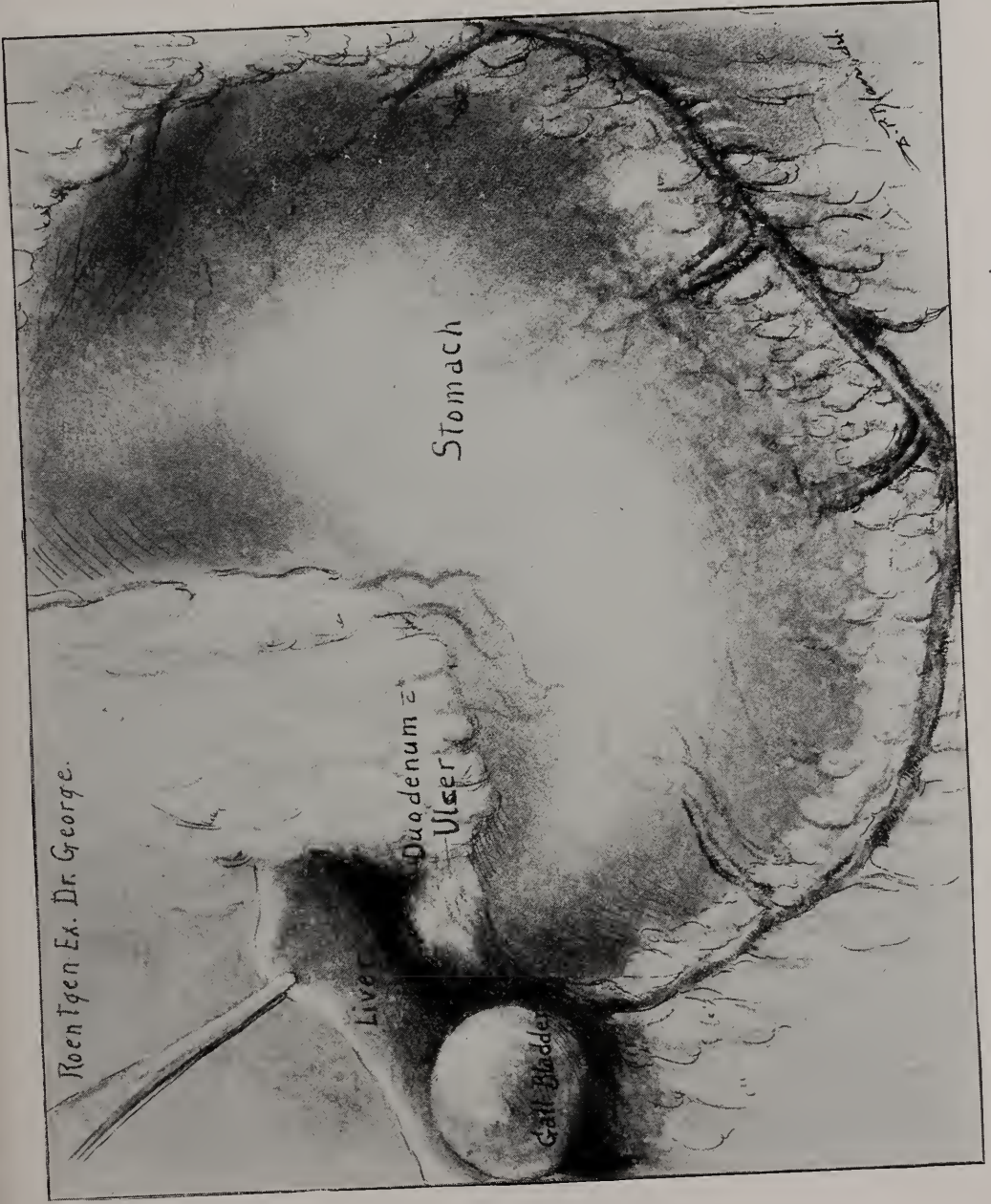


Fig. 11. Same case. Condition at time of operation.



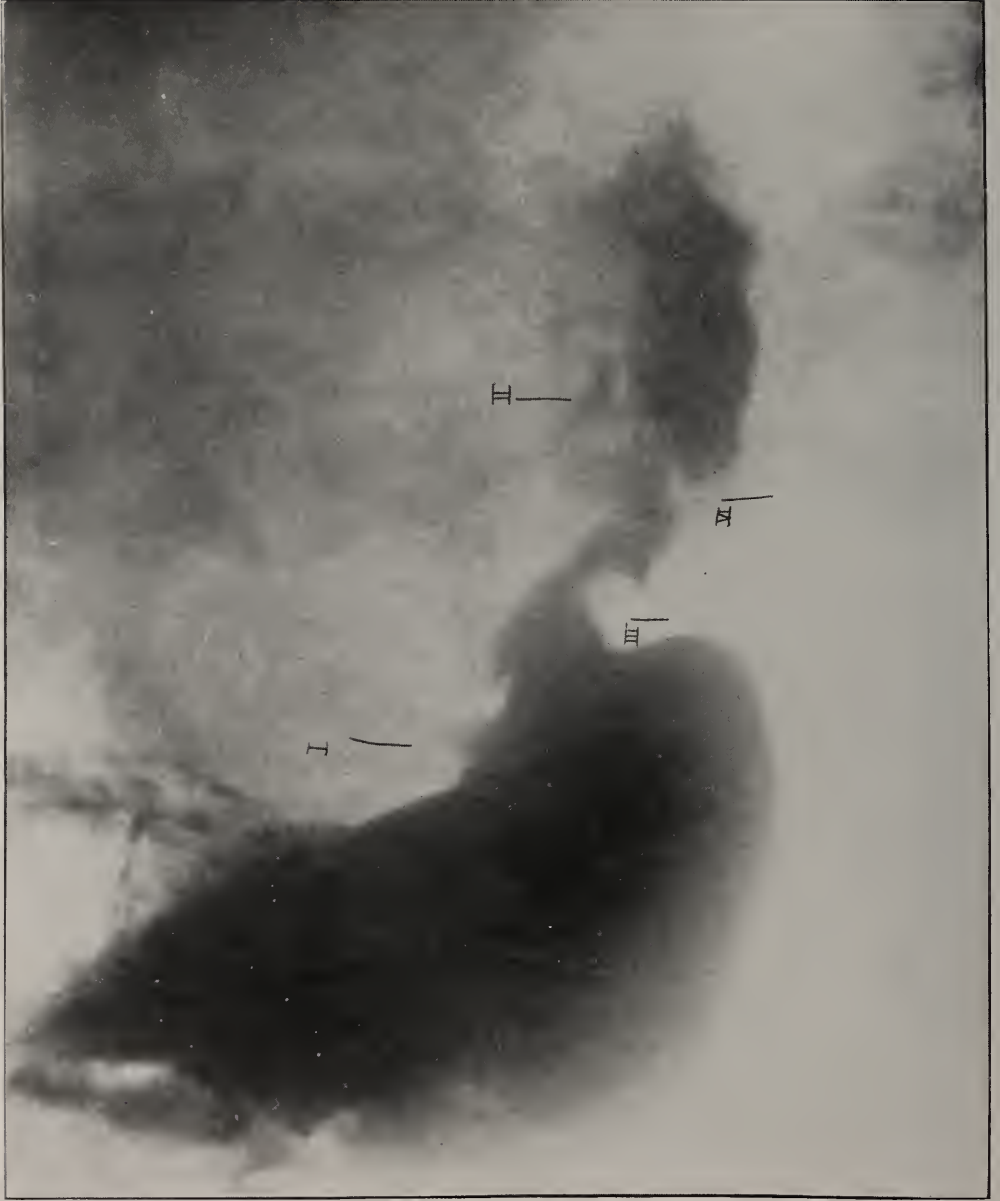

Fig. 12. Plates made one year ago showed penetrating ulcer of the lesser curvature (I). Penetrating ulcer of the duodenum. Operation one year later showed above described condition.



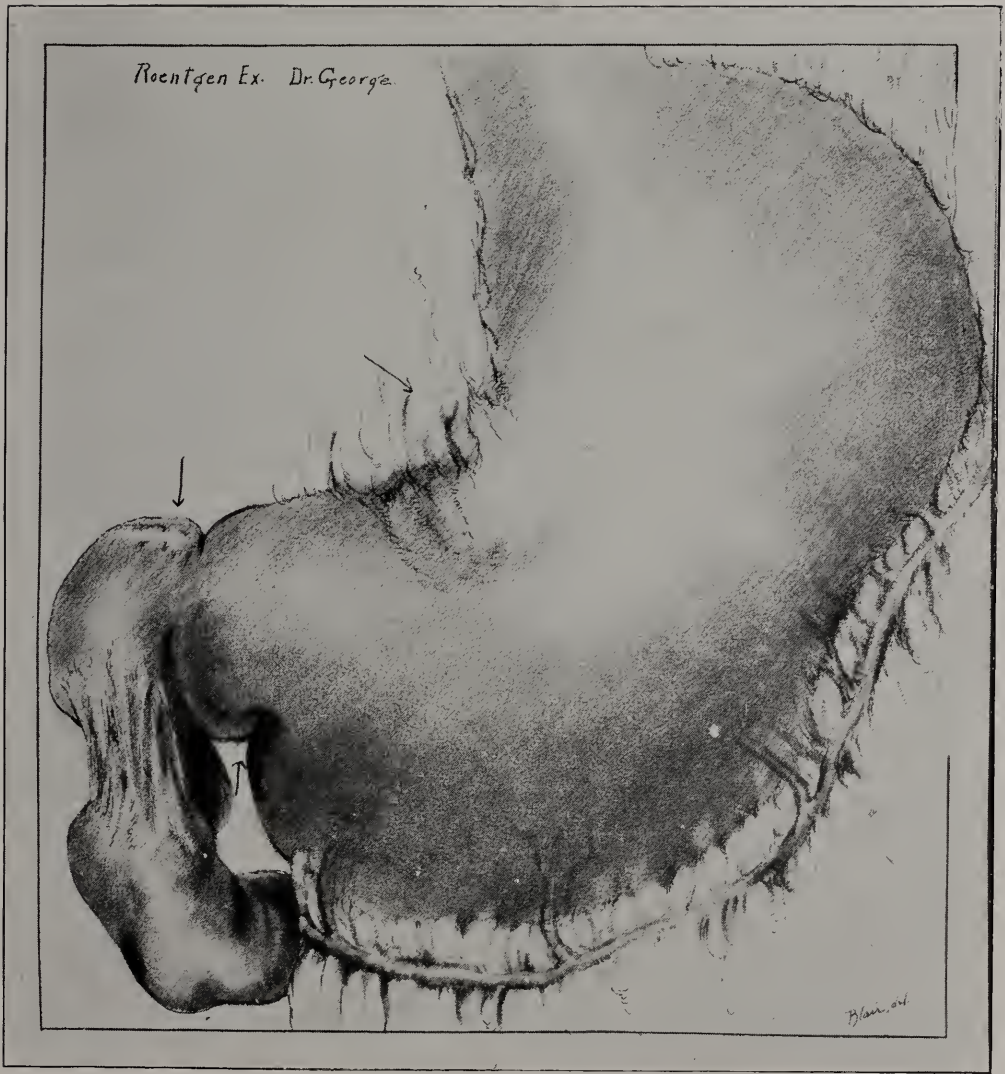

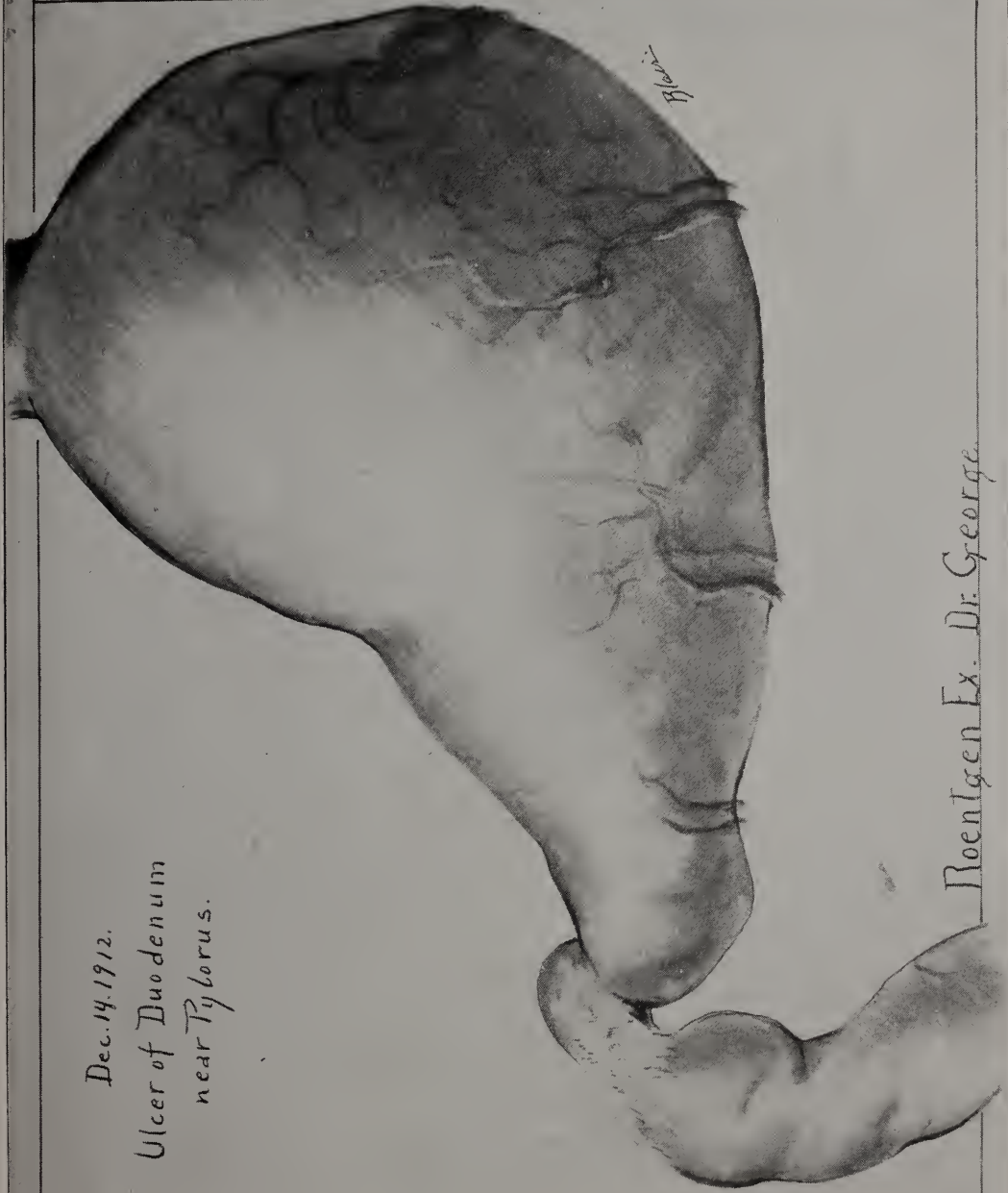
Fig. 13. Artist's drawing at time of operation.

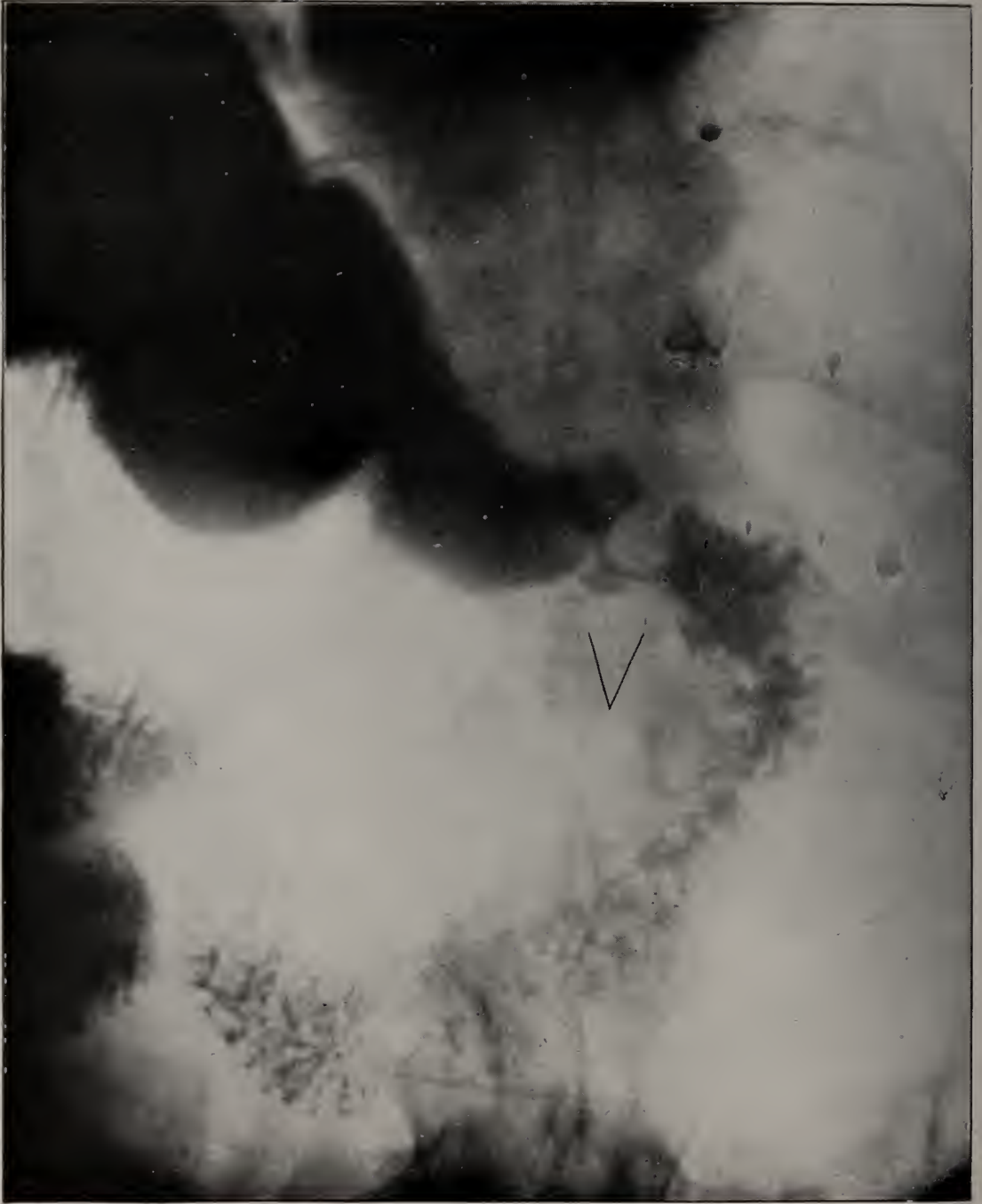

Fig. 14. This case was examined one year previously in Vienna by the Fluoroscope only. The diagnosis made was "Gastro-spasm probably due to Vagotonus." Our examination by serial plates showed the spasm, but in addition its cause. There is an obliteration of the first portion of the duodenum, due to the cicatrix of ulcer.

Dec. 14, 1912.

Ulcer of Duodenum  
near Pylorus.



Roentgen Ex. Dr. George.

Fig. 15. Artist's drawing at time of operation.

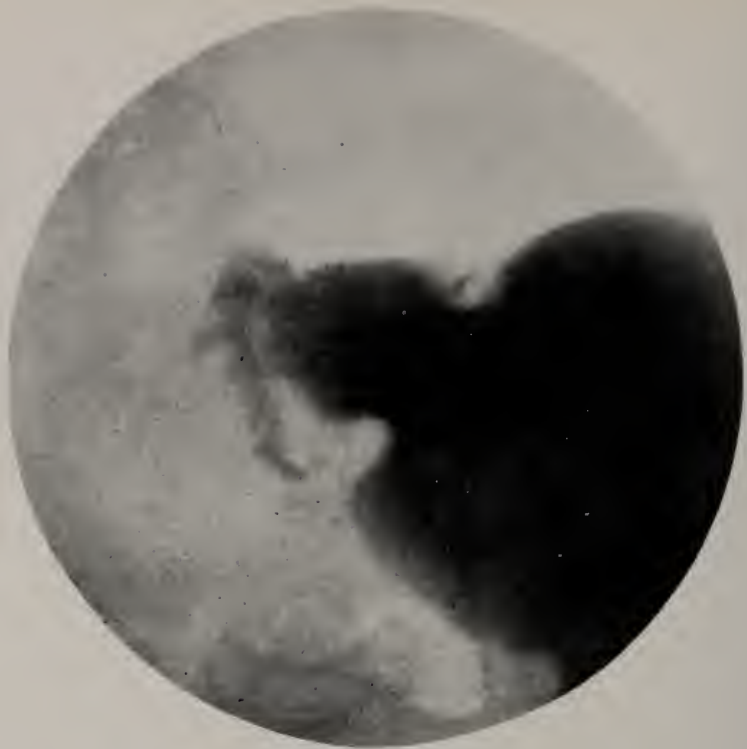

Fig. 16. Lateral view of stomach. Diagnosis: almost complete obliteration of the first portion of the duodenum due to cicatrix of ulcer. Confirmed by operation.

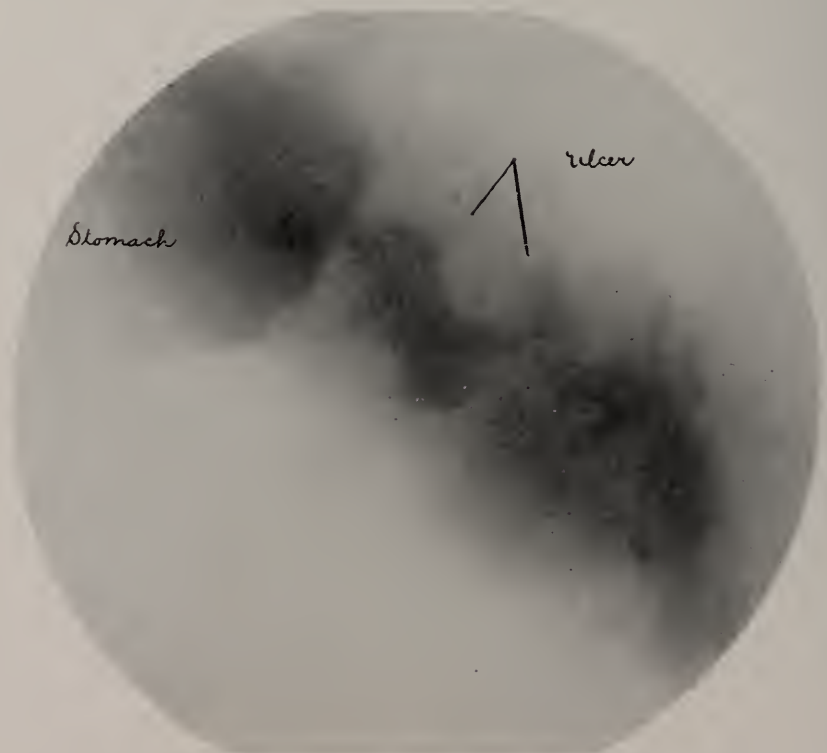


Fig. 17. Shown with an apology. Lateral view of man weighing over two hundred pounds. Numerous plates taken on different days show a persistent defect. Roentgen diagnosis: "Cicatrix of ulcer on posterior-superior surface of first portion of duodenum." Operation showed old ulcer of first portion, on superior surface, extending as much anteriorly as posteriorly.



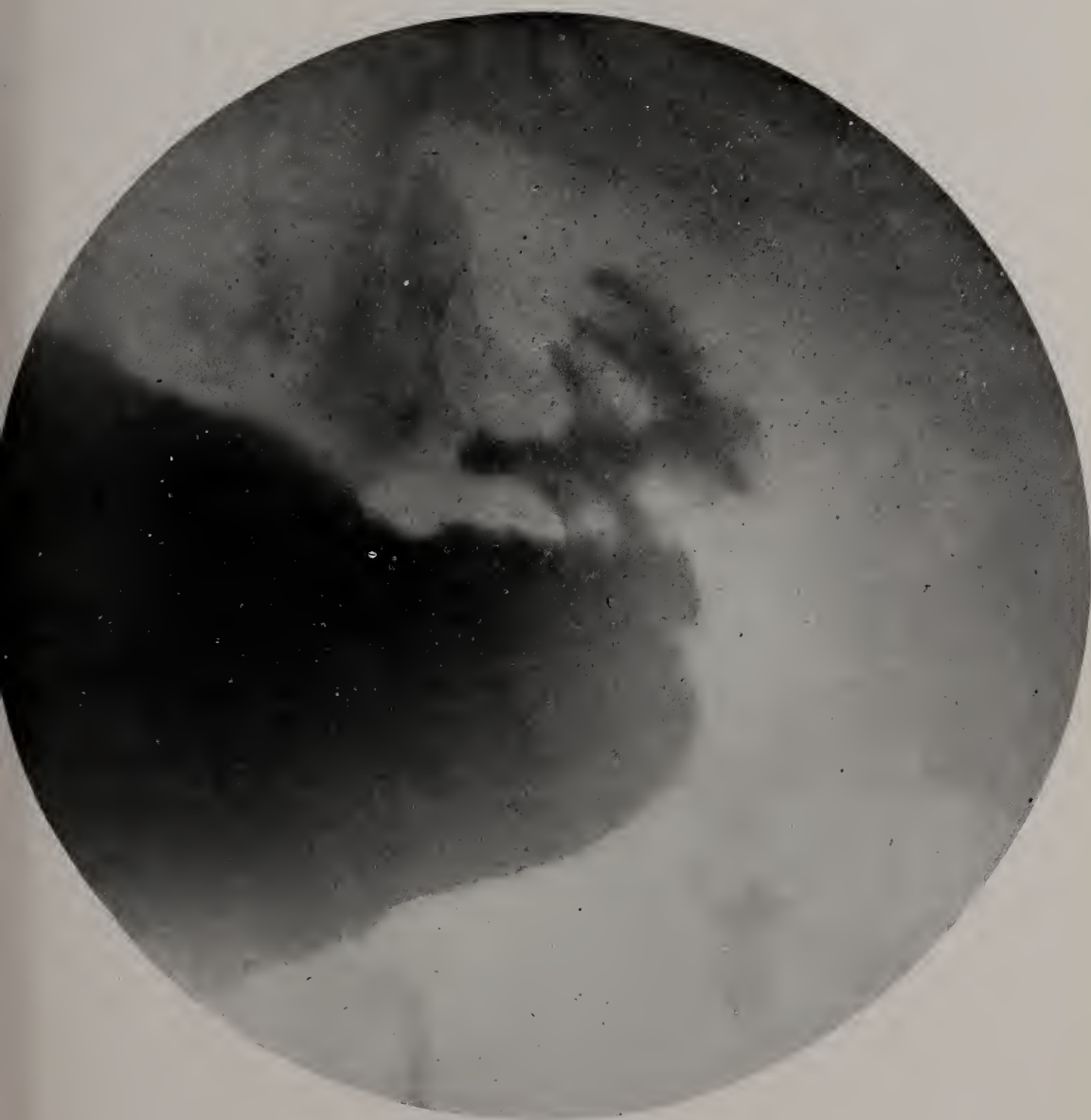

Fig. 18. Extensive cicatrices due to old ulcer. Confirmed by operation.

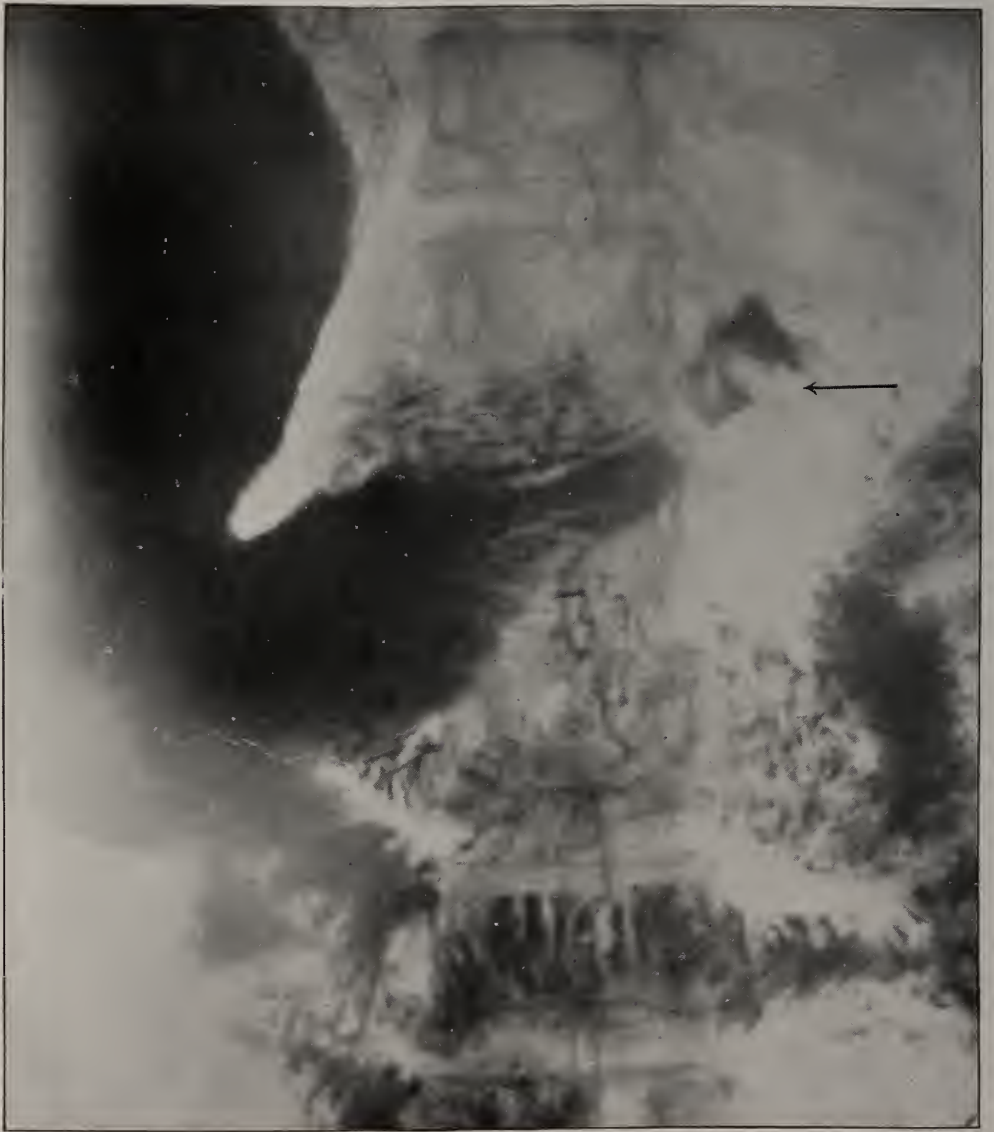

Fig. 19. Typical duodenal ulcer on the inferior surface of the duodenum. Confirmed by operation.

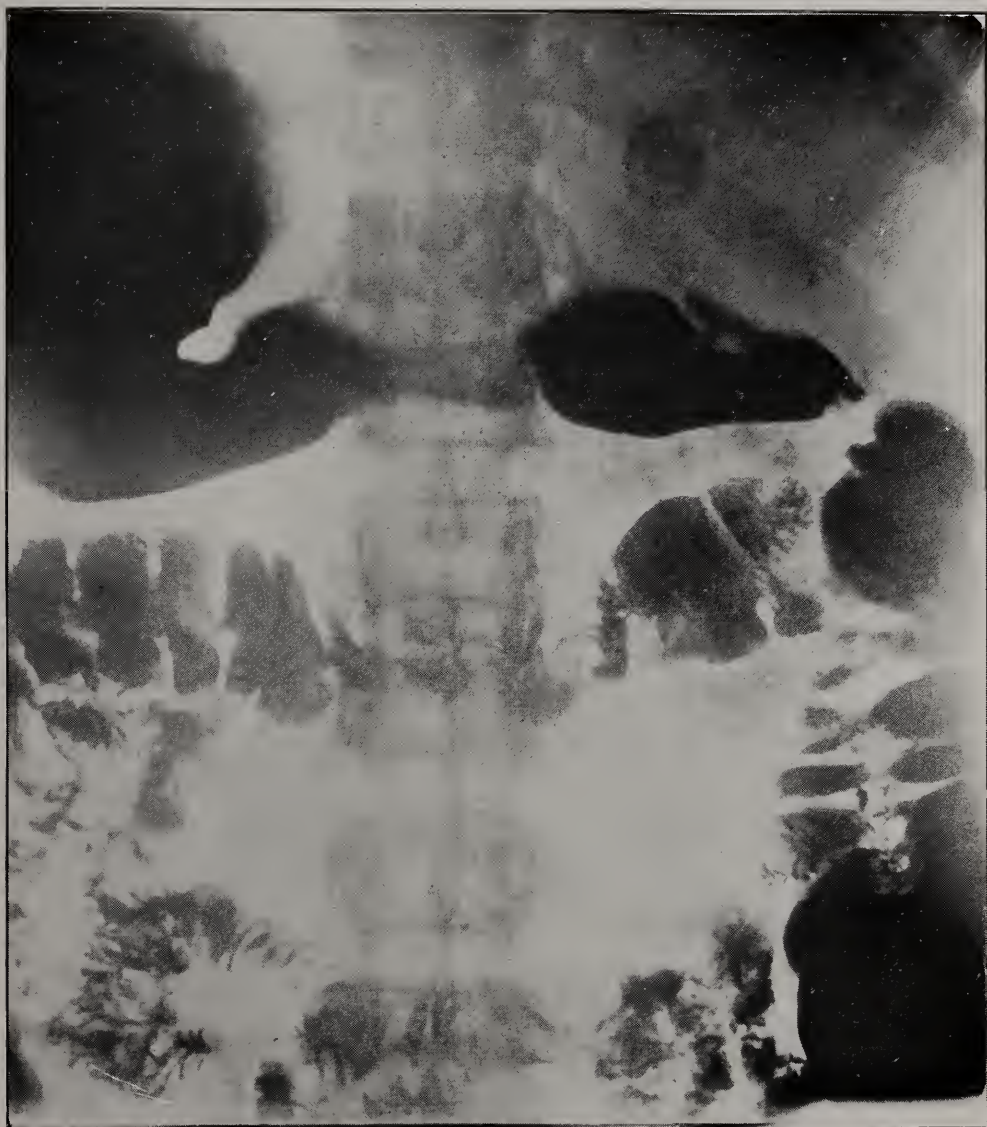

Fig. 20. Plate taken six hours after bismuth meal shows dilatation and elongation with some obstruction of the descending portion of the duodenum. The stomach is held to the right, and fixed to the liver. Confirmed by the fluoroscopic examination and by operation.



Fig. 21. Examination six months ago. Definite hour-glass contraction of lower end of stomach. Obliteration of the first portion of the duodenum, due to cicatrix of ulcer. Beginning hour-glass contraction of fundus. Operation (posterior gastro-enterostomy) was proposed, but refused.





Fig. 22. Same case six months later. Two hour-glass contractions of the stomach well marked. Tremendous dilatation of antrum and duodenum, with obliteration of pylorus. These conditions confirmed by operation. Duodenal dilatation was found to be due to a band of adhesions across the transverse duodenum.

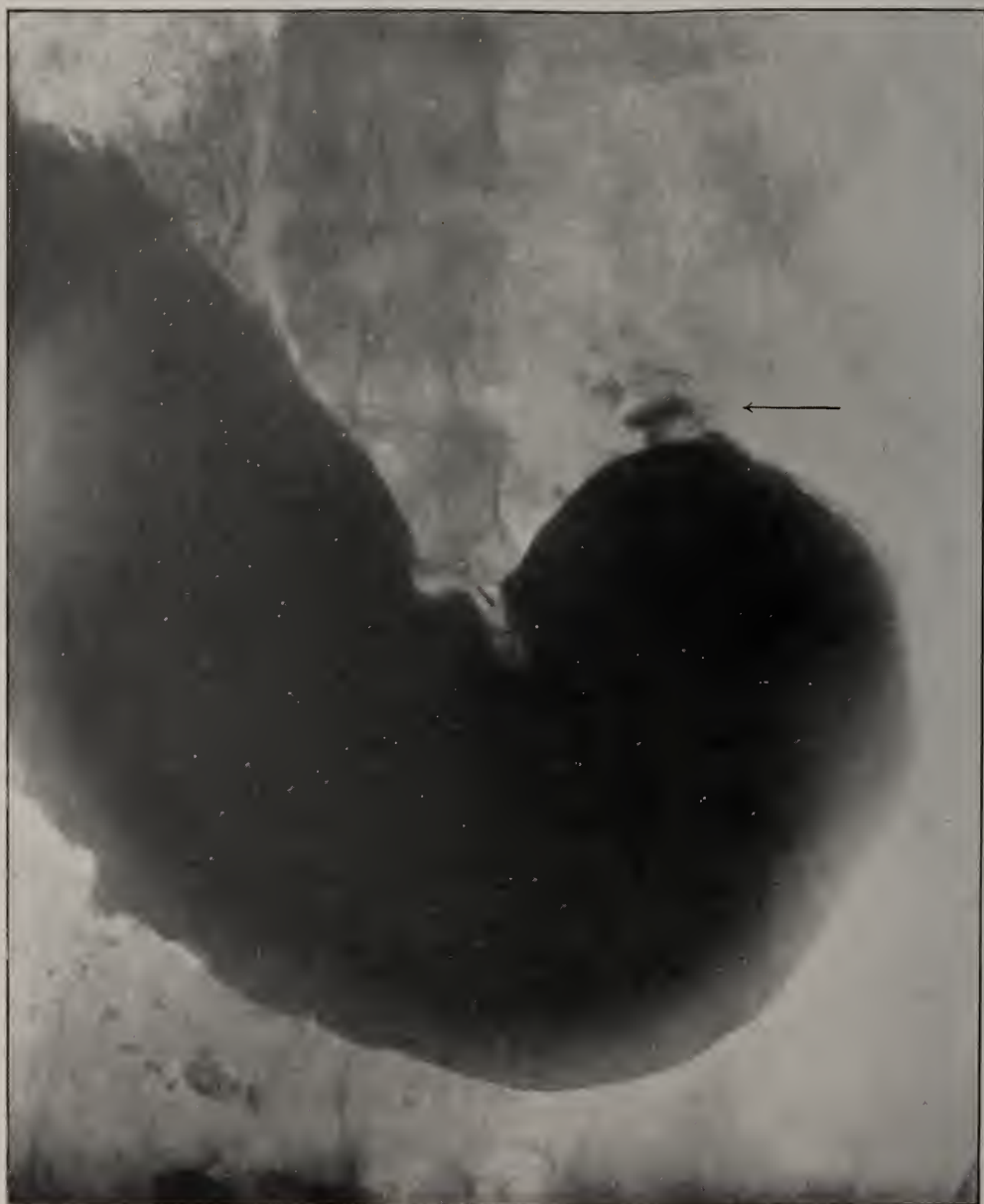


Fig. 23. Chronic duodenal ulcer with cicatrix at the pylorus, extending into the duodenum, causing prognathian dilatation of the antrum, and general dilatation of the stomach.

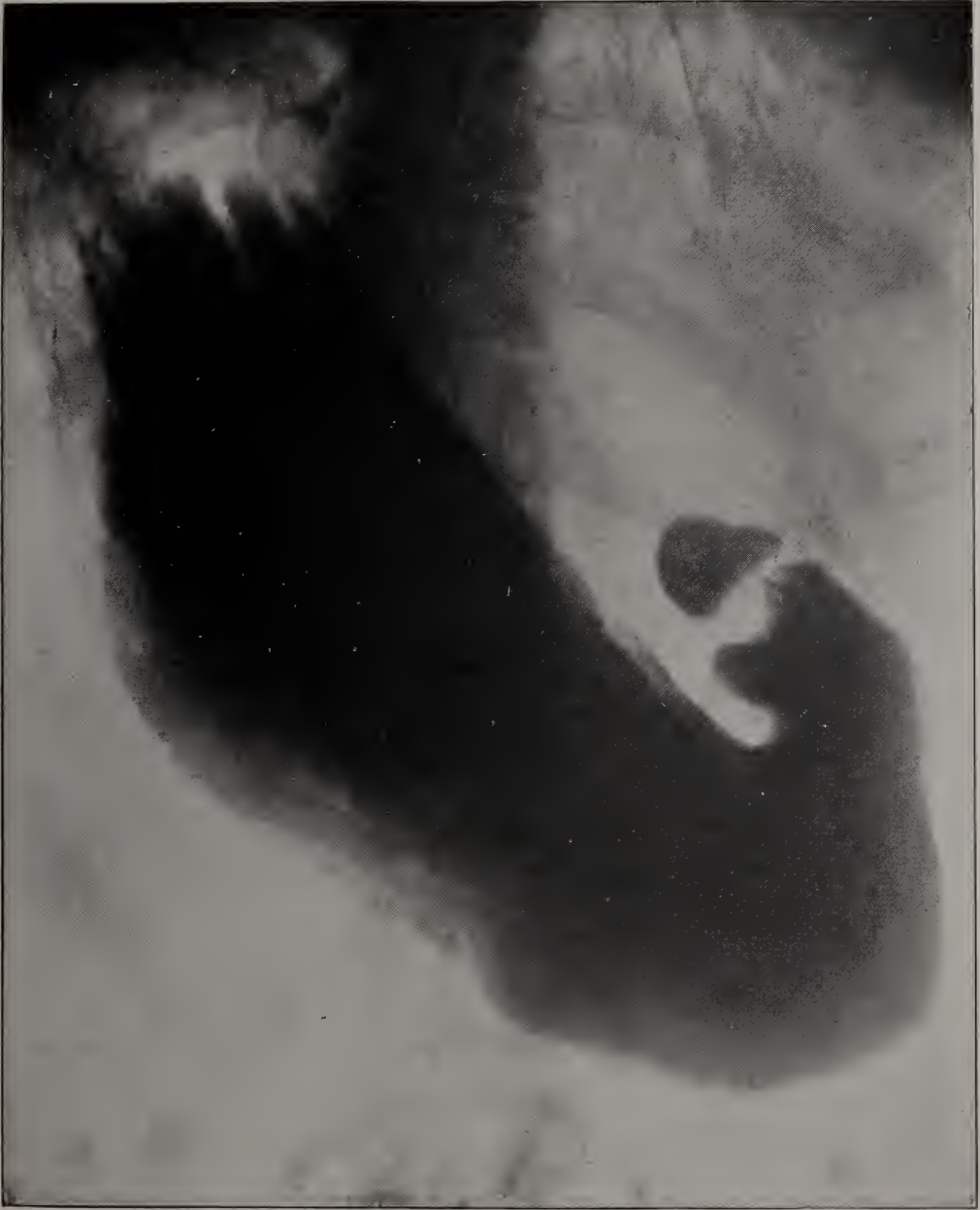


Fig. 24. Clinical diagnosis: Duodenal ulcer. Roentgen diagnosis: "Duodenal cap normal. Fixed position of stomach far over to the right, due to adhesions probably from gall-bladder." Operation showed adhesions around the gall-bladder.

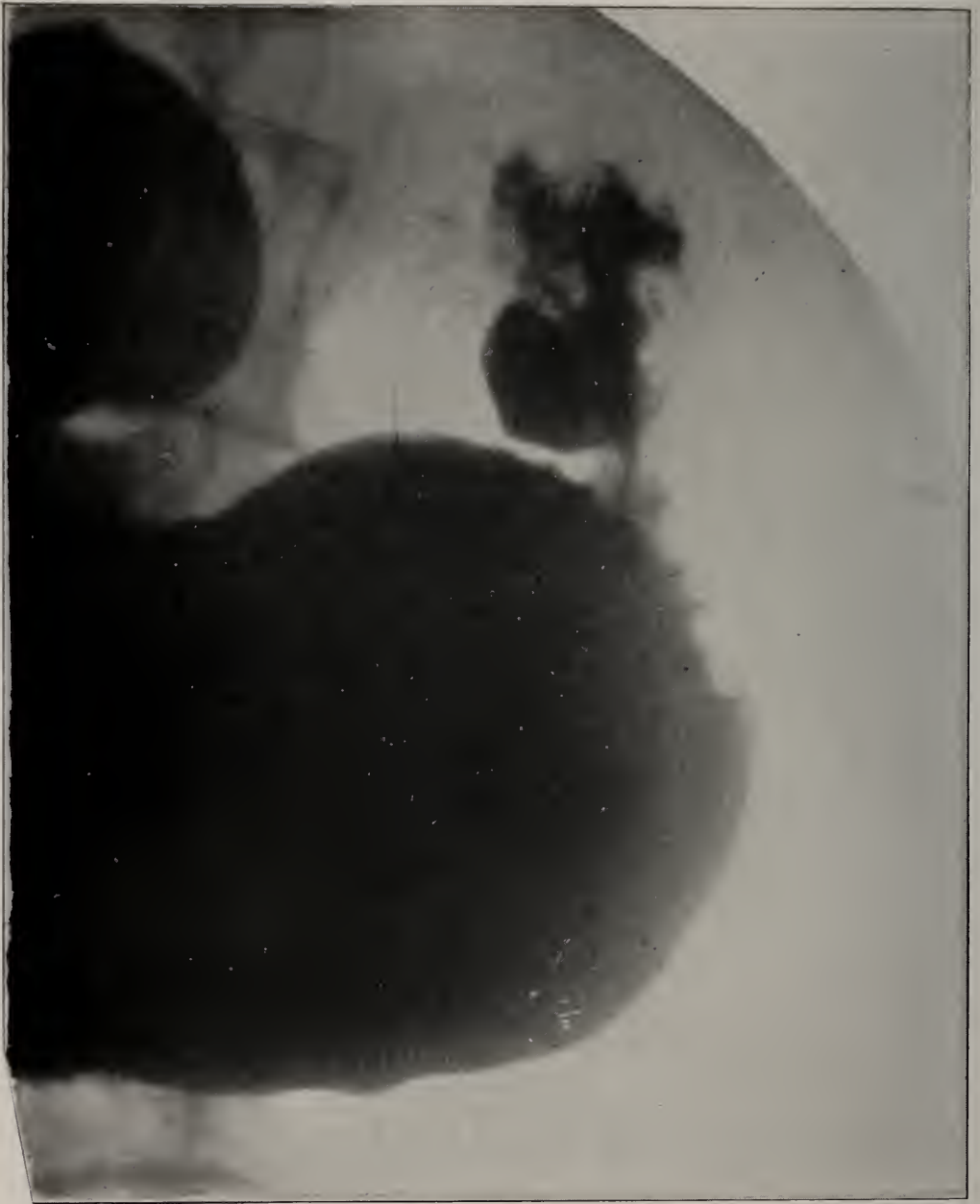

Fig. 25. Roentgen diagnosis was primary carcinoma of duodenum which extended into the antrum on the greater curvature of the stomach. This diagnosis was based on the extensive defects, involving both duodenum and antrum, much greater than conditions ordinarily seen due to ulcer alone. Surgical diagnosis at time of operation was duodenal ulcer. Post mortem confirmed Roentgen diagnosis, the carcinoma being much more extensive in the duodenum than the Roentgen plates show, especially of the descending portion.



## A PLEA FOR A MORE CONSERVATIVE TREATMENT OF MALIGNANT GROWTHS.

BY RUSSELL H. BOGGS, M. D., PITTSBURGH, PA.

At the present time it is evident that there is a profound sentiment spreading among the leading minds of the profession, which questions the wisdom of the hitherto unquestioned practice of treating all malignant growths by the most radical means at our command. This sentiment springs mainly from a more comprehensive experience with a great number of cases traced out carefully to their end results. It is self-evident that such an experience becomes possible only with the passing of many years, and much careful following up of cases.

We all know for what a long time it has been taught, and accepted as a truth beyond dispute, that the only proper and scientific method in malignancy was extirpation, wide and merciless, immediately, and in all cases not hopelessly inoperable on the face of things. This includes, of course, the removal of all lymphatics draining the diseased area, so far as possible, and often a sacrifice of many important structures contiguous to the growth, especially muscles and large areas of skin. The surgeons have tried conscientiously to avoid the possibility of leaving any cancer cells behind. We have all admired the many brilliant operations devised along these lines, and we know how rigorously they were put into practice in innumerable cases. And now at last time enough has elapsed for us to form some true estimate, in the light of experience, of the value of these extreme radical measures.

What opinion must we form?

In a recent clinical lecture John B. Murphy spoke of the great shock he received on reading an article in one of the British medical journals, wherein was analyzed a series of cases of epithelioma of the lip, extending over a period of twenty or twenty-five years. It was demonstrated, from the cases that could be traced that 52 per cent of the patients who had carcinoma or epithelioma of the lip, without any demonstrable metastasis at the time of the operation, died a cancer death.

Dr. Murphy further states that 76 per cent of the patients who have demonstrable enlargement of a gland at the time of the operation die a cancer death. Murphy goes on to speak of mammary carcinoma, and contends that the situation here is "equally unpleasant." "The improved technique," he says, "that has been adopted in recent years,—first, that of Halstead; second, the splendid technique of Rodman; and, third, the additional advance brought out by Handley,—would tend to make us believe that we could get better final results in the future than we have been having in the past. That appeared to be true for a long time until Halstead analyzed his statistics at the meeting of the American Surgical Association in Cleveland. That analysis certainly did not justify us in cherishing much hope."

Nothing could better support the position I am taking in regard to the end results in the purely surgical treatment of malignancy than Dr. Murphy's mature and ripened opinion as expressed in this lecture. "An analysis of that class of cases," he concludes "disheartened me very much, and an analysis of the more extensive operations done in various portions of the body later has added to my discomfort, and has made the cancer field rather a hopeless proposition to me. I think we can honestly say that we have not improved our cancer results in the last quarter of a century."

It must be clearly borne in mind that Murphy is speaking here of those regions in which the cancer is always peculiarly virulent, because of their rich lymphatic supply. By comparison, an epithelioma of the upper half of the face, for instance, is almost a benign growth, and is usually easily and permanently cured, if taken at all early and treated with any skill. Indeed as far as the prognosis is concerned, we can classify cancers of any one type by location better than in any other way.

The virulence of malignancy increases or decreases very strictly with the richness or the poverty of the lymphatic supply in the various parts of the body. Here is a rule which can never be lost sight of, either by the surgeon or the roentgenologist. Now it is an absolute fact that, when properly applied, the Roentgen rays decrease the lymphatic permeability, and produce a condition most unfavorable to the dissemination of the cancerous process, thus tending to render the aspect of an unfavor-

ably situated lesion more favorable. I think all real roentgenologists at the present time appreciate this power of Roentgen-therapy upon the lymphatic system, and the powerful part it has played in the prevention of recurrences and metastasis, as well as at times making otherwise, some inoperable cases operable. This in connection with its direct destructive action on the neoplastic cells and its strongly alterative action on the healthy cells, all of which it has, when properly administered, gives it a very important place in the treatment of malignancy.

Every malignant growth presents a separate and distinct problem which calls for cordial and earnest team-work among all concerned. The patient himself must be brought so far as possible to be one of the team. For many years before the employment of Roentgen rays, surgery held out the only chance of relief. The favorable cases cured by surgery gave the popular belief all over the world that this was the only hope. However, almost every case of malignancy, except where very superficial or favorably situated, recurred. Many relieved themselves of the responsibility by referring the patient for operation, even if the outlook was unfavorable. The careful study of cases in the last few years putting us in a position to determine whether the treatment is for palliation or for cure.

The improvement in surgical technique and the recognition of the necessity of handling carefully both the diseased and healthy tissue, as well as the wide extirpation of all the structures involved, has lessened the number of recurrences by this method. It is to be remembered that recurrences after removal are regularly more malignant in type, more rapid in progress, more prone to metastases than was the original lesion. An incomplete operation (except in certain peculiar types) of itself is as powerless for palliation as for cure. It neither prolongs life nor diminishes suffering. Partial operations, therefore, are scarcely ever indicated. The fact that the long-time many patients, suffering from hopeless, inoperable malignant growths, have lived comfortably after Roentgen treatment, has impressed many with the power the rays play in the treatment of malignancy.

A few have formerly pointed out that possibly the rays had a tendency to produce metastases, but there is no foundation for such a claim, as practically all agree. I have seen cases

where the disease was so extensive and the patient so emaciated that the rays had very little effect. But from this it must not be concluded, as has occasionally been done, that the rays increased metastases. X-ray treatment of malignant diseases must be given powerful enough to produce the desired changes. The small acne dose that is frequently given is useless. If small inefficient doses are given for a long time, naturally the growth will increase in size and a general metastases occur, the same as if no treatment at all had been given.

Some have pointed out the great harm that has been done in incipient carcinoma, particularly of the breast, by careless and repeated manipulations of the growth. It is claimed that this is not only the cause of increasing the growth but also of secondary infection of the lymphatic glands. I have seen a few cases where this is what seemed to have taken place in patients who were treated by massage at the hands of osteopaths. It is certainly better to remove doubtful growths surgically than to manipulate it repeatedly until it becomes so plain that the surgical treatment is usually useless and the patient is therefore in a hopeless state.

Ochsner in the last edition of his *Clinical Surgery* appreciated at least to some extent the value of Roentgen rays. In speaking of lympho-sarcoma of the neck he states: "From the anatomical conditions present in this region an extensive removal is, of course, not possible, and consequently these cases, with very few exceptions, have been hopeless; and still there are undoubtedly a few who have recovered permanently. The after treatment with the X-ray seems to be of great importance. We have seen severe cases in which the recurrent nodules have disappeared permanently."

I have treated quite a number of cases of lympho-sarcoma of the neck, some following operation, to prevent recurrence; some when recurrence had taken place, and others without operation at all. The experience gained from treatment without operation has convinced me that these tumors will usually disappear under heavy radiation and that the results are more permanent if the patient is given X-ray treatment at first without operation. In nearly every case the mass can be made to disappear under heavy



radiation, if the treatment is begun before the glandular involvement is too extensive, even if the mass has attained considerable size and the skin is not broken. After the growth has entirely disappeared a second series of radiation should be begun as soon as the reaction has disappeared. It may be necessary to give a third or even a fourth series, watching the patient for at least a year or more.

I have patients apparently well for over four years in whom a gland has been removed and a microscopic diagnosis made. In this connection I will mention the following case: Mr. H., age forty-two, had a gland removed from the left cervical region at the Mayo Clinic and a diagnosis of lympho-sarcoma made. On account of the size of the mass, operation was not advised, and they suggested X-ray treatment. At the end of six months the mass had disappeared and no glands were palpable. Three years and nine months have elapsed and there has been no recurrence. About the same time another patient was operated on for lympho-sarcoma of the cervical glands, followed by a recurrence before the wound was entirely healed. The tumor increased under radiation, given three times a week for four weeks, when the recurrence was almost as large as the original growth. Then, intense radiation was given daily for three weeks after which irregular treatment was given for the next six months. Up to the present time there has been no recurrence.

My most successful results in sarcoma have been chiefly confined to the lymphatic glands. In few cases in which the disease involved other structures the end results were unfavorable, except in a patient with an inoperable sarcoma at the junction of the clavicle and the sternum. This patient has been apparently cured for five years. Much palliation was derived in many of these cases. Pfahler and others have shown many such cases are not only greatly benefited but have been cured by this method.

The carcinomatous cases in which the Roentgen rays have been of the greatest service are limited to those of the breast, cervical glands and other external parts when internal metastasis has not taken place. Roentgen-therapy is applied in deeply seated growths not with the idea of effecting a cure but in order to check the progress and make the patient more comfortable;

used preparatory to operation, and again post-operatively to destroy any remaining foci.

Post-operative Roentgen treatment has been adopted as a routine procedure by the most progressive physicians and surgeons. This treatment is just as important as the wide removal of a growth as it makes the operation more radical. It is always a question how far the operator should go in the removal of the adjacent glands and in many cases it is impossible to go far enough. The size of the growth does not always determine the likelihood of a recurrence. Therefore, to give the best chance of a permanent cure the rays must be employed, and likewise, there is also a question as to the extent of the reaction necessary to destroy the remaining foci left after an operation, but the mistake has been as a rule that the radiation has been too limited both as to area and to quantity. If the best results are to be expected, the radiation must be given as soon as possible after operation and not as many have done in the past, wait until a recurrence had taken place. Frequently, physicians and surgeons advise their patients to have Roentgen treatment after the operation, but advise them to rest or recuperate first, thus losing valuable time.

When treatment is given it certainly must be given according to the judgment and discretion of the roentgenologist and not the physician or surgeon referring the patient unless he is familiar with this method and has followed a number of cases. It is most disheartening the way physicians and surgeons take it upon themselves to tell the patient when he or she has had sufficient radiation and this explains many recurrences. Of course any one who has had sufficient experience in malignancy knows that a few treatments are useless, unless followed up systematically and as thoroughly as a course of mercury. And while, the time may come that the experiments now being carried on in Europe will lead to a treatment for cancer analogous to the Salvarsan treatment, still we must rely, at present, on the Roentgen rays which remains the best treatment we have for palliation, prophylaxis and cure in many types.

In the paper which I read before this society two years ago, I spoke of my own faulty technique in a case which I had treated six years before. This case received heavy radiations after

operation, over the anterior chest wall but very little over the supra-clavicular region. A supra-clavicular recurrence was noticed six years after the operation. Under heavy Roentgen treatment the recurrence almost entirely disappeared for a year. She is now back with a second recurrence, but is comfortable and the picture of health. This recurrence which sprang up quickly, was each time controlled by X-ray and the growth became hard, freely movable and approaching the schirrous type. We all know that the atrophic schirrous type is much less malignant than the medullary and that also the rays increase the stroma and decrease the cellular elements, thus tending to convert a medullary to a schirrous type. It not only decreases the mass but also the degree of malignancy. The palliation and the prolongation of life that the patient receives from Roentgen treatment in recurrent carcinoma should never be denied them.

The external recurrences can be caused to disappear, unless too extensive, and great relief is often obtained when the bronchial and mediastinal glands are involved. Hopeless cases which have not been operated on derive more benefit in comparison with hopeless recurrent cases. These patients not only obtain palliation sooner but live longer and more comfortable than the recurrent cases, possibly because the bronchial and mediastinal glands are not so much involved. Many hopeless cases present themselves when they are almost in a septic condition, and after a few heavy treatments, there is not only marked improvement in the disease itself, but the aspect of the patient is completely changed; from one of the most miserable objects in the world she usually becomes fairly comfortable.

Ochsner's conclusion in regard to recurrent carcinoma of the breast is as follows: "During the past few years a number of these apparently hopeless cases have been cured after the use of Roentgen rays. Whether such recovery is to be permanent remains to be seen. In our own experience no patient has presented herself for treatment of this condition to whom we could promise any surgical relief."

The question of ante-operative treatment is still a live subject for discussion, and my experience in the past few years makes me feel firmer in regard to ante-operative treatment in many

cases of malignant growths than I stated in the paper which I read before this Society two years ago.

It is well known that carcinoma of the glands of the neck are nearly always secondary to epithelioma of the face, carcinoma of the larynx, parotid glands, tonsil or tongue. The following is Ochsner's treatment of the glands of the neck: "Thorough surgical removal is the only treatment that promises anything, with the possible exception of treatment by the X-ray. The condition is, therefore, almost hopeless. These cases should always receive vigorous after-treatment with the X-ray."

In contrast to what has been said in regard to malignant growths of the breast, lower lip or where the tissue is richly supplied with lymphatics, is epithelioma situated on the face above the angle of the jaw.

Of course, in epithelioma we are dealing with a malignant condition, but this varies with the pathological condition of the growth and as before brought out, with the location. These lesions range from an almost invisible scaly spot, almost benign in character, to the far advanced cases with extensive glandular metastases. The initial lesions often progress slowly changing very little in months or even a few years, but it must also be borne in mind that they will eventually become active, involving deeper structures and adjacent glands, thus proving fatal. The treatment of many of these early lesions is really prophylactic in nature, but this must be properly done and the old time methods of applying stimulating ointments or irritating caustics are to be condemned. The experience of the older physicians has shown the great harm frequently done by these improper methods, and is the real cause of the popular belief that it is a dangerous procedure to remove a scaly spot, wart or mole before it becomes malignant. Whenever an epithelioma is treated it should be thoroughly and completely removed no difference what method is used.

There are a number of processes which will cure a greater percentage of the early lesions, but it is also true that more cases can be permanently cured and that the cosmetic results are better when removed by radiation. Selection of the Roentgen method for the removal of the early lesion may seem extreme;



but since experience has shown that the prognosis in any case has proved uncertain that the permanent results are so much better, it is a question if it is not always advisable to give the few necessary treatments in order to effect a cure. On the other hand, it is never admissible to give several hundred treatments of short duration, covering one or two years, producing a degeneration followed by a Roentgen ulcer. I have seen a few such cases in consultation and the operator did not know that he was treating a Roentgen ulcer instead of an epithelioma. Every dermatologist and roentgenologist has undoubtedly seen the same condition but in the early days of X-ray, many failed to realize the difference in pathology. When these Roentgen ulcers are removed with all the degenerative tissue, a permanent cure follows almost invariably. When the epithelioma is far advanced or of the more malignant type it has become quite generally recognized that the Roentgen rays is the method that should be employed.

Pusey's extensive experience in the treatment of epitheliomas of all types and the care with which he follows up the end results makes any statement of his along this line authoritative. Dr. Pusey lately gave the history of thirty-six or thirty-eight cases of epithelioma of the lower lip which were treated by means of the X-ray more than three years ago and whose subsequent histories were known. In only two instances were there subsequent metastases under the jaw—approximately five per cent of the failures which does not nearly approach the percentage of metastases occurring under the jaw after surgical interference.

### CONCLUSIONS.

More conservative treatment of malignant growths, I believe, in conclusion, must be practiced in order to secure more positive results in curable cases and afford greater palliation in hopeless cases. The cumulative results from the comprehensive experience of many points to these facts: that the degree and location of malignancy should determine the treatment; that good results follow from early operations when favorably situated; that post-operative Roentgen treatment even in these early operations decreases recurrences; that some unfavorable cases can be made more favorable for operation by ante-operative treatment; that hopeless cases which have not been operated upon

derive more benefit in comparison with hopeless recurrent cases; that the Roentgen rays has superseded all other methods, even incision radically performed, in the treatment of epitheliomas unless involving mucous membrane.

When many more receive a shock in studying malignancy, they are certain to avail themselves of the value of Roentgen rays in the treatment of the seemingly favorable cases, as an adjuvant and as a palliative measure.

CONSERVATIVE SURGERY FROM A ROENTGEN-  
OLOGIC STANDPOINT.

BY CHEVALIER JACKSON, M. D., PITTSBURG, PA.

I am sorry to appear before you with so little knowledge of the therapeutic effect of the Roentgen ray. There is only one reason in the world why the statistics of this work are what they are. The profession has been brought to realize the importance of discriminating between the operable and the non-operable cases, to urge early diagnosis and early appropriate operation, in order to lower the mortality rate. Out of over seven hundred cases of malignancy I operated on an average of only once in every fifty-two cases. Think that over a moment and see what it means. It means refusing to operate on fifty-one cases out of fifty-two. It means refusing to operate on practically every case you see, until you begin to think you never will see an operable case. It is only the early case and only certain types of cases that are operable at all. To give you an illustration: A man was sent to me from Detroit. I found a not very large malignant growth in the larynx. I told the man I would write to his physician, which I did. I told the doctor that the case was not one for operation. That if I operated, the man would in all probability die on the table. He was a large vigorous man, and might have gone through the operation with no more annoyance to himself than would have been occasioned by the extraction of a tooth. The operation could have been done under local anesthesia, but it would have been no more than three or four months when the growth would have recurred. On the other hand, if the growth were let alone, the man would live for two or three years, with the aid of palliative treatment, such as was outlined by Dr. Boggs. There was no doubt but that the period of life could be lengthened.

What happens to these cases? As a rule, the patient goes to a surgeon, and if he realizes that the growth is going to recur anyway, he will feel that he ought to give the patient a chance, and operate. Perhaps he will relieve him from his symptoms for six months. But, gentlemen, that is a crime. In those cases it ought always to be "hands off."

I will not worry you with what is to be regarded as an operable growth more than to say that the larynx is a cartilaginous box; that it contains exceedingly few lymph vessels; that a growth located at the anterior commissure, if it is small and not infiltrating, can be removed by splitting open the larynx and taking out the entire interior of the larynx together with the growth. But in the case I mentioned the growth had extended backward between the larynx and the esophagus, and in such cases it passes quite rapidly into the lymph vessels of the neck, and, as Dr. Boggs said, if we cannot take out the lymph vessels we had better not treat the case surgically at all. An operable case does not mean, then, that the patient will die on the table. There need not be one death in a thousand, so far as the operative section is concerned. Modern surgery has obliterated that operative risk, so that it is practically *nil* to-day. It is the recurrence that is fatal and a fatal result after a recurrence is brought about much more quickly than if the patient had not been operated on at all.

As to the Roentgen ray, it seems to me that this subject ought to be considered from two viewpoints. In the first place, in many cases there can be very material palliative effect. I am sure that in some cases there can even be a curative effect. I know that the ray will do good because I have seen cases where it has done good. I have seen much in the way of palliation and a few cures. Then there is the other class of cases which is considered as being hopelessly inoperable, and if you can give the patient any relief at all, your efforts are worth while, even if the treatment is no more than a placebo. I do not believe in promiscuous operating, but it is worth while using the Roentgen



ray in these cases, and if there is a ghost of a chance you can prolong life for a considerable period, and also make living comfortable. I am connected with seven different hospitals in Pittsburg, and have seen many sad cases. To tell a large healthy man that he must die and that he had better settle up his affairs is an awful thing. No one can realize what that means. You knock the props out from under him and take away all hope. Therefore, if there is a ghost of a chance in such a case from Roentgenotherapy, it certainly is worth while. You do not know, gentlemen, how often I have been begged to operate in these cases, begged by the family, by the physician and by the patient.

Why don't I operate? I do not care to traffic in human life and do what is not for the best of the patient. This is not the only thing. I wish to demonstrate that the operation in an operable case will cure. There are walking on the streets of Pittsburg and elsewhere men with malignant diseases of the larynx. The diagnosis was made by eminent pathologists, and the whole thing is not due to personal skill, but to the courage to say, I will not operate.

A few points Dr. Boggs brought up are exceedingly important: (1) There is the type of malignancy. Few things are recognized so little as the type of malignancy. The other thing I used to speak of often is excessive malignancy. Even if a case is fit for operation and you have reason to believe that that is an extreme type of malignancy, do not touch it. There is one type of malignancy which cannot be demonstrated in the laboratory, but it will recur, no matter what you do. You cannot cure the case surgically or in any other way. That is the type of malignancy which it is important for us to recognize. (2) In regard to the location of the disease. I have spoken of its location in the anterior part of the larynx. That is one class of laryngeal cases which we may consider to be operable. That is one region in the body where the most brilliant results from surgery have been demonstrated. If the tumor is situated further back between the larynx and the esophagus, you enter a region

where any operative interference is invariably followed by disastrous results. It is a case of "hands off."

Dr. Boggs spoke of the surgeon feeling in duty bound to operate. I cannot endorse that feeling. I wish to encourage you all to improve your technic, if possible, in any way as far as it applies to the treatment of malignant growths in the larynx, and especially to the party wall between the larynx and esophagus. To what extent that is feasible you know better than I. If you can improve your technic, I beseech you to do so, because it is a life-saving method. My opinion rests entirely on my own experience, and I will say in conclusion that if you cannot take out the entire growth, let it alone. Treat it with the Roentgen ray to give relief and perchance to cure the patient.

THE NEED OF POST SURGICAL TREATMENT IN  
CANCER.

PRELIMINARY REPORT.

BY DRS. COLE AND HOLDING.

From a review of the literature, medical and statistical on the mortality of cancer, the following statements appeal as being particularly significant.

“The death rate from cancer increased from 73.8 per 100,000 in 1909 to 76.2 in 1910, the latter being the highest ever recorded. As in other countries, there is a tendency toward increase from year to year, varying in degree in the general death rate from cancer, which increase is probably due in part to increased care in diagnosis and in part to increase in the proportion of persons at the more advanced aged periods, but may represent likewise an actually greater specific incidence of the disease.” (U. S. Census Bureau Report 1910.)

This statistical statement does not bring the matter home to us as does a popular article written by MacFarland in which he states, that—“In all persons now living in the United States, aged 35 or over, one man in every fifteen and one woman in every eight will probably die of cancer;” that “almost all cancers of the alimentary tract as well as those which attack the larger organs of the body are inoperable when discovered;” that “ninety to ninety-five per cent of all tongue and pelvic cancers prove fatal.”

Judd (1909) states in relation to the prognosis of surgical operations in cancer of the breast, “The radical operation performed before the pathologist can demonstrate any involvement of the glands will give about 85% of cures, although as soon as we are able to show that one axillary lymph node is involved the percentage of cures drops at once to 25% and if the secondary lymphatics (supra-clavicular) are involved, we will be able to effect very few, if any, cures.”

Savage (1911) says “The better way to put it would be to say that in early cases (those of from two weeks to as many months) the percentage of cures is 60%. In neglected cases,

those where the disease has been present for many months the percentage of deaths is 100%."

Richardson comes to the following conclusion in cancer of the breast cases:—"When there is a mass of conglomerated lymph nodes in the axilla, even if there are no perceptible ones at the first rib, I know that my dissection no matter how painstaking is too late. When I find but one or two nodes in the center of a mass of axillary fat, easily separated on all sides by an extensive and clean dissection, I know the case belongs to a group in which the outlook is bright, in which the per cent of cures is higher than 25 or 30 or even 50%."

This represents the best prognosis that surgery affords us, viz: that in cases operated on within two months after their onset (at which early period it is exceptional to have patients seek medical advice) six cases out of ten recover: or conversely, four out of ten die. In cases where a single metastasis to the axilla occurs, three in four will die and in comparison to the high mortality in the past, a recovery of one or two in four is considered a bright outlook.

The question naturally arises "Is there nothing that can be done after the operation to help?" or "Is there no method other than surgery?"

To meet this need various electrical and biochemical methods have been advocated. Among these may be mentioned

- Metallic Electrolysis
- X-Rays
- Radium
- Effulgeration
- Thermo-penetration
- Various serums, residue, etc.

In regard to the various electrical methods there is wide variances of opinion.

We are all aware of the favorable case reports that have been issued by advocates of these methods. If one is interested along these lines enough to go to certain clinics in Chicago (Pusey), Boston (Williams), Philadelphia (Pfahler, Leonard, Pancoast, Manges, Bowen, Massey), Cincinnati (Lange), Pittsburgh (Boggs, Johnston), Detroit (Vaughn), Toledo (Dachtler), he will hear well authenticated and enthusiastic reports of curative results and diminished post-operative mortality re-



cords, will see these cases and can observe their progress, will learn that the surgeons of these localities are strongly in favor of post-operative methods. Surgeons in some instances even refusing to operate on cases unless the patients agree to have post-operative treatments.

In other clinics, in other medical centers or for that matter in the same cities, the attitude toward these post-operative measures is non-committal or frankly opposed to them. Perhaps the explanation frequently offered that the enthusiasm for any method in a given locality varies directly with the technique of the specialists resident in that community: as well as the frequent statement of the relative scarcity of specialists with good therapeutic technique, have some truth in them and should not be too hastily discounted. All of these so-called newer methods have sincere advocates and are constantly used by physicians; their results and technique have been published, witnessed, and sufficiently attested, to warrant serious consideration. The substantiation of the real scientific value of therapeutic measures, however, must not rest on individual statistics, but on results obtained by users (other than the discoverers). The personal equation must be eliminated before a method can have any scientific standing.

Given the following premises:—(1) The need of some adjuvant to surgery in carcinomatous cases, (2) Methods which give any reasonable promise of relief; a logical conclusion indicated is:—a conscientious investigation of these methods at the hands of a commission of competent scientists, surgeons and physicians in some hospital where every refinement of technique, surgical, pathological, electrical, and biological is available. Such a commission in considering any methods should take certain definite steps:

(1) The thorough standardization of apparatus and technique, definitely based on the monographs of the best exponents of that method.

(2) The verification of this technique and its physiological action on animals with thorough pathological and physiological study of tissue and secretory changes.

(3) Diagnosis of cases treated to be confirmed.

(4) Accurate technique of application to the cases.

(5) Consent by patient to thorough histological observation.

(6) Complete report of results obtained.

## CONCLUSIONS.

1. Anything that promises reasonable help in cancerous cases should be thoroughly investigated and if found to be helpful should be established on a scientific basis.
2. Certain adjuvant methods, in certain experts' hands, have palliative and in some cases, curative action.
3. These methods do not enjoy the complete confidence of the medical profession in general.
4. It is authoritatively claimed that there are only a few experts who are successful in getting results by these methods-- (Article on Roentgenization, Journal A. M.A., in Department of Therapeutics.)
5. If this be true, it must be because of, (a)—a difficult technique which few men have the patience to acquire; or (b) inherent personal qualifications possessed by certain men only: the former would mean that these methods were based in science, the latter, that they were based in art.
6. A competent commission should investigate and report as to the scientific basis of these adjuvant methods.

THE ROENTGEN RAY AS AN AID IN THE DIAGNOSIS  
OF FRACTURED SKULLS.

BY DR. WM. H. STEWART, NEW YORK CITY.

The skull is described by Gray as "a superior expansion of the vertebral column as if composed of four vertebræ, the elementary parts of which are specially modified in form and size and almost immovably connected, for the reception of the brain and special organs of senses."

The structure of the skull with its double deck, of compact substance and intervening cancellated material, its bridging and trestling, its thickened protuberances at prominent and susceptible points, the peculiar dovetailing of the sutures, its shape and movability, all combine to make this casing for the vital structures resilient to external violence. It has, however due to lack of uniformity of thickness, weak points which are particularly susceptible to injury, these I believe to be over the parieto temporal regions.

Fracture of the skull itself subsides into secondary importance, the vital lesion being the amount of injury to the blood-vessels, dura and brain substance, but as a clue to the location of the serious lesion it is of utmost importance. For this reason I venture to bring to your attention the aid that can be rendered in locating these fractures by means of the Roentgen ray. In a hurried review of the English literature on the subject I failed to find one instance where the X-ray was used as an aid in the diagnosis of fractures of the skull. Most of the text books fail to even mention its use. The following statements by prominent surgeons illustrate how the ray may be used to advantage:

Scudder says, "It is not an uncommon experience for the surgeon to be called to an individual who is unconscious following a blow on the head. A swelling is evident on the top or side. Palpitation reveals a haematoma. **It is sometimes impossible to distinguish between a haematoma and fracture of the skull.**" Again he says: "A knowledge of the nature of the fracture will help in determining the injury to the brain—as a linear fracture of the vault with rupture of the middle meningeal artery."

Wm. Barton Hopkins states in his "Clinical Treatise of Fractures:" "A mere fissure in the vault of the cranium accompanied

by moderate and temporary symptoms of concussion of the brain will almost inevitably escape detection for no sign indicative of its existence can be felt through the scalp." Again he states: "If there is a wound leading to the seat of the fracture the *existence* of the latter being immediately revealed, its proper management may often be definitely determined upon without regard to the presence or absence of cerebral symptoms. It must be mentioned however, in qualification of this statement, that there are a certain number of fractures of skulls especially of limited areas, in which localization is of the inestimable value in indicating with extraordinary precision the site of the lesion, while as already stated, an intra-cranial lesion at any point may produce general symptoms identical in all respects with those due to fracture when such symptoms are present, fracture being the removable cause, it becomes *a matter of first* importance to prove or eliminate its presence."

John B. Murphy in "Practical Medicine Series for 1912," makes the following statement:

"Personally the author has been impressed with the frequency with which a patient with an apparently insignificant haematoma or laceration was admitted with a normal temperature and mentality, and yet careful examination would show a depressed fracture of the vault with more or less injury to the brain."

We are all conversant with cases where the fracture with a lacerated bleeding artery is remote from the point of injury; see the inestimable value of localization by the X-ray, in these.

The frequency with which fracture of the skull is mistaken for various other conditions, especially in cases of coma, calls for any method which will make a rapid and positive diagnosis. There are a number of cases of fracture of the skull in which the diagnosis can not be made except by the aid of the X-ray: I refer to those which have no symptoms, either objective or subjective, only a history of a fall. In some hospitals every patient who receives a blow on the skull or point of the lower jaw, either directly or from a fall, is considered as suffering from a fractured skull, unless proven otherwise. The signing of a release is always required when a patient desires to leave.

With the advent of warm weather comes the open windows, the use of the streets and yards as play grounds, and the roofs and fire escapes as sleeping places; these factors are the source



of many accidents in children, and common among them is the fractured skull. The elasticity of the bones of the skull in children is largely accountable for the rarity of basilar involvement, this is in marked contrast to this injury in adults, where authorities claim 80% of fractures of the vault extend into the base. The frequency of a serious fracture in small injuries of the head in children, and the apparent insignificance of such fractures has been often observed. That skulls of children fracture easily without injury to the brain or blood vessels is the conclusion, when there *is* some injury to the vital tissues the extensive nature of the fracture relieves the tension, in other words the child decompresses himself.

**Technique:** The patients are often in a comatous or irritable condition when referred to the Roentgenologist, and a great deal of patience and perseverance are required. It must also be borne in mind that the minimum amount of disturbance and movement is the rule. The head must be absolutely fixed and all respiratory movement must be overcome. If the objective symptoms, such as bleeding from the ear, laceration of the scalp, haematoma, or paralysis are present, they are a clue as to the possible site of the fracture, and your attention is naturally directed toward that region; this must not mislead you however, for every case should have both parietal and occipital regions radiographed. Where it is possible the laterals should be made without turning the patient on the side. In radiographing the occipital region the patient's head should be slightly raised, the tube placed at an angle of 15 degrees to the level of the plate, and centered at a mid point of the vertical plate of the frontal bone; a diaphragm with a diameter of six inches is used and care should be taken to keep the lower edge of your chimney just above the supraorbital ridge. Radiographs of the frontal region are not safely made by turning the patient on his face, and must be made with the tube beneath. However as fractures of the frontal region even with extensive laceration and loss of brain substance do not seem to be a serious injury, the examination can often be deferred until the patient is in better condition. Short exposures and rapid plates are of course the rule. A hypo of majendie where much irritability is present, will aid in obtaining a satisfactory examination.

I have selected a few typical cases for demonstration purposes which I desire to give brief histories of and show the radiographic findings:

**Case I.** R. N., U. S. Age 10. Admitted to Harlem Hospital on May 11th with the diagnosis of fractured skull. Said to have fallen into a subway excavation—a distance of from 6 to 8 feet. Examination shows a haematoma on top of the head to the front, with a small punctured wound just admitting a probe. Patient vomited copiously about one half hour after the accident—dazed and sleepy—no paralysis or convulsions—reflexes normal—on admittance some vomiting—marked nonurgent—slept well and apparently comfortable. May 12th—slight oozing from wound—vomited small amount of clear fluid. X-ray examination showed a sagittal fracture extending downward through the vertical plate of the frontal bone nearly to the supraorbital ridge. Wet dressing—slept well. Out on porch on May 14th. Convalescence uneventful. Discharged on release on May 22nd, 1911.

**Case II.** T. P., U. S. Age 10. Admitted Dec. 6, 1911, with a diagnosis of fracture of the skull. Patient while running across the street is said to have plunged head first in the “guard iron” of a street car. When seen was semi-conscious, verbal response was unobtainable. He presents an open wound over the left supraorbital ridge from which a reddish serous fluid containing brain tissue was discharging. On the way to hospital developed continuous twitching of muscles of face on right side and became very restless. Pupils equal and reacting. Depression and ridge of bone is palpable. Was taken to the operating room—wound cleaned and all loose and depressed portions of the bone removed. Post-operative X-ray findings show a complete absence of the left middle portion of the vertical plate of the frontal bone. Recovery uneventful.

**Case III.** C. S., U. S. Age 8. Admitted June 25, 1912. While playing the child fell from a shed roof, a distance of about 15 feet, striking on her head. Has been conscious and semi-rational ever since. Bled profusely from nose and mouth. Vomited just after the fall. Extensive fracture with considerable separation extending from left parietal across the frontal into the right parietal was found by the X-ray examination. Practically no symptoms. Case illustrated how the patient may decompress herself. Complete recovery.

**Case IV.** W. D., U. S. Age 17. Admitted Sept. 9th with a diagnosis of fracture of the skull. Patient fell three stories striking on his head on stone pavement. When seen was uncon-

scious, bleeding profusely from right ear. No convulsions or paralysis. Pupils equal, abdomen rigid. Regained consciousness on entering the hospital, quite restless. Sept. 10-11-12, noisy and restless, slept at intervals. Complains of pain and stiffness in neck. Rational at times. X-ray examination shows a forked linear fracture of the right parietal bone, low down, extending downward into the squamous portion of the temporal bone to the region of the external auditory canal. Gradual improvement. Discharged on Sept. 22nd, 1910.

**Case V.** T. S., Italy. 5 years. Admitted in Harlem Hospital on Oct. 4th, 1910, with diagnosis of fracture of the base. Said to have fallen off a fence to the court below striking on his head. When seen was irritable and stupid, bleeding from right ear. Some restlessness and crying for three days. X-ray examination revealed a vertical fracture of the right parietal bone extending downward into the region of the external auditory canal. Convalescence uneventful. Discharged on Nov. 4th on release.

**Case VI.** W. M., U. S. Age 16. Admitted Dec. 15th, 1911. Patient said to have been hit upon the head while watching several boys playing with dice. Implement used was a block of wood. When seen was conscious but dazed. Response to questions slow. A thin sero-sanguinous fluid was discharging from left ear. Pupils were equal and reacting. Vomited while in the admitting room. Examination of head reveals a small haematocoele on left side of head. X-ray findings "a long forked linear fracture extending from the upper left portion of the occipital downward and horizontally nearly across the left parietal, the lower fork extending downward and terminating in the external auditory canal. This case is remarkable in that he lost 38 oz. of cerebral spinal fluid in 21 hours. Recovery.

**Case VII.** C. H., U. S. Age 12 years. Boy fell from first story fire escape to the pavement striking on his head. When seen was very irritable—pulse slow with good tension—pupils equal but widely dilated. Bleeding freely from a lacerated scalp wound. X-ray findings, a long linear forward fracture of the right parietal extending horizontally and downward into the greater wing of the sphenoid. Recovery.

**Case VIII.** J. R., Ire. Age 40. Admitted Sept. 30th, 1911. Patient fell one flight of stairs, was picked up unconscious—some projectile vomiting with bleeding from both ears and nose, no external evidence of injury to the skull—location of

fracture uncertain—remained restless and irrational for three weeks. Some slight improvement. Oct. 23rd developed left facial paralysis—referred to X-ray department for diagnosis. Radiographic findings—a stellate fracture of the right squamous portion of the temporal bone. Oct. 28th, a right decompression operation performed, blood clot removed, X-ray findings verified. Recovery.

**Case IX.** M. C., U. S. Age 10. Admitted Nov. 23rd, 1910. Was hit by a car, when first seen was conscious, but in marked shock with rapid and feeble pulse and shallow breathing, has a depression of the skull with haematoma at occiput, contusions of the face, crepitus and false point of motion middle third of the left femur. Developed a convulsion, clonic in character in the ambulance and become unconscious. Spinal puncture on admittance, bloody serum withdrawn. Regaining consciousness became restless and fretful. Was fairly comfortable and slept well for the next few days. Except for some restlessness in the early convalescence recovery was uneventful. X-ray examination disclosed a fracture beginning high up in the occipital bone over the superior longitudinal sinus extending downward and to the right passing over the right lateral sinus and ending in the mastoid portion of the temporal. From about the middle of the lateral sinus a fork extends downward parallel and to the right of the occipital sinus terminating in the foramen magnum.

**Case X.** A. B., U. S. Age 11. Admitted Jan. 6th, 1911. Said to have been struck by a Madison Ave. car. Was picked up unconscious, bleeding from the nose, with eyes deviated. Remained unconscious and died on Jan. 9th. X-ray examination revealed the line of fracture beginning to the right of the sagittal suture in the right parietal bone, extending backward across the right lateral sinus, dividing, one going forward and ending in the mastoid portion of the temporal bone, the other downward into the foramen magnum.



## LABORATORY NOTES.

BY DAVID R. BOWEN, M. D.

**The Developing Tank.**

At our last meeting I presented a plan for negative development which was well received and which, I still believe, had considerable merit.

Not long after my return from Richmond I found, in the shops, a system using metal frames similar to the one I had described but of simpler construction and greater durability. In so far as this frame enters into the present plan I can claim no originality, except that it seems not to have occurred to the makers to adapt a single tank to the various sizes of plates.

This, doubtless because they have catered to portrait photographers who do not use the widely varying sizes.

I am using a soap-stone tank  $25\frac{1}{2}$  inches wide, 41 inches long, and  $23\frac{1}{2}$  inches high, outside measure.

Considerably smaller than the ordinary flat top desk, and in this tank is completed the whole process of developing, washing and fixing. I have the back side extended upward 12 inches to form a splash-board.

In some rooms this might be omitted. The tank is divided by partitions into six compartments.

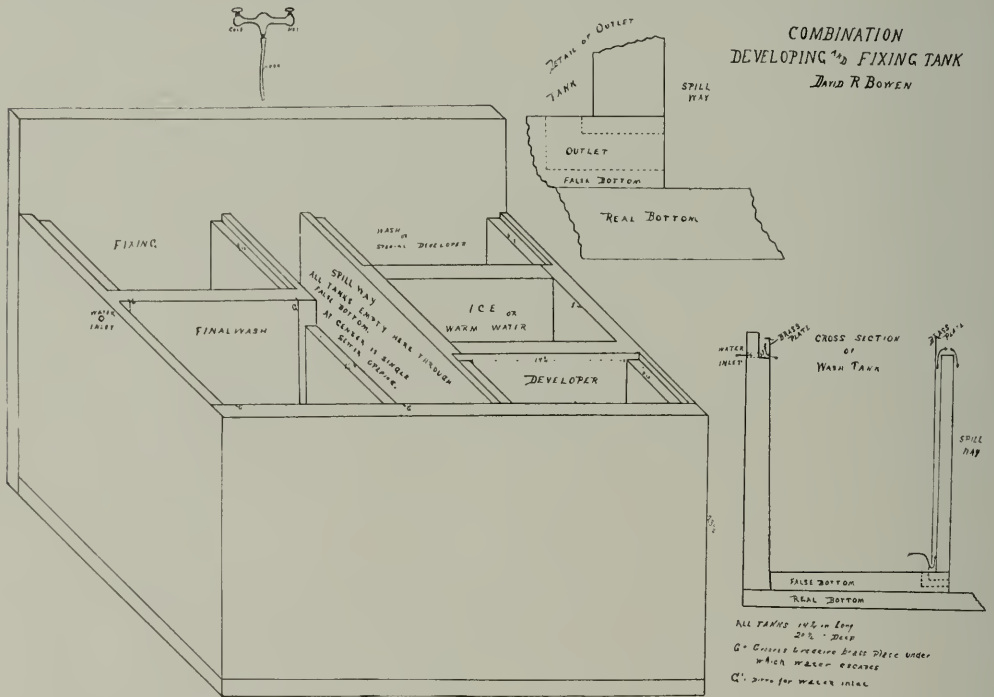
The middle one six inches wide extends from front to back and serves as a spill-way. Its bottom is  $1\frac{1}{2}$  inches lower than that of the other five and slopes toward a central opening which forms the single sewer outlet for the whole tank.

To the right are three tanks each  $14\frac{1}{4}$  inches long, 6 inches wide, and  $20\frac{1}{2}$  inches deep. With the exception of the middle one there is a recess  $\frac{1}{2}\times 1$  inches cut out across each end to receive the ends of the metal frames. The front one of these three is used for developer, the middle for ice, and the back was planned for the first wash, i. e. between developer and hypo. I think now I am more likely to use this for developer of a formula especially adapted for photographic plates exposed with the intensifying screen. On the left hand are two tanks of same length and width as those on the right. The back one, nine inches wide, holds the acid hypo. The front one, 12 inches wide has the running water.

The water enters behind, and is distributed under, a metal strip across the top at the left hand end.

By means of a metal plate at the right hand end, the water is made to leave from the bottom, thus a perfect circulation is secured from top to bottom.

The bottom of each of the five tanks being one and a half inches higher than that of the spill-way allows an opening (L-shaped in longitudinal section) by which each tank may be emptied and cleaned. These openings are closed by rubber plugs and no metal appears in contact with any of the solutions. Every part is readily accessible for thorough cleaning.



I have had some trouble with the fluctuation of the level of the developer when, for instance, one day's work happens to run all small plates and the next day mostly large ones. To overcome this, I am having a hole drilled in that tank at the normal level. To this will connect by about 18 or 20 inches of rubber tube the lower opening of a two quart douche bottle. When the developing begins the bottle, with its top vent open, rests below the level of the developer. When the level becomes too low the top vent of the bottle is closed and the bottle raised. The air pressure keeps the solution from flowing out when the opening is covered.

By this device the normal level can be maintained with a minimum of attention.

**Advantages.**—First, economy. The most valuable item about a Roentgen laboratory is time. The tank will accommodate 15 plates of all sizes. Thus the operation is at least 15 times as fast as by single tray.

Only a few of us are so fortunate as to have assistants to whom we are willing to delegate all of the developing, and what tray user can, on a hot afternoon, contemplate a stack of 30 or 40 plates with anything less than "that tired feeling." But developing has become a pleasure and I nearly always develop all the plates, leaving them in the fixing bath for the assistant to finish if I wish.

Having been prepared for a considerable increase in the expenditure for developer the actual decrease has been a surprise. Eight gallons of developer, costing about two dollars and used for four weeks in the month of July developed about 300 plates without a trace of dichroic fog. Considerably less than a cent per plate. The ice tank offers, I believe, the first real solution of hot weather problems. There has been no difficulty in keeping developer temperature at 68° F. or even below, when the coolest tap water was 82° F.

**Results.**—Economy of time, energy, space and material would after all be secured at too great cost if the final result is found to be in any way inferior. Tank development has not been popular. Various text-books mention or describe it but none recommend it, while some, as instance Luppó-Kramer, unqualifiedly condemn it.

It has seemed to retard the effect of the direct rays and to accelerate that of the secondary, giving results tending to flatness. This has been due largely, perhaps entirely, to extended treatment with dilute solutions. In this I am using full strength developer and the process is as rapid as by tray, while the exposure to air is far less, and plates are even more readily accessible for inspection or individual control.

The uniformity; the freedom from pinholes, scratches, and fog have been a source of continued gratification. There has seemed to be a more faithful record of shadows. Plenty of detail in bone without wiping out of the detail in the soft parts.

**Developer.**—I have used the regular Cramer developer as given with each box of Cramer X-ray plates, with the addition of potass. iodide, 7 gr. to the gallon. This is an absolute preventive of chemical fog. When shall the developer be renewed?

Certainly as soon as it is ever so slightly turbid. A considerable brown shade seems not to matter so long as the solution remains transparent.

The appearance of any trace of iridescence about the edge of a normally exposed plate is a signal for renewal. Roughly, changing once in 3 to 4 weeks is practical. A rack for holding the empty frames and another for drying plates in the frames are details that will work out differently in different rooms. Mine are illustrated as suggestions.

#### **As to Lighting.**

I have found a Ruby ceiling light with orange colored wall very satisfactory. For examination of plates during development a deeper ruby light at the eye level and operated by a foot-switch is convenient.

A white light over the fixing-bath permits the examination of plates there without trailing hypo "all over the farm."

#### **Stand For Eye-Localizer.**

Made of same height as radiographic table and on easy rolling casters. Can readily be moved to the end of the table and fastened by clamps or a tie.

Saves all handling of the localizer and makes it readily reversible for right or left eye.

#### **Dumb Waiter.**

A rolling stand similar to that for the localizer. but with draw and shelves for sand-bags, leadplates, diaphragms, shears, bismuth, adhesive, numbers, and, in short, all the little things. If the casters are right it will take only a little training to make it follow around like a faithful dog.

#### **Stereo-tunnel.**

No different in principle from that offered last year, but of 10x12 size and a full half inch opening.

Simply a metal envelope open at the side, the front being of aluminum and the reverse of brass, the two folded together at the three closed edges and bound with stiff wire at the open side.

Can readily be pushed under the draw-sheet to secure single or stereo-exposures of fractured hips without moving the patient from the bed. The weight of a heavy patient will not pinch the plate.


When the subject is not too heavy the plate can be put nearer to the skin by backing up with one or two old plates.



A PRIVATE X-RAY LABORATORY.

DESIGN AND PLAN BY E. H. SKINNER, M. D., AND H. P. WELLS,  
M. D., OF KANSAS CITY, MISSOURI.

This design and plan of a private X-ray laboratory is presented as a working basis and not as an actual possibility. It is an innocent amusement of the writers. Such a plan as presented here is not without the realm of possibility as far as the financial sanity of the scheme is concerned.



The building could be of cut stone or stucco with slight alterations in the exterior details. The interior allows of wide latitude of treatment to meet the requisities of any radiologist. Since the above plan was drawn Dr. Skinner has suggested that less space be devoted to the artistic treatment of the negative-viewing room in the center so that more and better provision could be provided for dressing rooms in conjunction with the fluoroscopic room. In the large charity hospital there is no need

of exquisite privacy for fluoroscopic patients. In private laboratories the lack of dressing rooms becomes embarrassing aside from the loss of time which is a greater consideration. This rapidly expanding field of X-ray diagnosis presents many problems in the private laboratory. The radiologist must consider the maintenance of ocular accommodation without interruption of interview or entrance and exit of other patients.

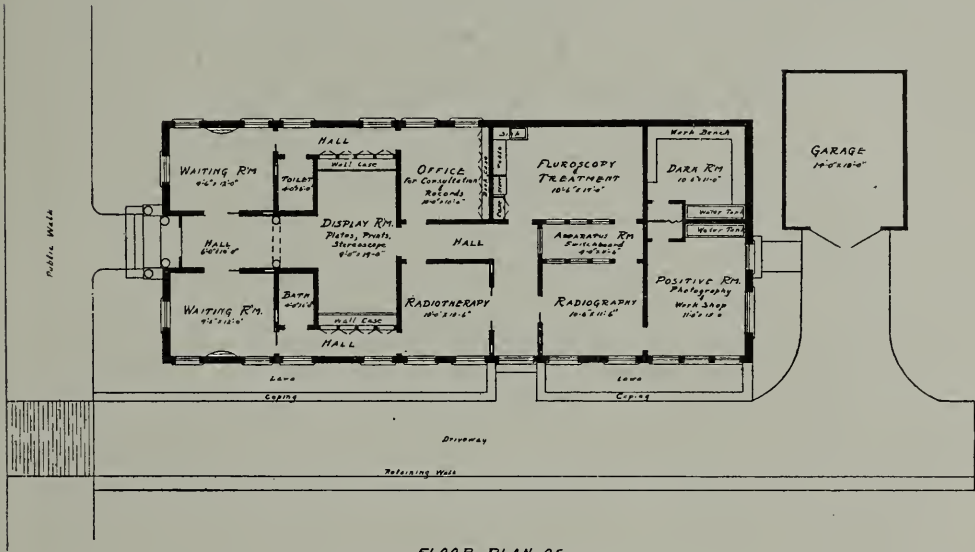


*Front Elevation  
of a  
Private X-Ray Laboratory  
Designs & Plans by  
Drs Wells & Skinner*

The detailed treatment of the laboratory may be briefly described as follows: Front of white stone returning on either side as shown in the prospective drawing; columns in front outside of cut stone with Ionic caps; window trimmings of same material, all woodwork throughout including floors in the various work rooms to be of oak or tile. All walls plastered with cement plaster and oil painted. Barrel arch in display room to be of colored art glass with a large skylight above. Lighting in all rooms to be by the indirect method, the lights being hidden behind a deep moulding, and reflected upward.

Columns and pilasters in front corridor to be of English veined Italian marble or colored marble. Main building structure to be of reinforced concrete with fire proof tile partitions. Cellular under entire building. Garage shown in rear to be of stucco on metal lathe or of composition stone treated in blocks to match the front of the building.

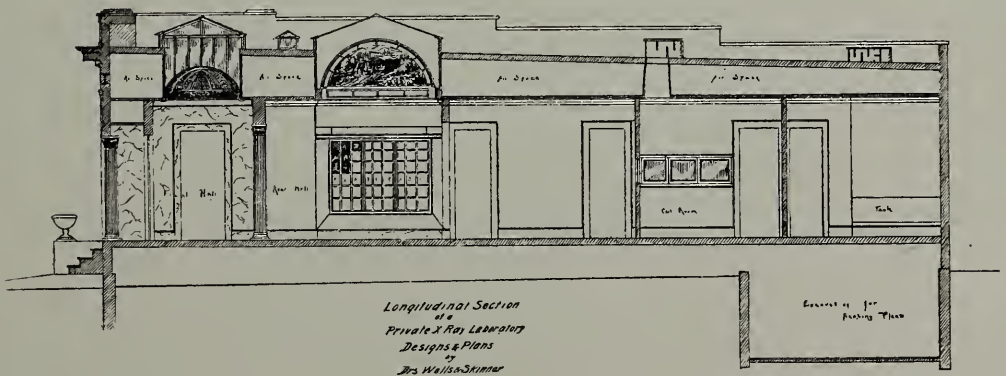
This little building could be placed in the middle of a 75 ft. lot so as to have some gardening effects about it. Greek torches on the parapet of the roof would be of verde antique bronze as



FLOOR PLAN OF  
PRIVATE X-RAY LABORATORY  
BY  
E. H. SKINNER, M.D.  
&  
H. P. WELLS, M.D.  
SCALE 3/16" = 1'

Drawn by  
E. E. Shepard  
310 Delaware Ave.

well as all the metal trimmings shown in the front elevations such as the front door gratings and the vent openings and the lamps.



This plant could be provided at a cost of approximately \$20,000.00, in a favorable location in any city where the volume of work would warrant the expenditure of \$1200.00 in yearly rental or 6% upon the original investment. In cities where the

majority of consulting physicians are located in office buildings in the down town districts the feasibility of such a building as this is questionable as ground values are too high. The elegances of such X-ray appointments would however be attractive and there is every reason why the radiologist housed so pleasantly could be of greater value to his clientele and happier with his work.



DEMONSTRATION OF A SAFE AND PRACTICAL  
METHOD OF COMBINING FLUOROSCOPY  
WITH RADIOGRAPHY IN ABDOM-  
INAL DIAGNOSIS.

BY DR. PAUL EISEN, OF MILWAUKEE.

The radiographic method, if used alone, either in series of direct or sets of stereoscopic views of the abdominal viscera made visible by inflation of air or instillation of some contrast showing material, gives at best only the anatomy, the position, size, shape, outline and correlation of the organs, and that under conditions that obtain only during the time of exposure, conditions due to posture, tension, nerve control abdominal pressure and many other temporary factors. Even to cinematographic series this holds good to a certain degree, although their demonstration shows, besides, the whole physiologic or pathologic action, peristalsis, antiperistalsis, retrogression, etc., better and sharper in outline than the eye can hold fast; on the other hand, besides the above mentioned temporary factors, the latter method bars all manipulations with the patient which the roentgenologist finds of value to aid him in coming to a radiologic diagnosis. Where manipulations are impossible, fluoroscopy can be dispensed with. The radiologic diagnosis can then be considered with the clinical findings, and a medical diagnosis may be formed. This again can be furthered by findings found at operation, making a surgical diagnosis, and the pathology, if not at autopsy, can be pretty accurately established; to attempt an etiologic or pathologic diagnosis from X-ray findings leads often to disreputable mistakes. So much for the still existing need of doing fluoroscopy in abdominal cases.

To meet this need, some excellent apparatus have been devised, notably by Albers-Schonberg, Haenisch, Holz knecht, Schwarz and Koehler; in combining directly the fluoroscopic examination with radiography, we derive all the benefits of the cinematographic method without encountering its shortcomings, notably manipulations with the patient. The different kinds of apparatus are mostly foreign make and out of reach of most

American roentgenologists, whereas a simple device that I have thought out, makes of the Kelley-Koett Stereoscopic Tube Stand No. 6 which many of us have, a safe and efficient apparatus. Besides being simple, it is built on correct principles and has advantages not to be found in any other foreign make or type. I know and have seen no apparatus that is absolutely safe, at any rate I make no such claim for this type.

The danger in fluoroscopy comes from three sources, firstly from the tube direct: these rays can be guarded against absolutely; secondly those rays passing through the lead glass in front of the fluorescent screen; these are safely guarded against by using the right kind and quantity of current; thirdly those secondary rays emanating from the patient; these rays one must guard against by wearing lead rubber gloves, if not using a Holzkecht distinctor, and a lead rubber apron, at least of 1/16 inch, 2mm thickness and enveloping the body well. My apron weighs 10 pounds. In testing for penetrated or vagrant rays with a fluoroscope, I have found none that I could detect after thorough accommodation in the dark. But the actual danger must be not so great, as I have worked with far less protection for the last five years and have noticed no harm either to my skin or to any internal organ.

To begin with the proper source of current, it had best not be in connection with a WEHNELT interrupter whose number of interruptions one can not control, but either, as abroad, in connection with a mercury interrupter or from a transformer. In the last case the transformer must be built suitably; I own a 220 volt 2 K. W. Kny-Scheerer "Ideal" of Reiniger, Gebbert & Schall type in which I have cut down the stationary segments of the rotary converter from 9 to 3 inches; with 1800 revolutions I have 3600 breaks; the voltage stays stationary, must cover a 6 inch spark gap to get the necessary penetration of the tube of 6 Benoist or 8-9 Wehnelt, while the amperage or amount of current need not exceed more than 1-2 milliamperes for fluoroscopy, while in radiography I put the whole output of the machine through the tube after lowering its vacuum suitably; this is necessary in using an intensifying screen.

The tube should therefore be one that can be lowered and brought up quickly; until lately I have found old re-exhausted

Green & Bauer tubes of a high vacuum suitable, but I have derived better and more reliable service lately from Mueller's water cooled tube Rapid with either a Queen or Heinz Bauer reducer, filling the tube with fresh icewater after each exposure bringing it up quickly for further fluoroscopic work. With proper accommodation of the eyes, having beforehand only a blue light burning, and waiting in the dark at least five full minutes, the main difficulty is overcome.

The points to consider in fluoroscopy and its combination with radiography are two: first and foremost *safety* to the patient as well as to the roentgenologist, and secondly an apparatus built on technically correct lines, at the same time allowing ready access to the patient, making any manipulation of him or change of position easy, with the regulating device for the tube at hand, and appliances for bringing the tube and plate holder or screen in focus, as well as interchanging them, in handy and quick reach.

Of the three sources of dangerous rays, those coming directly from the tube, excepting those passing the diaphragm, I believe to have cut these out by re-enforcing the lead glass protection shield by a hood of lead rubber, 2 mm or 1/16th inch thick, fastened over the shield and tube with hemp cord, soaked in paraffin, covering all parts effectually. With the small amount of current in use in fluoroscopy, there are surely not many rays escaping, at least none that I could discover with a fluorescent screen; maybe some might escape, though. Lead rubber I have found by photographic test of far better protection than lead glass of much greater thickness: The hood is seen covering an 8 inch Mueller tube, the bowl, tube and saddle weighing together 20 pounds, 8 pounds more than a 7 inch tube and bowl without a rubber hood, the difference in weight being due mainly to the glass. The hood at the same time cuts out all green light. It does not help puncture the tube.

One of the great advantages in using this stand for both fluoroscopic and radiographic work lies in the fact that one can use, instead of the different types of adjustable or shifting diaphragms, the different sized and shaped cones with suitable diaphragms that go with the stand. The cones insure uniform and safe distance of the patient's skin surface from the surface

of the tube. The opening is easily capped by a leather hood or sheet of aluminum, 3 mm thick, cutting out all soft rays from both the patient and operator, besides decreasing the rayed area of the patient's skin. The cone further allows an area of only 9 inches diameter from reaching the plate or screen-holder, ensuring equal safety to the operator. The cone cuts out all side rays far better than any built diaphragm can, the side lights being especially undesirable; at the same time it gives the object a sharper definition, bringing it automatically in the middle of the focus of the central rays. These advantages are increased by the possibility of using 10x12 inch plates and intensifying screen, and a fluoroscope of only 7x9 inch dimensions, making work and apparatus inexpensive and handy, besides encouraging taking more views, as developing incurs less time and money than with the large plates. It can hardly be called a great disadvantage, not to get the whole abdomen on one plate, but where this is valuable, as in a case of mine where a retroperitoneal tumor displaced all the viscera, a total view was facilitated by knowing beforehand what to focus for. The same holds good for taking stereoscopic views with a rapid changing plateholder, while two stereoscopic views within 10 seconds can easily be accomplished with this stand.

The main advantage of this arrangement is in the plateholder; to accomplish the combining of the two methods of examination, all I had to do was to fasten permanently, with 4 screws, a plate of lead glass, 4-5 mm thick, underneath resp. in front of the metal frame of the plateholder, which leaves a space, half an inch wide, between the lead glass plate and the sheet of aluminum covering. In this space one can easily slide and quickly focus another piece of lead glass of the same thickness, on the back of which is pasted a piece, 7x9 inches of a fluorescent screen. This whole plate of glass and screen can then be quickly exchanged, for radiography, by an envelope, slid in sidewise, containing a 10x12 photographic plate and metal backed intensifying screen, well wrapped up in black paper and black envelope. The plates of lead glass are not of uniform thickness, but taper from 5 to 4 mm, making together about 9 mm thickness. This affords sufficient protection with all but very stout patients, where, in examining especially the coecal region, more current is required. But one is protected by the apron. The



patient can use a little compression, standing against the aluminum sheet, and to ensure close contact between plate and screen, card board is shoved in between lead glass plate number 1 and envelope. The advantage of this plate and screen-holder is that it is correctly and quickly focused for both direct and stereoscopic views, having the object in the center of the focus, besides being stable during all manipulations with the patient, or with the patient once in the desired position, while interchanging the fluorescent screen with the photographic plate, at the same time shielding both from any moisture or warmth coming from the patient, through the interception of the aluminum sheet. For the upright position, the patient standing on a foot stool, 10 inches high, in examining the right side, the patient's arm is on the other side of the horizontal bars, for the left, the tube holder and screen are pulled out to left and focused, the only disadvantage coming with having patient lie on either right or left side on a board, as shown in Albers-Schoenberg or Skinner's apparatus, for which position the plate holder is removed from the stand and placed upon the board underneath the patient; with the patient reclining, the plate holder is replaced, all parts being reversed. The stand allows for the tube and plate holder to move up and down in unison, it moving downward of its own weight in releasing the screw, following in this way the ingestion of food as easy as "rolling off a log." In males I have even, with little difficulty, watched the filling of the intestines per rectum with the man standing, in women or the very sick, the reclining position is more appropriate, the patient lying on a high canvas-topped table with ball-bearing feet.

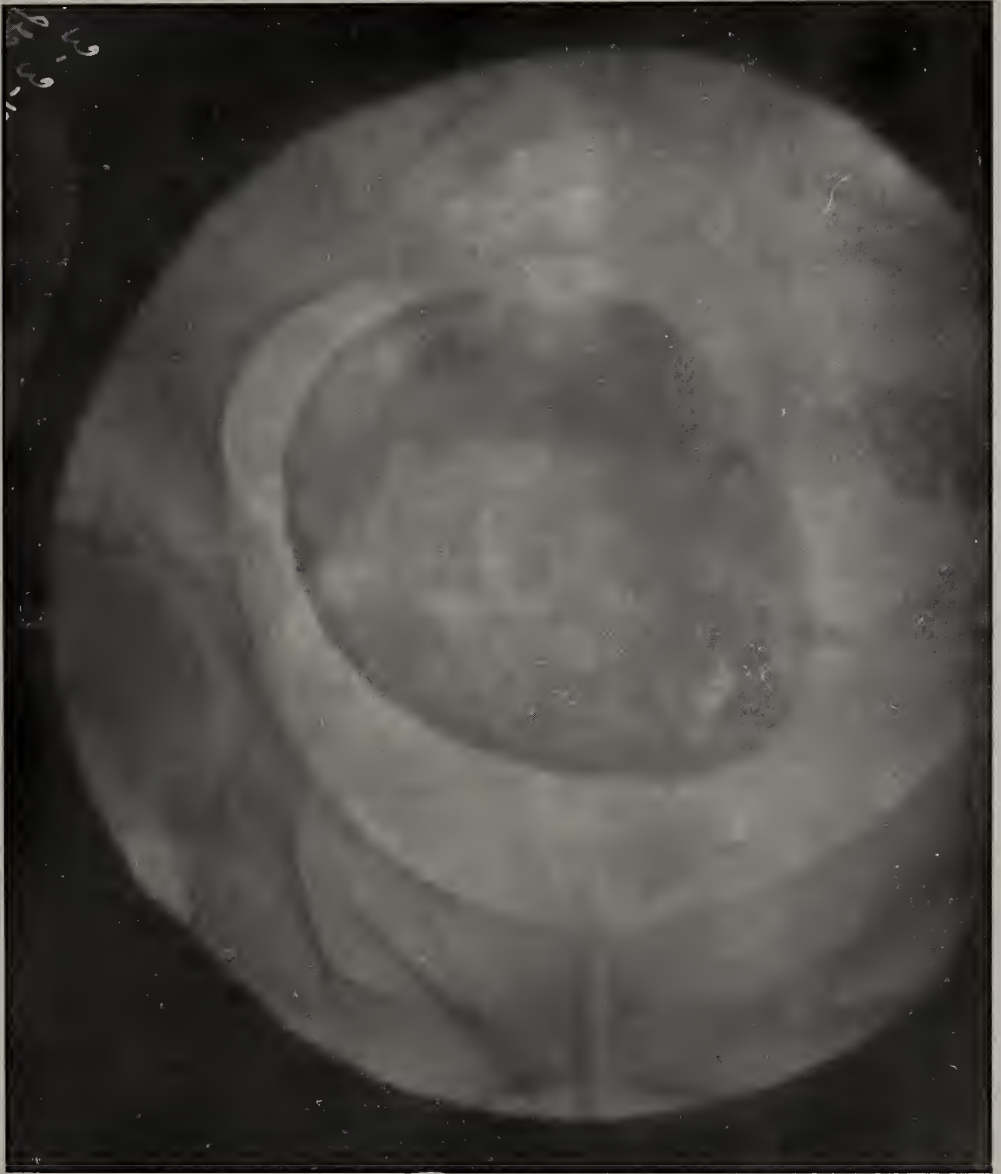
For turning the current on and off during the fluoroscopic examination, I need assistance, while the radiography I attend to personally, mainly for protection's sake, being shielded in my lead room. Watching the fluoroscope during radiography is a dangerous and besides needless procedure.

In closing, I may state that my demonstration has shown a technically correct and practical apparatus for combining fluoroscopy with radiography in abdominal diagnosis with as much safety as is possible in doing any fluoroscopic work of value to a diagnostician.

Note: It was not my intention to recommend any particular

type of apparatus, in fact, Mr. Kelley gave me no encouragement when I asked him for his assistance, I had in mind only to point out, in an apparatus, the essential points that are necessary to successfully employ both the fluoroscopic and radiographic methods in abdominal diagnosis.

121 Wisconsin Street.



Calcified Uterine Myoma  
Harry Dachtler, Toledo, Ohio





## POEMS

Written by Caroline Bartlett Crane for a dinner given at her home  
to a number of visiting roentgenologists

## THE CHAMPION INTERRUPTER

You're "rid of interrupters"?  
Not so; there's one that stays,  
And useless seems the struggle  
To tame its fractious ways.  
'Twas first, 'tis last, in office,  
Its hold you may not break;  
'Tis not electrolytic  
Nor mechanical in make;  
'Tis not a Wehnelt, Caldwell,  
Nor yet a mercury jet—  
(I think you'll surely guess it,  
So I won't tell you yet);  
'Tis not a flashing cartridge  
Nor a magnetic choke—  
(Oh, now, I'm quite in earnest;  
*Don't* think this is a joke!)

The while I sing its greatness  
I'd like to smash it small,  
But then, you'll own, such tactics  
Would never do, at all!  
And so I growl its praises:  
It worketh day and night—  
This wondrous interrupter  
Of unexampled might!  
And every doctor has it  
And it grips him for his own;  
*How* it interrupts, ah, heavens!  
'Tis—the *Doctor's Telephone!*

O Wappler, Waite and Bartlett,  
O, Snook and Scheidel, too,\*  
I'd set your souls on fire  
With something *great* to do!  
Step-up, step-down transformers  
Are useful in their place,  
But the way you dodge your duty  
Is surely a disgrace.  
Spring, summer, fall and winter,  
One need stands out alone,—  
One cry: 'Tis for an Inter-  
Rupterless Telephone!

---

\*With apologies to Others. They wouldn't meter—in verse!

## THE CALL TO DINNER.

My friends, I hate to seem abrupt  
 And I deplore to "interrupt,"  
 To pry your stereoscopic eyes  
 From off the inner mysteries;  
 But, Sirs, to reason I appeal;  
 Is there no vacuum you *feel*?  
 When the thrice-smitten dinner gong  
 Falls on deaf ears, there's something wrong.  
 I view you with an anxious eye—  
 What if your vacuums run *too* high  
 And puncture or collapse befall?  
 Beware, I cry you, one and all.

Poor souls, unto my warning hark;  
 The coil that gives the fattest spark  
 Must guard its precious insulation;  
 In my opsonic estimation  
 You're softening down—without your ration!

Do you, by some sad mental hitch  
 See only when you throw the switch?  
 Must all appeals to you be sung  
 In that alluring Roentgen tongue?—  
 The dinner gong's in English rung.

Where's the transformer of such worth  
 'Twould firmly step *you* down to earth?  
 What prime conductor could assume  
 To lead you towards the dining-room?  
 Oh, for a "ground" that should convey  
 All volts and amperes far away!  
 Oh, for the luck of burning fuse,  
 And not another you could use!  
 Oh, for minds sane and water-cooled,  
 By prudent counsels to be ruled!  
 Ah! did I dare, I would aspire  
 To be your psychic rectifier  
 And make the currents of your thought  
 Face right about the way they ought!  
 Deluded souls, I sweetly pray,  
 Lead-screen your brains and slip away  
 From these enthralling rays that cheat  
 Your days and nights, and

*Come and eat!*

## AN UNFAIR ADVANTAGE.

What topsy-turvey men, alas!  
 Who better see through wood than glass!  
 And, given a Merry Widow hat,  
 Show but the wires and pins of that!  
 And are your fluoroscopic eyes  
 To *all* our foibles just as wise?  
 You "see through us," 'tis my belief,  
 Shoe-pegs to unerupted teeth!  
 What if no pericardium stays,  
*Outside* the heart, your wizard's gaze!  
 Then shall your new mysterious ray  
 Snatch all *our* mystery away!  
 You scare us so that we would fain  
 Go hide behind—a window pane!

## CONSTITUTION

As Revised and Adopted by the Society, October, 1910, and with  
Amendments Added as Adopted September 20th to  
23rd, 1911, and September, 1912

---

### ARTICLE I.

NAME: The Society shall be known as the American Roentgen Ray Society.

### ARTICLE II.

OBJECT: The object of the Society shall be the study and the Practical Application of the Roentgen Rays.

### ARTICLE III.

SECTION 1. The Members shall be Active, Corresponding, Honorary and Associate, and shall be persons interested in the object of the Society, recommended by at least two members in writing, and approved by the Executive Committee, who must have proof of their good ethical standing. They shall be elected by ballot.

(See Resolution passed by three-fourths vote of the Society, September 23, 1911, prescribing new requirements for the eligibility of all applicants for *active* membership in the Society.)

SECTION 2. Active members shall be residents of America, shall sign the constitution, and pay annual dues of ten dollars (\$10.00), which sum shall include the subscription to the "American Quarterly of Roentgenology."

SECTION 3. No member who is in arrears for annual dues shall vote, hold office, or be entitled to receive the transactions. It shall be the duty of the Treasurer to erase from the roll of membership the name of every member who is in arrears for one year, thirty (30) days after the receipt of a registered letter by said member, such action to be reported at the next annual meeting for confirmation.

SECTION 4. Corresponding members shall be residents of foreign countries.

SECTION 5. Honorary members shall be persons who have distinguished themselves in Roentgen Ray research of practical work.

SECTION 6. Associate members shall be persons who are interested in the advancement of the Roentgen Ray, but who are not actively engaged in radiographic or radiotherapeutic work, whose membership is not otherwise provided for. They shall be required to pay annual dues of ten dollars (\$10.00), which sum shall include one subscription to the "American Quarterly of Roentgenology."

SECTION 7. Corresponding, Honorary and Associate members shall have all the privileges of Active members, except to vote and hold office.

#### ARTICLE IV.

##### Officers.

SECTION 1. The officers shall be a President, First and Second Vice-President, Secretary, Treasurer, Librarian, and Executive Committee of three, and a Board of Censors which shall consist of the three last living ex-Presidents. The officers shall be elected annually by ballot. (See Section 5, Article V.)

#### ARTICLE V.

##### Duties of Officers.

SECTION 1. The President shall perform all the duties pertaining to that office, and shall deliver an address during the annual meeting.

SECTION 2. In the absence of the President, one of the Vice-Presidents shall preside.

SECTION 3. The Secretary shall keep or cause to be kept, a correct record of all transactions of the Society in a permanent form. He shall send due notice of all meetings to each member, shall notify all members of committees of their appointment and of the duties assigned to them. He shall conduct the correspondence and perform all duties usually pertaining to his office. The Secretary shall have printed an alphabetically arranged list of members of the Society, with their addresses, for free distribution to members applying for same, which list shall be revised from time to time, and shall specify Charter members.

SECTION 4. The Treasurer shall receive and be accountable for all money that shall come into his hands by virtue of his office. He shall give good and sufficient bond to the Executive Committee for the safe keeping and disposal of his trust, and shall make a full report to the Society annually. He shall pay out money only by the written approval of the President and Chairman of the Executive Committee.



SECTION 5. An Executive Committee of three members shall be elected as follows: one for three years, one for two years, and one for one year; and thereafter, one annually to serve for three years, and the new member of the Executive Committee to be elected by ballot, the polls to be open at the Registration Bureau for twenty-four hours, and the one receiving the highest vote to be declared elected. They shall hold the bond of the Treasurer, audit his accounts annually, arrange for annual meetings, have general supervision of the affairs of the Society not otherwise provided for, and shall transact the business of the Society.

SECTION 6. A Board of Censors, consisting of the three last living ex-Presidents, the senior of whom shall be Chairman, shall consider all matters pertaining to the conduct of the Society, and after due consideration and investigation of complaints, if it appears to be misconduct, they shall communicate with the member in question. Upon a continuation of the misconduct they shall refer the matter to the Society at the next annual meeting for further action.

## ARTICLE VI.

### Meetings.

The annual meeting shall be held on the Wednesday following the second Tuesday of December of each year, unless otherwise arranged by the Executive Committee.

## ARTICLE VII.

### Publications.

SECTION 1. A Standing Committee of Three, to be known as the Committee on Publication, shall have full charge of the publication of the Proceedings of the Society. One member shall be elected to serve one year, one two years, and one three years, and thereafter one member shall be elected annually to serve three years. The members of this Committee shall be nominated at the annual meeting by the Nomination Committee and elected by the vote of the majority of the members present at such annual meeting. The President, Secretary and Chairman of the Executive Committee shall be members *exofficio* of this Committee. This Committee shall appoint the Editor of the "American Quarterly of Roentgenology."

## ARTICLE VIII.

### Amendments.

This Constitution may be amended by a three-fourths vote of all the members present at an annual meeting, provided the proposed amendment has been read before the Society at least one day previously, and the hour for action has been set by the Society and announced in open meeting at least one day previously.

RESOLUTIONS ADOPTED BY THE SOCIETY FOR THE PURPOSE OF PRESCRIBING THE MANNER IN WHICH CERTAIN OF ITS AFFAIRS SHALL BE CONDUCTED, WHEN SUCH EXIGENCIES HAVE NOT BEEN SPECIFICALLY PROVIDED FOR IN THE CONSTITUTION.

1. Requirements for Membership.

(1). Form of Application Blank to be used for the purpose of furnishing the Executive Committee with necessary data concerning the applicant, and for the purpose of Society Records:

Application for Membership in the American Roentgen Ray Society.

Date.....
Name .....
Age ..... Birthp'ace .....
Residence .....
Medical Degree obtained at.....
Collegiate or other Degrees.....
Served as Interne in the following Hospitals.....
Years in Practice of Medicine..... Years in Practice of Roentgenology..... Preliminary knowledge of and training in Roentgenology obtained where?.....
Extent of practice outside of Roentgenology.....
Other specialties practiced.....
Present Hospital and Medical College connections.....
Membership in Learned Societies.....
Bibliography .....
Signature.....
Proposed by—
Signature.....
Signature.....
Approved by Executive Committee—
Signature.....
Signature.....
Signature.....

This application must be signed by two members in good standing in the Society, and acquainted personally with the applicant, it must be accompanied by letters of recommendation from:

(a) Those who sign.

(b) At least one practicing physician or surgeon in good standing residing in the applicant's immediate vicinity.

(2) An applicant for ACTIVE membership must have been a graduate in Medicine, and have been engaged actively in X-Ray work for at least two years after his graduation, and must submit a Scientific Paper on Roentgenology to the Executive Committee, which, if approved, may be published in the Proceedings of the Society.

(3) Applications must be sent to the Chairman of the Executive Committee at least six months before the next meeting at which they are to be acted upon. He shall publish, or cause to be published, the names and addresses of such applicants, together with the names of the members proposing them, either in the Quarterly or by personal letter to each member of the Society, at least once before the next meeting at which the names of the applicants are to be acted upon. Any objections held by members against such applicants should be sent to the Chairman of the Executive Committee as soon as possible for filing.

(4) The names and addresses of such applicants, together with the names of the members proposing them, shall be publicly read before the Society before they are acted upon by the Executive Committee.

(5) The Executive Committee shall have the power to hold over for further consideration any applications that are: (a) not made public according to the manner above prescribed; or, (b) not entirely satisfactory to the Committee, or for the reason of furnishing insufficient data.

(6) The Executive Committee shall have the power, as heretofore, to reject any application upon which they find good reason not to report favorably.

(7) Applicants shall be accorded the privilege of attending scientific sessions of the meetings as guests of the Society.

The above Resolution was reported to the Society by the Executive Committee, and adopted by a three-fourths vote of the active members of the Society present, after fulfilling all of the requirements prescribed by the Constitution for the adoption of a Constitutional Amendment. September 23, 1911.

#### BY-LAWS.

1. A Nominating Committee of three shall be appointed by the President on the next to the last day of the meeting. Said Committee shall make report on the last day of the meeting.\*

\* See Constitution, Article V., Section 5, and Article VII.

2. The newly elected officers shall take office at the close of the last day of the meeting at which they are elected.

3. All matters of parliamentary usage not already provided for, shall be decided according to Robert's Rules of Order.

4. Papers shall be limited in reading to twenty minutes. Openers of discussion shall be allowed ten minutes, and all others five minutes. No person shall speak twice on the same subject except by permission of the meeting.

5. A member found guilty of reprehensible conduct may be expelled from the Society on recommendation of the Executive Committee, and by a two-third vote of members present.

6. THE ORDER OF BUSINESS SHALL BE—

- (1) Call to Order.
- (2) Reading of Minutes.
- (3) Unfinished Business.
- (4) Reports of Committees.
- (5) Election of Members.
- (6) New Business.
- (7) Announcement of Nominating Committee by the President, or Report of the Same to the Society.
- (8) Reading of Essays.

---

**LIST OF MEMBERS OF THE AMERICAN ROENTGEN  
RAY SOCIETY.**

May 1, 1913.

Abell, A. J.....	Syracuse, N. Y.....	630 University Block
Adair, J. W.....	Marion, Ohio	
Albee, F. H.....	New York .....	125 West 58th St.
Ashbury, Howard E....	Baltimore, Md.....	1017 Cathedral St.
Baetjor, Frederick H....	Baltimore, Md.....	4 East Madison St.
Barsness, Nellie M.....	St. Paul, Minn.....	419 East 10th St.
Beck, Emil .....	Chicago, Ill.....	2632 Lakeview Ave.
Bergman, A. P.....	New Haven, Conn. ....	157 Bradley St.
Bierwirth, J. C.....	Brooklyn, N. Y.....	253 Henry St.
Birdsall, Edgar .....	Glen Falls, N. Y.....	Colvinn Bldg.
Boggs, Russell H.....	Pittsburg, Pa. ....	315 Empire Bldg.
Bowen, Chas. F.....	Columbus, Ohio .....	125 S. Grant Ave. or care Grant Hospital
Bowen, David R.....	Philadelphia, Pa. ....	3 South 44th St.
Brady, E. T.....	Roanoke, Va. ....	1232 Clark Ave., or Watt & Clay Bldg.
Brosius, Wm. Lewis....	Gallatin, Mo. ....	200 S. Market St.





- Grier, G. W. . . . . Pittsburgh, Pa. . . . . 519 Jenkins Bldg.  
 Groover, Thomas A. . . . . Washington, D. C. . . . . 1410 M St., N. W.  
 Hagopian, Mugur . . . . . Philadelphia, Pa. . . . . Garretson Hospital, or  
 613 Perry Bldg.  
 Hamilton, Wilbur S. . . . . San Antonio, Tex. . . . . Moore Bldg.  
 Hammond, Roland . . . . . Providence, R. I. . . . . 266 Benefit St.  
 Hartung, Adolph . . . . . Chicago, Ill. . . . . 31 N. State St.  
 Hatch, Edward S. . . . . New Orleans, La. . . . . Maison-Blanche Bldg.  
 Hazen, Charles M. . . . . Bon Air, Va.  
 Heberding, John . . . . . Youngstown, Ohio . . . . 11 W. Federal St.  
 Heck, Stanton . . . . . Salem, Ohio  
 Herbert, Edward . . . . . Fall River, Mass. . . . . 140 Purchase St.  
 Hett, J. E. . . . . Berlin, Ontario, Canada. 115 King St.  
 Heublein, A. C. . . . . Hartford, Conn. . . . . 42 High St.  
 Hickey, Preston M. . . . . Detroit, Mich. . . . . 32 Adams Ave. West  
 Hill, Walter C. . . . . Cleveland, Ohio . . . . . 533 Osburn Bldg.  
 Holding, Arthur F. . . . . New York, N. Y. . . . . 103 Park Ave.  
 Holmes, G. W. . . . . Brookline, Mass. . . . . 11 Wellington Road  
 Hopkins, William H. . . . . Geneva, N. Y. . . . . 40 Park St.  
 Hoyt, Charles W. . . . . Rochester, N. Y. . . . . 50 Westminster Road  
 Hull, T. A. . . . . Troy, N. Y. . . . . 3 Union Place  
 Hulst, Henry . . . . . Grand Rapids, Mich. . . . 100 Fountain St.  
 Hunter, James W., Jr. . . . . Norfolk, Va. . . . . 221 Dickson Bldg.  
 Imboden, Harry M. . . . . New York City . . . . . 480 Park Ave.  
 Jaches, Leopold . . . . . New York, N. Y. . . . . 27 East 95th St.  
 Jannsen, J. S. . . . . Milwaukee, Wis. . . . . 128 Wisconsin St.  
 Jennings, Curtis H. . . . . Fitchburg, Mass.  
 Johnston, George C. . . . . Pittsburgh, Pa. . . . . 8047 Jenkins Arcade  
 Kast, Ludwig . . . . . New York City . . . . . 771 Madison Ave.  
 Lange, Sidney . . . . . Cincinnati, Ohio . . . . . 22 West 7th St.  
 Leaming, Edward . . . . . New York, N. Y. . . . . 33 West 67th St.  
 Leonard, Charles Lester. Philadelphia, Pa. . . . . 112 South 20th St.  
 Le Wald, L. T. . . . . New York, N. Y. . . . . Gibbs X-Ray Laboratory,  
 338 East 26th St.  
 Lindenmuth, E. O. . . . . Indianapolis, Ind. . . . . 427 Bd. of Trade Bldg.  
 Lothrop, E. P. . . . . Buffalo, N. Y. . . . . 153 Delaware Ave.  
 McCollin, S. Mason. . . . . Philadelphia, Pa. . . . . 1823 Arch St.  
 Mackee, G. M. . . . . New York, N. Y. . . . . 58 West 58th St.  
 MacMinn, C. A. . . . . Schecnectady, N. Y. . . . . 5 Park Place  
 Manges, Willis F. . . . . Philadelphia, Pa. . . . . 264 South 16th St.  
 Marsh, James P. . . . . Troy, N. Y. . . . . 1828 5th Ave.  
 Martin, J. M. . . . . Dallas, Texas . . . . . 312 Wilson Bldg.  
 Maurer, J. M. . . . . Washington, Pa. . . . . 97 W. Wheeling St.  
 Means, Hugh J. . . . . Columbus, Ohio . . . . . 715 N. High St.

- Meisenbach, Roland O...Buffalo, N. Y.....140 Allen St.  
 Meter, Edward G.....Reading, Pa. ....948 Penn St.  
 Mick, W. H.....Omaha, Neb. ....476 Branders St.  
 Miller, Albert G.....Philadelphia, Pa. ....2150 North 21st St.  
 Morton, William J.....New York, N. Y.....19 East 28th St.  
 Nadler, A. G.....New Haven, Conn.....377 Orange St.  
 Newcomet, William S...Philadelphia, Pa. ....3501 Baring St.  
 Olmstead, Ingersoll ....Hamilton, Ont., Canada.215 James St. South  
 Ormsby, Oliver S.....Chicago, Ill. ....100 State St.  
 Osgood, Alfred T.....New York, N. Y.....40 East 41st St.  
 Pancoast, Henry K.....Philadelphia, Pa. ....University Hospital,  
 3400 Spruce St.  
 Peabody, C. M.....South Orange, N. J.  
 Perry, P. C.....Jacksonville, Fla. ....210 Laura St.  
 Pfahler, George E.....Philadelphia, Pa. ....1321 Spruce St.  
 Pirie, Alexander HowardMontreal, Canada .....Royal Victoria Hospital  
 Potter, Hollis E.....Chicago, Ill. ....150 Michigan Ave.  
 Quimby, A. J.....New York, N. Y.....40 East 41st St.  
 Quimby, W. A.....Wheeling, W. Va.....Schmulbach Bldg.  
 Rasely, Edwin R.....Uniontown, Pa. ....80 East Main St.  
 Reu, Leonard .....Buffalo, N. Y.....1104 Main St.  
 Rogers, Carey P.....Jacksonville, Fla.  
 Rupert, Theodore D....Geneva, N. Y.  
 Schaeffer, C. D.....Allentown, Pa. ....28 North 8th St.  
 Search, Charles J.....Brooklyn, N. Y.....453 Franklin St.  
 Selby, John Hunter....Rochester, Minn. ....St. Mary's Hospital  
 Skinner, Clarence E....New Haven, Conn.....Elm City Private Hosp.  
 Skinner, Edward H....Kansas City, Mo.....1019 Rialto Bldg.  
 Shorb, J. E.....Canton, Ohio .....423 South Market St.  
 Snook, Mr. H. Clyde...Philadelphia, Pa. ....1210 Race St.  
 Soiland, Albert .....Los Angeles, Cal.....916 Wright & Callendar  
 Building.  
 Steele, George M.....Oshkosh, Wis. ....100 Algoma St.  
 Stevens, Rollin H.....Detroit, Mich. ....623 Stevens Bldg.  
 Stewart, Thomas S....Philadelphia, Pa. ....1736 Spruce St.  
 Stewart, W. H.....New York, N. Y.....14 West 126th St.  
 Stover, George H.....Denver, Col. ....1443 Glenarm St.  
 Talley, Daniel D., Jr...Richmond, Va. ....118 East Franklin St.  
 Thomas, George F.....Cleveland, Ohio .....533 Osburn Bldg.  
 Titterington, M. B....Jerseyville, Ill. ....21 W. Pearle St.  
 Titus, Edward C.....New York, N. Y.....127 West 11th St.  
 Todd, J. Harvey.....Toronto, Ont., Canada..165 College St.  
 Tousey, Sinclair .....New York, N. Y.....140 West 57th St.  
 Tucker, Edwin D.....Toledo, Ohio .....227 Michigan St.

Van Allen, Harvey W.	Springfield, Mass.	.....	19 Maple St.
Van Strander, Wm. H.	Hartford, Conn.	.....	61 Church St.
Wadhams, R. L.	Wilkes-Barre, Pa.	.....	72 N. Franklin St.
Waite, Harry E.	New York, N. Y.	.....	113 West 31st St.
Weaver, Louis S.	York, Pa.	.....	9 East Market St.
Westcott, William C.	Atlantic City, N. J.		
Wilkins, W. A.	Montreal, Canada	.....	538 Dorchester West
Williams, T. V.	New Castle, Pa.	.....	533 South Mill St.
Wilson, Robert	Montreal, Canada	.....	596 Wellington St.
Zapffe, Fred C.	Chicago, Ill.	.....	100 State St.

#### Honorary Members.

Potter, Charles A.	Boston, Mass.	.....	254 Beacon St.
Sweet, William M.	Philadelphia, Pa.	.....	1205 Spruce St.
Tesla, Nicola	New York City	.....	48 East Houston St.

#### Corresponding Members.

Albers-Schonberg,			
Heinrich	Hamburg, Germany		
Edwards, J. Hall	Birmingham, England		
Haenisch, G. Fedor	Hamburg, Germany	....	Klopstockstrasse 10
Harris, L. Hererschel	New South Wales, Aus.	....	215 Macquarie St.
Holz knecht, Guido	Vienna, Austria	....	
Kohler, Alban	Weisbaden, Germany	....	
Klynens	Antwerp, Belgium	....	Rue Ommerganck
Schwartz, Gottwald	Vienna, Austria	....	



## CURRENT LITERATURE

---

### TREATMENT OF UTERINE HEMORRHAGE BY ROENTGEN-RAYS.

BY GEO. E. PFAHLER, PHILADELPHIA.  
(*Am. J. Obstet. & Gyn.*, May, 1913.)

In general, the object of the treatment is to depress, or obliterate, the functions of the ovaries, thus producing an amenorrhea or oligomenorrhea; and to cause an atrophy of fibroids if present, both by the action of the rays on the ovaries, and by direct action on the tumors. This should be accomplished without damage to the skin, the bowels or the lymphatic glands, with a fair degree of certainty, and within a reasonably short time. Therefore the greatest attention must be given to technic. To learn this technic, one must learn the principles of roentgenography, as well as roentgenotherapy. For instance, the man who cannot make good kidney and bladder plates, cannot understand the technic necessary to do good therapeutics in this special field. It is not easily learned, or more men would know it. The exciting instrument should give a uniform current of high voltage. For this Pfahler prefers the high-speed static machine (forty plates), but an inductor or a transformer may be used. The tube should be one that will keep a constant high vacuum of 7 to 8 Benoist. If this is allowed to get soft, the rays will be absorbed in the superficial tissues resulting in a burn, and the deep effect on the ovaries will not be obtained. Pfahler prefers a water-cooled tube with a constant stream of cold water.

The distance of the target of the tube from the skin of the patient is 12 inches.

The field of application of the rays is over the ovaries and including the fibroid if one is present. The rays should be confined to the area treated as much as possible. If a rapid result is desired, large doses must be given, and since less than a full skin dose should be given over any area of skin

within a month, the field of application must be subdivided in such a manner that by cross firing, an increased dose will reach the ovaries without burning the skin.

The frequency of application will vary with the circumstances connected with the patient, and with the skill of the operator. If a patient comes from a distance and must leave her home, it is desirable to get results as rapidly as possible. To give large doses in a short time, requires greater skill on the part of the roentgenologist.

Generally the applications are made in series of from three to nine. These are usually given on successive days. When circumstances demand it, they can all be given on one day, or can be given two or three times a week. After a full dose has been given over any area of skin, this area should not be treated again within three weeks. The favorable time for the treatment is immediately after a menstrual period. If the bleeding is continuous, the treatment should be given just after the time that would correspond to a period. A little less than (9 x) a full dose (10 x) should be given, and at a time corresponding in the succeeding month this should be repeated. The duration of the total treatment will vary with the individual. Generally from one to six such series of treatments are needed (10 x to 60 x), therefore the treatment will extend over a period of from one to six months—more often from five to six months. If large doses are given by the cross-fire method, with great skill, the duration of each individual application will vary with the technic of the operator and his apparatus. This will vary from five to twenty minutes. The skin dose, or total quantity of rays applied to the surface should be carefully measured so as to avoid burns. This can be done by the Kniebock quantimeter, or by the Sabaround and Noire discs, or Holzknicht's modifcator of the later instrument (Holzknecht radiometer). The units 10 x (Kniebock) or 5 H. (Holzknecht) correspond to an erythema dose.

Filters should be used to cut off the rays that are mostly absorbed by the skin. For this purpose the leather filter, first recommended by Pfahler (Transactions of the American Roentgen-Ray Society, Sept. 28, 29, 30, 1905), has served well. This consists of a layer of sole leather placed just above the diaphragm of the tube stand. Recently he has added to this a layer of 1 millimeter of aluminum. The skin dose must, of course, be measured beneath the filters.

Skin effects in the hands of the skillful operators have been of no consequence. In a number of patients treated, an erythema developed and in some others the skin became pigmented, or tanned. These effects disappear, leaving the skin undamaged. In a few cases a dermatitis of the first degree has been produced. In these later cases telangiectases develop in the skin about a year later. If the treatment is ignorantly or carelessly given, a severe burn may of course be produced. The treatment should never be carried beyond the production of a slight erythema.

#### Advantages and Disadvantages of the Treatment.

The advantages are: (1) it is painless; (2) it avoids the shock of an operation; (3) it preserves to a certain extent, we believe, the internal secretion which is lost in a complete oöphorectomy; (4) it does not interrupt the usual habits; (5) confinement in a hospital is avoided; (6) in the hands of a skillful operator it is without risk; (7) the menopause is brought on gradually, when necessary; (8) the amount of treatment can be graded to the needs of the patient.

The disadvantages are: (1) the prolonged course of treatment that is usually necessary. This can probably be shortened by improvement in technic. If it can be reduced to two or three months, it will probably be equal to the time required for operation and convalescence therefrom; (2) there is danger to the overlying tissues, if the rays are not properly applied. By careful attention to the technic and exact measurement of the skin dose, this can be eliminated; (3) it has been claimed to be more expensive than operation. In a sense this is true. However, if one considers that by this treatment the expense of board and hospital care is eliminated, both in the case of charity and private patients, and in both instances they can go about their usual duties, Pfahler believes we must conclude that it is not more expensive.

---

#### ABUSE OF ROENTGEN-RAYS IN TREATMENT OF SKIN AFFECTIONS.

BY J. T. BOWEN, BOSTON.

(*Boston M. & S. Jour.*, May 8, 1913.)

The place of the Roentgen-rays in dermatologic therapeutics is at present a limited one, not so extended as that of many of

the older methods that at times have seemed in danger of eclipse. This place, although small, should, however, be reserved for it. Unfortunately, the abuses of this treatment have had the result in great measure of prejudicing against its beneficial uses. Briefly, the legitimate use of the Roentgen-ray in this class of diseases is confined chiefly to the following cases: (1) Surgically inoperable epitheliomata, especially those involving the orbit of the eye. (2) Epitheliomata, or other malignant neoplasms in cases in which the patient absolutely refuses radical surgical interference. (3) Small cutaneous epitheliomata in certain selected cases, in which a good cosmetic result is very important. (4) Sycosis, and obstinate pruritus of local or general character. (5) In a few other dermatoses, such as obstinate patches of psoriasis and eczema, in mycosis fungoides, and in a few rare affections, the Roentgen-ray may occasionally be used with great advantage.

The disadvantages of the Roentgen-rays are chiefly those resulting from its improper use. The question of susceptibility has been much discussed, and need not concern us now. My chief object is to call attention to the disfiguring results produced by many who make use of this method without proper training or experience. To use this method properly and safely one should have had a certain apprenticeship. No one, however brilliant, can seize a knife for the first time and perform expert surgery. In the same way, no practitioner can buy a Roentgen-ray outfit and properly treat, without practice, skin affections of which he has little knowledge. He thinks, perhaps, that he is sure of his diagnosis, and has read statements that the Roentgen-ray has given wonderful results in similar cases. It is from such sources as this that the many disfiguring scars and blemishes are produced, that have the double misfortune of prejudicing other physicians or patients against the legitimate use of this method. Such instances have come to my knowledge with deplorable frequency of late. It has not been my purpose in this article to discuss freely the dermatologic uses of the Roentgen-ray. This subject is far too extensive for my present space. Numerous lengthy articles, and even books dealing with this matter may be found in the literature. The Roentgen-ray has proved to be, in proper hands, a useful addition to our means of treating certain carefully selected cases of skin disease, especially the



affections that I have mentioned. It is to the abuse of the method that I wish to call attention, and to show :

1. That a great many cases of unnecessary disfigurement, more obvious than the original affection, are caused by an improper use of the Roentgen-rays.

2. That the cases suitable for this treatment can be selected only by those who have some considerable knowledge of skin affections.

3. That this method of treatment requires especial study and training and should not be regarded as an easy and safe procedure by those unskilled in its use.

---

## INOPERABLE PRIMARY CARCINOMA OF THE BREAST.

BY GEO. E. PFAHLER, PHILADELPHIA.

(*New York Medical Journal*, April 26, 1913.)

This report is based on a study of twelve cases, which is all of this type that Pfahler has treated in the past fourteen years in which he has been doing roentgenotherapy. One patient, who was treated ten years ago, never got well, but the discharge, bleeding and tumor disappeared. She was free from pain, and lived four years. Another had a typical scirrhus carcinoma of the breast; was inoperable; was made comfortable and free from any symptoms of the disease for eight years during which Pfahler observed her. She went about her usual affairs and had the general good health of a woman from seventy to eighty years of age. A third was inoperable when referred to Pfahler for treatment because of the extent of the disease, and seemed hopeless even in his estimation. The disease had practically disappeared in three months. The puckered scar was then removed. Her general health improved immediately, and during three and one-half years she has felt and looked perfectly well. The fact that the disease was recurrent and metastatic, makes the result all the more convincing. A fourth patient was living and symptomatically well, over four years after she was referred with carcinoma of both breasts with metastasis. She had suffered no inconvenience except that of coming for treatment. In a case which was absolutely inoperable the disease was arrested for about a year, and even showed signs of disappearing. However, results in this case and in the previous one were less satisfactory than in any of the

others. Another patient improved in general health; pains were relieved; and she increased in weight and strength. There were some atrophy and telangiectases of the skin on the right side. After two or three years, Pfahler believes this is likely to degenerate and become necrotic. If so, and there is no carcinoma present, excision and skin grafting should be done. This patient was inoperable because of the extent of the disease. The disappearance of this advanced disease in the right breast under the action of the rays gave encouragement when signs of carcinoma developed in the opposite breast nearly a year later. The relief of the symptoms in the second breast shows that good results may at times be obtained even in a patient with a pronounced constitutional tendency. In still another case the results seemed to be most striking. The carcinoma of the right breast, with metastasis, was thoroughly removed, and on microscopic examination proved to be an undoubted case of malignant disease. The disease recurred at once, and no one doubted the recurrence. All this recurrence disappeared under the action of the rays. The disease in the left breast increased rapidly after amputation of the right. No one doubted its malignant character. Under the action of the rays, the clinical signs of the disease disappeared, and subsequent amputation of the breast showed neither microscopic nor macroscopic carcinoma. Two patients are still under active treatment, the metastases have disappeared, and the primary tumors have been greatly reduced. After they reach a stationary stage, if they do not entirely disappear, Pfahler will ask to have them excised locally, and hopes to make a later report of complete success. Dose. Each application in the early cases corresponds to about 2X, and in the later ones to about 4X (4/10 of an erythema dose). This dose should be accurately measured, either by the Kienbock quantimeter, the Holz knecht radiometer, or the Sabouraud and Noire disks. The tube should produce penetrating rays corresponding to 6 or 7 Benoist, and should be kept uniform. If tubes are allowed to get soft, the skin will absorb nearly all of the rays and a burn will result. Pfahler likes the water cooled tube best. Any instrument can be used if properly managed. Large machines will reduce the time of the exposure, but will also heat and reduce the vacuum of the tube rapidly. Therefore large machines are capable of doing great good or great harm according to the management. Pfahler prefers a forty plate, high speed static machine. The time of each exposure will depend on the apparatus used and the amount of current flowing through the

tube. This will usually be from five to twenty-five minutes, but should never be long enough to exceed an erythema dose, on any one area of skin. The repetition of the application will depend on individual circumstances. In general, Pfahler believes the more quickly all parts of the diseased area can receive a full dose of the rays, the more satisfactory will be the result. By careful use of a large apparatus, with which the time of exposure is short, two or more applications can be made on the same day. If the apparatus is small and therefore the exposure long, it will be too fatiguing to give more than one application on one day. He commonly begins with daily treatments, so as to arrest the disease as quickly as possible. When all parts of the skin have received a full dose, the treatment should be interrupted for two or three weeks. The distance of the anode from the skin is usually twelve inches, but this may be varied according to circumstances. Protection of the skin is most important. A dermatitis should be avoided as far as possible. The parts of the body that are free from the disease should be protected by lead, but especially the face and hair. Filters such as the leather filter which Pfahler first recommended over seven years ago (*Transaction of the American Roentgen Ray Society*, September 28, 30, 1905) and which consists of a layer of sole leather interposed between the tube and the patient, will give considerable protection. To this may be added, if necessary, one mm. of aluminum. It is possible to burn a patient through any filter. The disease should be attacked from as many directions as possible, and all lymphatic areas in the directions of drainage should be thoroughly rayed. The rays should reach the mediastinum, for when axillary and supraclavicular metastases have taken place, there is great danger also of mediastinal involvement. The total duration of the treatment will vary with the individual case, but will always extend over several months to a year or more. Pfahler commonly treats a patient for a few weeks actively, and then interrupts for a few weeks.

Compact, Authoritative, Practical

Our NEW Manual of

# X-Ray Practice

# and Technique

FREE ON REQUEST

**G. Cramer Dry Plate Co.**

St. Louis

Mo.

**FORBES DRY PLATES**  
*"In Business since 1883"*

To Insure Getting the Best Results, Use

## FORBES X-RAY PLATES

THERE is no Plate on the market that has caught on more readily and created a more steady demand. Easy to work, full of detail and intensity, and very rapid. TRY THEM.

**FORBES DRY PLATE CO., 26 Armour St., ROCHESTER, N.Y.**



GENERAL AGENTS:

SCHEIDEL-WESTERN X-RAY COIL CO., Chicago, Ill.

MACALASTER-WIGGIN CO., Boston, Mass.

THE APPENGOLD CO., 193 Third Avenue, New York, N.Y.





# The American Quarterly of Roentgenology

PUBLISHED BY

The American Roentgen Ray Society

*Edited by P. M. Hickey, M. D.  
Associate Editor, F. C. Zapffe, M. D.*

	PAGE
The Roentgen Ray as an Aid in the Diagnosis of Diseases of the Sphenoid Sinus - - - - -	57
<i>George E. Pfabler, M. D., Philadelphia, Pa.</i>	
Demonstration of Automatic Switch - - - - -	67
<i>Leonard Reu, M. D., Buffalo, N. Y.</i>	
Roentgenization for Non-Malignant Laryngeal Vegetations -	69
<i>A. L. Gray, M. D., Richmond, Va.</i>	
Circulatory Opacity - - - - -	75
<i>E. H. Skinner, M. D., Kansas City, Mo.</i>	
X-Ray Studies of the Ileocecal Region and the Appendix -	77
<i>James T. Case, M. D., Battle Creek, Mich.</i>	
Current Literature - - - - -	111
Book Reviews - - - - -	122
Minutes of Thirteenth Annual Meeting - - -	124

COPYRIGHT APPLIED FOR BY PRESTON M. HICKEY. ALL RIGHTS RESERVED

# Officers of American Roentgen Ray Society

---

PRESIDENT: HENRY K. PANCOAST, M. D., Philadelphia, Pa.

## VICE-PRESIDENTS:

A. W. CRANE, M. D., Kalamazoo, Mich.

CHAS. F. BOWEN, M. D., Columbus, Ohio

SECRETARY: SIDNEY LANGE, M. D., Cincinnati, O.

TREASURER: LEONARD REU, M. D., Buffalo, N. Y.

## Executive Committee

ARTHUR HOLDING, M. D., Albany, N. Y.

A. L. GRAY, M. D., Richmond, Va.

GEO. C. JOHNSTON, M. D., Pittsburg, Pa.

## Committee on Publication

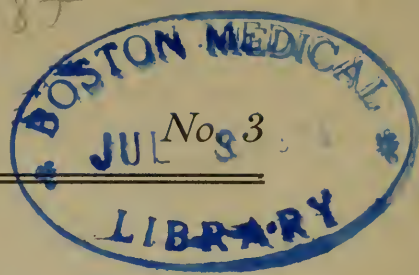
P. M. HICKEY, M. D., Detroit, Mich.

D. R. BOWEN, M. D., Philadelphia, Pa.

J. T. CASE, M. D., Battle Creek, Mich.

## Librarian

H. W. DACHTLER, Toledo, Ohio



# The American Quarterly of Roentgenology

PUBLISHED BY

The American Roentgen Ray Society

*Edited by P. M. Hickey, M. D.  
Associate Editor, F. C. Zapffe, M. D.*



	PAGE
Cases Illustrating the Roentgen Diagnostics of Internal Medicine	137
<i>A. W. Crane, M. D., Kalamazoo, Mich.</i>	
The Prognosis of Ankle and Wrist Fractures, a Method of Estimation from X-Ray Negatives	142
<i>Dr. E. H. Skinner, Kansas City</i>	
What is the Roentgen Picture of Bone Tuberculosis?	149
<i>Roland Hammond, M. D., Providence, R. I.</i>	
The Roentgen Rays in the Diagnosis of Gastric and Duodenal Ulcer	156
<i>George E. Pfahler, M. D., Philadelphia, Pa.</i>	
The X-Ray Study of 22 Cases of Ptosis of the Stomach and Colon Before and After Operation	165
<i>Max Kahn, M. D.</i>	
Editorial	171
Current Literature	173

COPYRIGHT APPLIED FOR BY PRESTON M. HICKEY. ALL RIGHTS RESERVED

# Helium Regulator X-RAY TUBES

---

---

High penetration for low electrical Resistance  
Tungsten Targets



*When you order Specify:*

The size of bulb—The size  
focus spot—The vacuum—  
The penetration—The work  
for which it is to be used:  
and we will try to send you  
what you want. One thing  
we will not do is send you a  
cranky tube



6 inch bulb	-	-	-	-	\$25.00
7 inch bulb	-	-	-	-	30.00

---

---

**ROENTGEN MANUFACTURING Co.**

1 2 1 0 R a c e S t r e e t

PHILADELPHIA, PA.




# The American Quarterly of Roentgenology

PUBLISHED BY

## The American Roentgen Ray Society

*Edited by P. M. Hickey, M. D.*

*Associate Editor, F. C. Zapffe, M. D.*



The Positive Diagnosis of Duodenal Ulcer by Means of the Roentgen Ray - - - - - 187

*Arial W. George, M. D., and Isaac Gerber, M. D.*

A Plea for a More Conservative Treatment of Malignant Growths - - - - - 199

*Russell H. Boggs, M. D., Pittsburgh, Pa.*

Conservative Surgery from a Roentgenologic Standpoint - - - - - 209

*Chevalier Jackson, M. D., Pittsburgh, Pa.*

The Need of Post Surgical Treatment in Cancer - - - - - 213

*Drs. Cole and Holding.*

The Roentgen Ray as an Aid in the Diagnosis of Fractured Skulls 217

*Dr. Wm. H. Stewart, New York City.*

Laboratory Notes - - - - - 223

*David R. Bowen, M. D.*

A Private X-Ray Laboratory - - - - - 227

*E. H. Skinner, M. D., and H. P. Wells, M. D.*

Demonstration of a Safe and Practical Method of Combining Fluoroscropy with Radiography in Abdominal Diagnosis - - - 231

*Dr. Paul Eisen, Milwaukee, Wis.*



Poems - - - - - 237

*Caroline Bartlett Crane.*

Constitution - - - - - 239

List of Members - - - - - 244

Current Literature - - - - - 249



COPYRIGHT APPLIED FOR BY P. M. HICKEY ALL RIGHTS RESERVED

---

---

Snook  
Progress Intensifying  
**SCREENS**

---

---

for Rapid Radiography

**T**HESE SCREENS have no lag, no grain, no peer, are fast, durable and washable; cost little, and are the greatest big stride in the development of intensifying screens; they make the exposures instantaneous

---

**P R I C E S**

SIZE	SCREEN	KASSETTE (Plate Holder)
5" x 7"	3.50	5.90
8" x 10"	8.00	6.00
10" x 12"	12.00	10.00
11" x 14"	15.40	11.00
14" x 17"	23.80	13.00

---


**SNOOK ROENTGEN MANUFACTURING CO.**  
1210 Race Street  
Philadelphia, Pa.

---

---









1 gal 378

COUNTWAY LIBRARY OF MEDICINE

RC

78

Al Al 83 v.4

RARE BOOKS DEPARTMENT

